# Anatomy: Thorax

Question 1 of 134

## A 5 year old girl is brought in having inhaled a small plastic object. Where in the tracheobronchial tree is the object most likely to lodge:

a Carina of the trachea

b Left main bronchus

c Right main bronchus

d Laryngotracheal junction

e Left superior lobar bronchus

Next > | See Answer

Something wrong?

Question Navigator

1 Current Question
2 ...
3 ...
4 ...
5 ...
6 ...
7 ...
8 ...
9 ...
10 ...
11 ...
12 ...



©2014 - 2017 FRCEM Success | Website designed & hosted by Cyberfrog Design

# Anatomy: Thorax

Question 1 of 134

A 5 year old girl is brought in having inhaled a small plastic object. Where in the tracheobronchial tree is the object most likely to lodge:

a) Carina of the trachea
b) Left main bronchus
c) **Right main bronchus** ✔
d) Laryngotracheal junction
e) Left superior lobar bronchus

## Answer

The right main bronchus is the shorter, wider and more vertical bronchus and therefore this is most often the location that foreign objects will lodge.

## Notes

The trachea bifurcates into a left and right main bronchus at the level of vertebra T4/T5. At the bifurcation of the main bronchi, a ridge of cartilage called the carina runs anteroposteriorly between the openings of the two bronchi.

Each main bronchus enters the root of a lung and passes through the hilum into the lung itself. The right main bronchus is wider and takes a more vertical course through the root and hilum than the left main bronchus, therefore inhaled foreign bodies are more likely to lodge on the right than the left.

The main bronchus divides into lobar bronchi (secondary bronchi) which each supply a lobe. The lobar bronchi further divided into segmental bronchi (tertiary bronchi) which supply bronchopulmonary segments (the functional unit of the lung).

Within each bronchopulmonary segment, the segmental bronchi give rise to multiple generations of divisions and ultimately to bronchioles (in order, conducting bronchioles, terminal bronchioles, respiratory bronchioles). The respiratory bronchioles continue as alveolar ducts and sacs, the walls of which form alveoli.

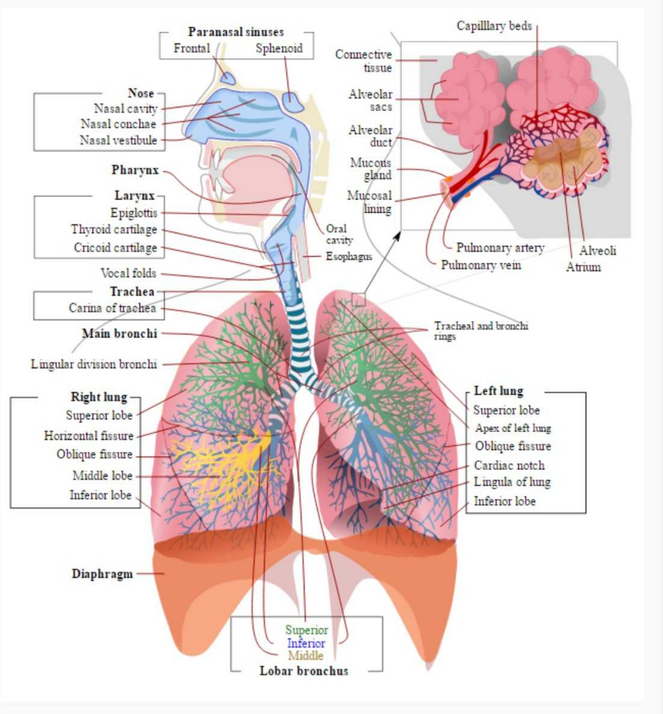


By LadyofHats [Public domain], via Wikimedia Commons

Next >

Something wrong?

## Question Navigator

1 Current Question
2 ...
3 ...
4 ...
5 ...
6 ...
7 ...
8 ...
9 ...
10 ...
11 ...
12 ...



©2014 - 2017 FRCEM Success | Website designed & hosted by Cyberfrog Design

# Anatomy: Thorax

Question 2 of 134

## Which of the following best describes the surface marking of the tricuspid valve:

a Posterior to the right half of the sternum at the level of the fourth intercostal space

b Posterior to the left half of the sternum at the level of the fourth costal cartilage

c Posterior to the third left chondrosternal joint

d Posterior to the left half of the sternum at the level of the third intercostal space

e Posterior to the right half of the sternum at the level of the third costal cartilage

< Previous | Next > | See Answer

Something wrong?

Question Navigator

1 Answered
2 Current Question
3 ...
4 ...
5 ...
6 ...
7 ...
8 ...
9 ...
10 ...



©2014 - 2017 FRCEM Success | Website designed & hosted by Cyberfrog Design

# Anatomy: Thorax

Question 2 of 134

Which of the following best describes the surface marking of the tricuspid valve:

a) Posterior to the right half of the sternum at the level of the fourth intercostal space ✔
b) **Posterior to the left half of the sternum at the level of the fourth costal cartilage** ✖
c) Posterior to the third left chondrosternal joint
d) Posterior to the left half of the sternum at the level of the third intercostal space
e) Posterior to the right half of the sternum at the level of the third costal cartilage

## Answer

The tricuspid valve is located posterior to the right half of the sternum at the level of the fourth intercostal space.

| Heart valve | Surface marking | Auscultation position |
|---|---|---|
| Tricuspid valve | Posterior to right half of sternum at level of 4th ICS | Left of sternum near 5th ICS |
| Mitral valve | Posterior to left half of sternum at level of 4th costal cartilage | Left 5th ICS in midclavicular line |
| Pulmonary valve | Posterior to third left chondrosternal joint | Medial end of left 2nd ICS |
| Aortic valve | Posterior to left half of sternum at level of 3rd ICS | Medial end of right 2nd ICS |

**Surface marking of heart valves**

- The tricuspid valve is located posterior to the right half of the sternum at the level of the fourth intercostal space.
- The mitral valve is located posterior to the left half of the sternum at the level of the fourth costal cartilage.
- The pulmonary valve is located posterior to the third left chondrosternal joint.
- The aortic valve is located posterior to the left half of the sternum at the level of the third intercostal space.

**Auscultation positions of heart valves**

Heart valves should be auscultated by positioning the stethoscope downstream from the flow of blood through the valves.

- The mitral valve is heard over the apex of the heart in the left fifth intercostal space at the midclavicular line.
- The pulmonary valve is heard over the medial end of the left second intercostal space.
- The aortic valve is heard over the medial end of the right second intercostal space.

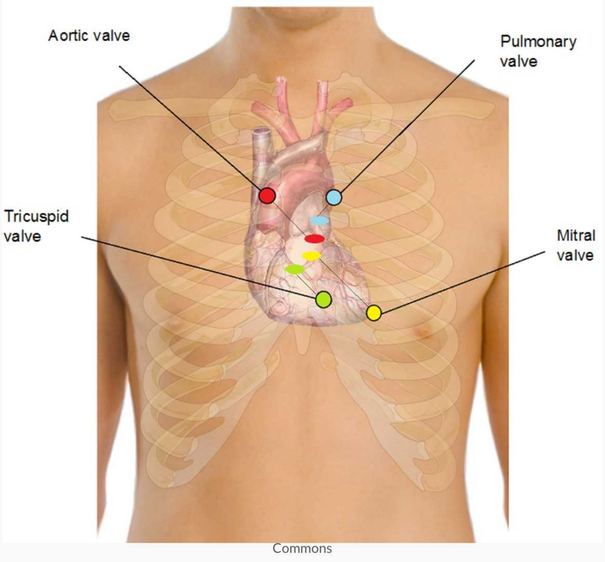


Commons

< Previous | Next > | Something wrong?

## Question Navigator

1 Answered
2 Current Question
3 ...
4 ...
5 ...
6 ...
7 ...
8 ...
9 ...
10 ...



©2014 - 2017 FRCEM Success | Website designed & hosted by Cyberfrog Design

# Anatomy: Thorax

Question 3 of 134

## A 29 year old male presents to ED having sustained a penetrating injury to the neck. On further exploration, it is found that he has transected the left phrenic nerve. Which of the following clinical features would you most expect to see:

a Inability to shrug the shoulders

b Inability to abduct the arm above 90 degrees

c Hemiparalysis of the diaphragm

d Loss of sensation of over the axilla

e Hoarse voice

< Previous | Next > | See Answer

Something wrong?

## Question Navigator

1 Answered
2 Answered
3 Current Question
4 ...
5 ...
6 ...
7 ...
8 ...
9 ...
10 ...
11 ...
12 ...



©2014 - 2017 FRCEM Success | Website designed & hosted by Cyberfrog Design

# Anatomy: Thorax

Question 3 of 134

A 29 year old male presents to ED having sustained a penetrating injury to the neck. On further exploration, it is found that he has transected the left phrenic nerve. Which of the following clinical features would you most expect to see:

**a)** Inability to shrug the shoulders
**b)** Inability to abduct the arm above 90 degrees
**c)** **Hemiparalysis of the diaphragm** ✔
**d)** Loss of sensation of over the axilla
**e)** Hoarse voice

## Answer

The phrenic nerve innervates the diaphragm. Injury to the left phrenic nerve will result in hemiparalysis of the left diaphragm. Paralysis of the diaphragm produces a paradoxical movement. The affected side of the diaphragm moves upwards during inspiration (as it is pushed superiorly by the abdominal viscera that are being actively compressed by the other half), and downwards during expiration.

## Notes

The diaphragm is a musculotendinous structure that separates the thoracic cavity from the abdominal cavity.

| Structure | Diaphragm |
|---|---|
| Primary function | Respiration – contraction of diaphragm flattens diaphragm increasing vertical dimension of thorax (inspiration), relaxation of diaphragm elevates diaphragm decreasing vertical dimension of thorax (expiration) |
| Secondary functions | Assists in straining movements by increasing intra-abdominal pressure, acts as functional sphincter on oesophagus preventing acid reflux |
| Peripheral attachments | Xiphoid process of sternum, costal cartilages ribs 7 – 10, ends of ribs 11 and 12, arcuate ligaments and lumbar vertebrae |
| Central attachment | Fuses with fibrous pericardium superiorly |
| Surface markings | Attachments: vertebrae T8/T9 anteriorly, vertebra T12 posteriorly, Domes: right dome 5th rib, left dome 5th intercostal space |
| Openings | Oesophageal opening at T10 (oesophagus, vagus nerve), aortic opening at T12 (aorta, thoracic duct and azygos vein), caval opening at T8 (inferior vena cava and right phrenic nerve) |
| Innervation | Phrenic nerve (C3 – C5) |

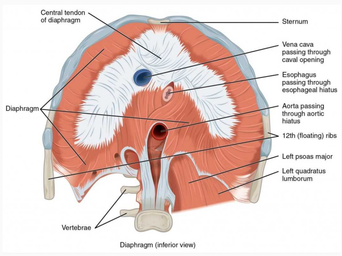


By OpenStax [CC BY 4.0 (http://creativecommons.org/licenses/by/4.0)], via Wikimedia Commons

### Function

The diaphragm performs an important function in respiration; contraction of the domes of the diaphragm in inspiration flattens the diaphragm, increasing the vertical dimension of the thorax and vice versa in expiration, with relaxation and elevation of the diaphragm reducing the vertical dimension of the thorax.

The diaphragm is also involved in non-respiratory functions; helping to expel vomit, faeces, and urine from the body by increasing intraabdominal pressure, and preventing acid reflux by exerting pressure on the oesophagus as it passes through the oesophageal opening.

### Attachments

The diaphragm is attached peripherally to:

- the xiphoid process of the sternum and the costal cartilages of ribs 7 – 10 (the costal margin) anteriorly
- the ends of ribs 11 and 12 laterally
- the arcuate ligaments and vertebrae posteriorly.

From these peripheral attachments, muscle fibres converge to form the central tendon which fuses with the fibrous pericardium superiorly.

### Surface markings

In the medial sagittal plane, the diaphragm slopes inferiorly from its anterior attachment to the xiphoid at approximately vertebral level T8/T9 to its posterior attachment to the median arcuate ligament at approximately vertebral level T12.

At rest the right dome of the diaphragm lies slightly higher than the left; this is thought to be due to the position of the liver. In normal expiration, the normal upper limits of the superior margins are the fifth rib for the right dome, the fifth intercostal space for the left dome and the xiphoid process for the central tendon.

### Diaphragmatic openings

Structures travelling between the thorax and abdomen must pass through the diaphragm via three main openings.

The oesophageal opening at vertebral level T10 transmits:

- the oesophagus
- the anterior and posterior vagal trunks
- oesophageal branches of the left gastric vessels
- a few lymphatics.

The aortic opening at vertebral level T12 transmits:

- the aorta
- the thoracic duct
- the azygos vein and sometimes the hemiazygos vein.

The caval opening at vertebral level T8 transmits:

- the inferior vena cava
- the right phrenic nerve.

### Innervation

The entire motor supply of the diaphragm is from the right and left phrenic nerves (C3 – C5) which penetrate the diaphragm and innervate it from its abdominal surface.

Damage to the phrenic nerve will result in hemiparalysis of the diaphragm. Paralysis of the diaphragm produces a paradoxical movement. The affected side of the diaphragm moves upwards during inspiration (as it is pushed superiorly by the abdominal viscera that are being actively compressed by the other half), and downwards during expiration.

A unilateral diaphragmatic paralysis is usually asymptomatic, and is most often an incidental finding on x-ray. If both sides are paralysed, the patient may experience poor exercise tolerance, orthopnoea and fatigue. Lung function tests will show a restrictive deficit.

### Diaphragmatic herniation

Diaphragmatic hernias are defined as congenital or acquired defects in the diaphragm. There are two main types of congenital diaphragmatic hernias; Bochdalek hernias and Morgagni hernias.

Acquired diaphragmatic hernias include traumatic diaphragmatic rupture, hiatus hernia and iatrogenic diaphragmatic hernias. Depending on the location and size of the defect, retroperitoneal or intra-abdominal organs and tissues can prolapse into the thoracic cavity due to the negative intrathoracic pressure.

Diaphragmatic rupture usually results from blunt abdominal trauma, which is typically associated with motor-vehicle accidents; the most commonly herniated viscera are the stomach and colon on the left side, and the liver on the right side.

In hiatus hernia, the stomach herniates through the oesophageal opening of the diaphragm, typically resulting in symptoms of acid reflux.

< Previous | Next >

Something wrong?

## Question Navigator

1 Answered
2 Answered
3 Current Question
4 ...
5 ...
6 ...
7 ...
8 ...
9 ...
10 ...
11 ...
12 ...



©2014 - 2017 FRCEM Success | Website designed & hosted by Cyberfrog Design

# Anatomy: Thorax

Question 4 of 134

## A 54 year old man presents to ED with central crushing chest pain. Later coronary angiograms show thrombosis in the circumflex branch of the left coronary artery. Which of the following conditions is most likely to result from obstruction to flow:

a Ischaemia of the AV node

b Ischaemia of the SA node

c Tricuspid valve insufficiency

d Mitral valve insufficiency

e Interventricular septum necrosis

< Previous | Next > | See Answer

Something wrong?

Question Navigator

1 Answered
2 Answered
3 Answered
4 Current Question
5 ...
6 ...
7 ...
8 ...
9 ...
10 ...
11 ...
12 ...



©2014 - 2017 FRCEM Success | Website designed & hosted by Cyberfrog Design

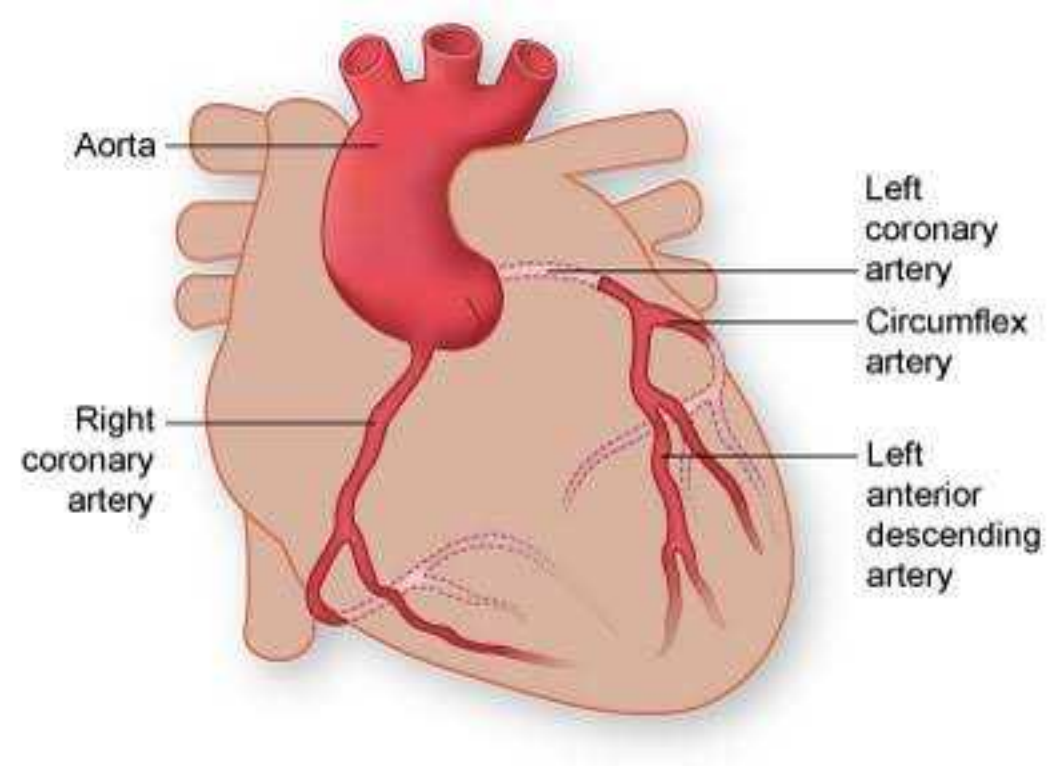
Aorta
Left coronary artery
Circumflex artery
Right coronary artery
Left anterior descending artery

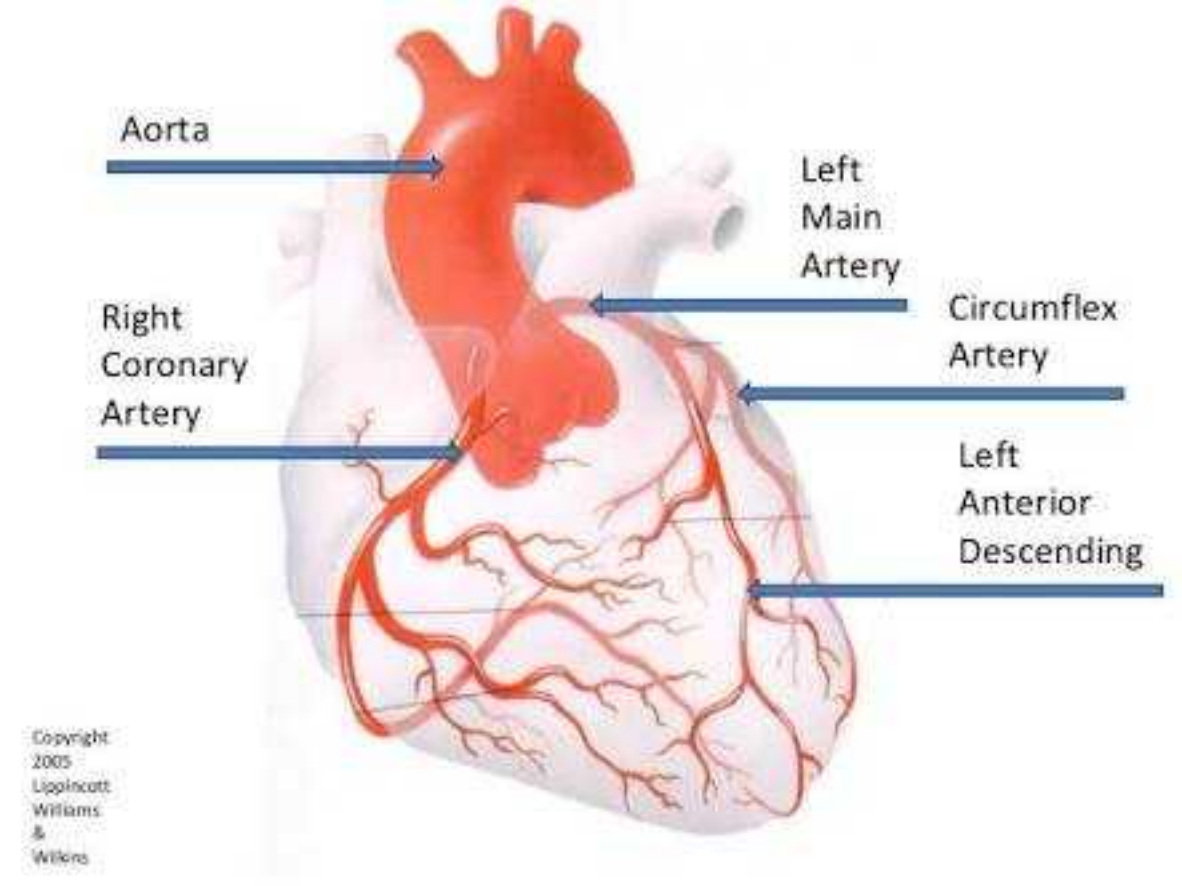
Aorta
Left
Main
Artery
Right
Coronary
Artery
Circumflex
Artery
Left
Anterior
Descending
Copyright
2005
Lippincott
Williams
&
Wilkins

Chris Tabak, MD
tchb@case.edu

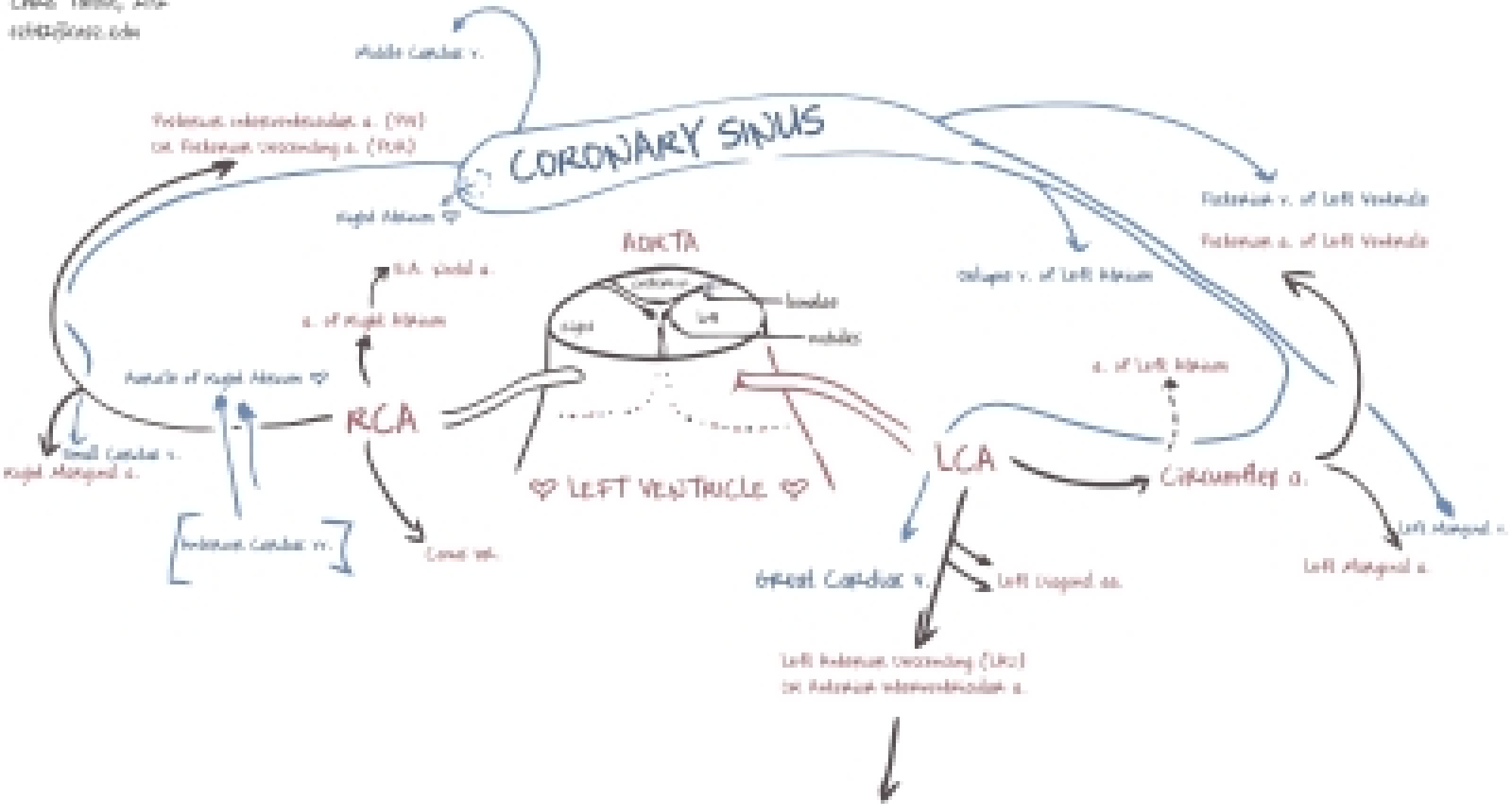

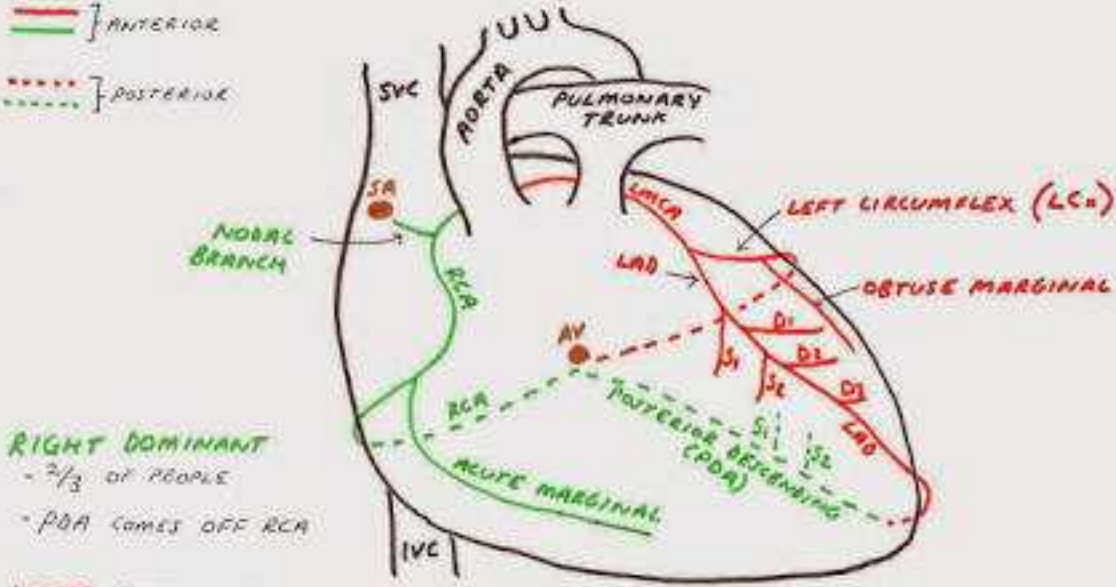


**RIGHT DOMINANT**
- 2/3 OF PEOPLE
- PDA COMES OFF RCA

**LEFT DOMINANT**
- PDA COMES OF LCx

**CO-DOMINANT**
- PDA COMES OFF BOTH RCA + LCx

$D_1, D_2, D_3$ = DIAGONAL BRANCHES OF LAD

$S_1, S_2$ = SEPTAL BRANCHES OF LAD

$S_1, S_2$ = SEPTAL BRANCHES OF POSTERIOR DESCENDING ARTERY

# Anatomy: Thorax

Question 4 of 134

A 54 year old man presents to ED with central crushing chest pain. Later coronary angiograms show thrombosis in the circumflex branch of the left coronary artery. Which of the following conditions is most likely to result from obstruction to flow:

**a)** Ischaemia of the AV node
**b)** Ischaemia of the SA node
**c)** Tricuspid valve insufficiency
**d)** **Mitral valve insufficiency** ✔
**e)** Interventricular septum necrosis

## Answer

The circumflex branch of the left coronary artery supplies the left ventricle and thus its blockage results in necrosis of the myocardium in the left ventricle, producing mitral valve insufficiency. The tricuspid valve is in the right ventricle. The SA and AV node are usually supplied by the right coronary artery. The interventricular septum is supplied anteriorly by the anterior interventricular artery and posteriorly by the posterior interventricular artery.

## Notes

The right and left coronary arteries arise from the right and left aortic sinuses in the initial portion of the ascending aorta and supply the muscle and other tissues of the heart.

| Artery | Territory of supply |
|---|---|
| Right coronary artery | Right atrium and ventricle, sinoatrial node, atrioventricular node |
| Right marginal branch | Inferior aspect of right ventricle |
| Posterior interventricular branch | Posterior aspect of right and left ventricles, posterior one-third of interventricular septum |
| Left coronary artery | Via main branches below |
| Anterior interventricular branch | Right and left ventricles, anterior two-thirds of interventricular septum |
| Left circumflex branch | Left atrium and left ventricle |

**Territories of supply**

Although there is variation, in most people the territories of supply are as follows:

The right coronary artery supplies:

- the right atrium
- most of the right ventricle
- the sinoatrial and atrioventricular nodes
- the interatrial septum
- a portion of the left atrium
- the posteroinferior one-third of the interventricular septum
- a portion of the posterior part of the left ventricle

The left coronary artery supplies:

- most of the left atrium
- most of the left ventricle
- a portion of the right ventricle
- most of the interventricular septum (including the atrioventricular bundle and branches)

**Branches**

The right coronary artery supplies the right atrium, the sinoatrial node and the atrioventricular node (via the SA and AV nodal branches) and gives rise to two principal branches:

- the right marginal branch (supplying the inferior margin of the right ventricle and the apex)
- the posterior interventricular branch (supplying the posterior aspect of the right and left ventricles and the posterior one-third of the interventricular septum).

The left coronary artery gives rise to two principal branches:

- the anterior interventricular branch (supplying the right and left ventricles, the apex and the anterior two-thirds of the interventricular septum)
- the circumflex branch (supplying the left atrium and left ventricle).

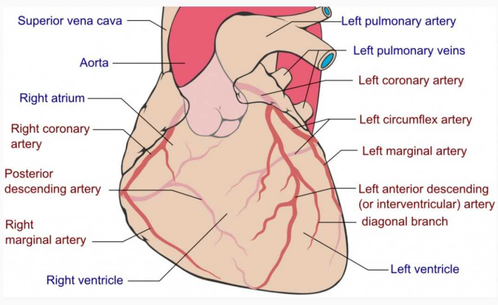


By Coronary.pdf: Patrick J. Lynch, medical illustrator derivative work: Fred the Oyster (talk) adaption and further labeling: Mikael Häggström (Coronary.pdf) [CC BY-SA 3.0 (http://creativecommons.org/licenses/by-sa/3.0)], via Wikimedia Commons

< Previous | Next > | Something wrong?

## Question Navigator

1 Answered
2 Answered
3 Answered
4 Current Question
5 ...
6 ...
7 ...
8 ...
9 ...
10 ...
11 ...
12 ...



©2014 - 2017 FRCEM Success | Website designed & hosted by Cyberfrog Design

# Anatomy: Thorax

Question 5 of 134

## Which of the following structures lies immediately posterior to the base of the heart:

a Vagus nerve

b Oesophagus

c Thoracic duct

d Trachea

e Aortic arch

< Previous | Next > | See Answer

Something wrong?

Question Navigator

1 Answered
2 Answered
3 Answered
4 Answered
5 Current Question
6 ...
7 ...
8 ...
9 ...
10 ...
11 ...
12 ...



©2014 - 2017 FRCEM Success | Website designed & hosted by Cyberfrog Design

# Anatomy: Thorax

Question 5 of 134

Which of the following structures lies immediately posterior to the base of the heart:

a) Vagus nerve
b) Oesophagus ✔
c) Thoracic duct
d) **Trachea** ✖
e) Aortic arch

## Answer

The oesophagus lies immediately posterior to the base of the heart.

## Notes

| Border/Surface | Main structure (contributing structures) |
|---|---|
| Apex | Left ventricle |
| Base | Left atrium (right atrium, proximal great veins) |
| Anterior surface | Right ventricle (right atrium, left ventricle) |
| Inferior surface | Left and right ventricle |
| Left pulmonary surface | Left ventricle (left atrium) |
| Right pulmonary surface | Right atrium |
| Inferior border | Right ventricle (left ventricle) |
| Left border | Left ventricle (left auricle) |
| Right border | Right atrium |
| Superior border | Both atria, roots of great vessels |

The general shape and orientation of the heart are that of a pyramid that has fallen over and is resting on one of its sides.

- The apex of this pyramid projects forwards, downwards and to the left. The apex is formed by the inferolateral part of the left ventricle and is positioned deep to the left fifth intercostal space in the midclavicular line.
- The base is facing posteriorly. The base is formed mostly by the left atrium with a small portion of the right atrium and the proximal part of the great veins, and is fixed posteriorly to the pericardial wall, opposite the bodies of the T5 – T8 vertebrae (T6 – T9 when standing). The oesophagus lies immediately posterior to the base.

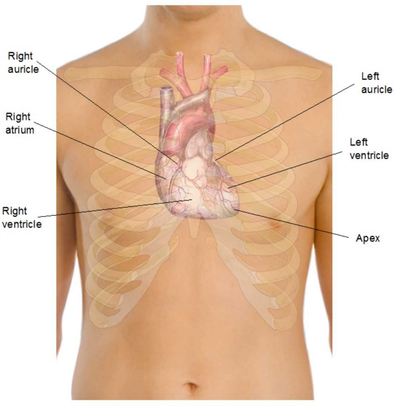


Modified by FRCEM Success. Original by Mikael Häggström (See above. All used images are in public domain.) [Public domain], via Wikimedia Commons

**Surfaces**

There are four surfaces to the upturned pyramid:

- The anterior (sternocostal) surface consists mostly of the right ventricle with some of the right atrium and some of the left ventricle.
- The inferior (diaphragmatic) surface consists of the left ventricle with a small portion of the right ventricle separated by the posterior interventricular groove.
- The left pulmonary surface consists mainly of the left ventricle and a portion of the left atrium.
- The right pulmonary surface consists of the right atrium.

**Borders**

There are four main borders separating the surfaces of the heart:

- The inferior border is formed mostly by the right ventricle and a small portion of the left ventricle near the apex.
- The left border is formed mostly by the left ventricle with a small portion of the left auricle.
- The right border is formed by the right atrium.
- The superior border is formed by both atria and the roots of the great vessels.

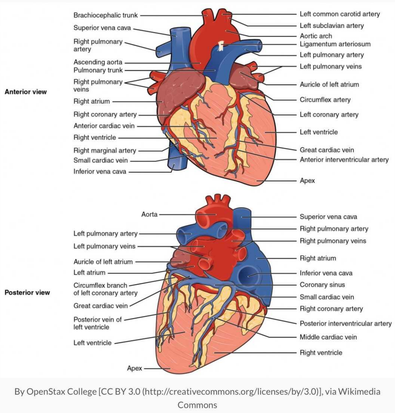


By OpenStax College [CC BY 3.0 (http://creativecommons.org/licenses/by/3.0)], via Wikimedia Commons

< Previous | Next >

Something wrong?

## Question Navigator

1 Answered
2 Answered
3 Answered
4 Answered
5 Current Question
6 ...
7 ...
8 ...
9 ...
10 ...
11 ...
12 ...



©2014 - 2017 FRCEM Success | Website designed & hosted by Cyberfrog Design

# Anatomy: Thorax

Question 6 of 134

## The inferior margin of the lung in quiet respiration is a line that runs anterolaterally between which of the following surface landmarks:

a Rib 5 in the midclavicular line and rib 6 in the midaxillary line

b Rib 6 in the midclavicular line and rib 6 in the midaxillary line

c Rib 6 in the midclavicular line and rib 8 in the midaxillary line

d Rib 6 in the midclavicular line and rib 9 in the midaxillary line

e Rib 7 in the midclavicular line and rib 8 in the midaxillary line

< Previous | Next > | See Answer

Something wrong?

## Question Navigator

1 Answered
2 Answered
3 Answered
4 Answered
5 Answered
6 Current Question
7 ...
8 ...
9 ...
10 ...
11 ...
12 ...



©2014 - 2017 FRCEM Success | Website designed & hosted by Cyberfrog Design

# Anatomy: Thorax

Question 6 of 134

The inferior margin of the lung in quiet respiration is a line that runs anterolaterally between which of the following surface landmarks:

a) Rib 5 in the midclavicular line and rib 6 in the midaxillary line
b) Rib 6 in the midclavicular line and rib 6 in the midaxillary line
c) **Rib 6 in the midclavicular line and rib 8 in the midaxillary line** ✔
d) Rib 6 in the midclavicular line and rib 9 in the midaxillary line
e) Rib 7 in the midclavicular line and rib 8 in the midaxillary line

## Answer

The inferior margin of the pleural cavity is a line that runs between rib 8 in the midclavicular line, rib 10 in the midaxillary line and vertebra T12 posteriorly. The inferior margin of the lung in quiet respiration is a line that runs between rib 6 in the midclavicular line, rib 8 in the midaxillary line and vertebra T10 posteriorly.

## Notes

Each lung is surrounded by a pleura. The pleura consists of two parts, the parietal pleura (which lines the thoracic cavity) and the visceral pleura (which lines the lungs). The two parts of the pleura are continuous with each other at the hilum of each lung. The potential space between these two parts of the pleura is called the pleural cavity.

**Pleural cavity**

The pleural cavity normally contains a small amount of lubricating fluid to allow the visceral pleura attached to the lungs to smoothly slide over the parietal pleura attached to the thoracic wall during respiration. The serous fluid also produces a surface tension, pulling the parietal and visceral pleura together. This ensures that when the thorax expands, the lung also expands, filling with air.

**Innervation**

The parietal pleura is innervated by somatic afferent fibres. The costal pleura (pleura related to the ribs and intercostal spaces) is innervated by branches of the intercostal nerves, and pain is felt in relation to the thoracic wall. The diaphragmatic pleura (covering the diaphragm) and the mediastinal pleura (covering the mediastinum) are innervated mainly by the phrenic nerves (C3 – C5), and pain is referred the the C3 – C5 dermatomes (lateral neck and supraclavicular region of shoulder).

Although the visceral pleura is innervated by visceral afferent fibres, pain is not generally elicited from this tissue.

**Surface markings**

Superiorly the pleural cavity projects as much as 3 – 4 cm above the first costal cartilage but does not extend above the neck of rib 1.

Anteriorly the pleurae approach each other posterior to the upper part of the sternum. At the lower part of the sternum the left pleura does not come as close to the midline as the right pleura because the middle mediastinum bulges to the left.

Inferiorly the pleura reflects onto the diaphragm above the costal margin. The inferior margin of the pleural cavity is a line that runs between rib 8 in the midclavicular line, rib 10 in the midaxillary line and vertebra T12 posteriorly.

The inferior margin of the lung in quiet respiration is a line that runs between rib 6 in the midclavicular line, rib 8 in the midaxillary line and vertebra T10 posteriorly.

The lungs therefore do not completely fill the pleural cavities, producing two pleural recesses, the costomediastinal and costodiaphragmatic recesses, in which fluids can collect.

The costomediastinal recess occurs on each side where the the costal pleura is opposed to mediastinal pleura, particularly on the left side in the region overlying the heart.

The costodiaphragmatic recess occurs between the costal and diaphragmatic pleura. It is the region between the inferior margin of the lung and the inferior margin of the pleural cavity and is clinically important for pleural aspiration.

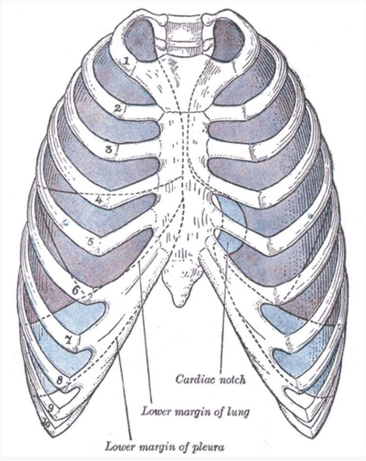


By Henry Vandyke Carter [Public domain], via Wikimedia Commons

< Previous | Next > | Something wrong?

## Question Navigator

1 Answered
2 Answered
3 Answered
4 Answered
5 Answered
6 Current Question
7 ...
8 ...
9 ...
10 ...
11 ...
12 ...



©2014 - 2017 FRCEM Success | Website designed & hosted by Cyberfrog Design

# Anatomy: Thorax

Question 7 of 134

A 54 year old man complains of tingling and a blistering rash that has erupted over his left back and left chest at the level of the nipple. You diagnose shingles. Which of the following spinal nerve roots is most likely affected:

a T2

b T3

c T4

d T5

e T6

< Previous | Next > | See Answer

Something wrong?

## Question Navigator

1 Answered
2 Answered
3 Answered
4 Answered
5 Answered
6 Answered
7 Current Question
8 ...
9 ...
10 ...
11 ...
12 ...



©2014 - 2017 FRCEM Success | Website designed & hosted by Cyberfrog Design

# Anatomy: Thorax

Question 7 of 134

A 54 year old man complains of tingling and a blistering rash that has erupted over his left back and left chest at the level of the nipple. You diagnose shingles. Which of the following spinal nerve roots is most likely affected:

**a)** T2
**b)** T3
**c)** T4 ✔
**d)** T5
**e)** T6

## Answer

The dermatome that includes the nipple is supplied by spinal nerve T4. The herpes zoster virus is harbored in the dorsal root ganglion of T4 and can be activated to cause the characteristic rash that is distributed along the T4 dermatome.

## Notes

| Dermatome | Landmark |
|---|---|
| T1 | Medial antecubital fossa |
| T2 | Apex of axilla |
| T3 | Third intercostal space |
| T4 | Level of nipples (fourth intercostal space) |
| T5 | Fifth intercostal space |
| T6 | Level of xiphisternum |
| T7 | One-quarter distance between xiphisternum and umbilicus |
| T8 | One-half distance between xiphisternum and umbilicus |
| T9 | Three-quarter distance between xiphisternum and umbilicus |
| T10 | Level of umbilicus |
| T11 | Midway between umbilicus and inguinal ligament |
| T12 | Midpoint of inguinal ligament |

**Dermatome assessment**

- The T1 dermatome is best tested on the medial (ulnar) side of the antecubital fossa, just proximal to the medial epicondyle of the humerus.
- The T2 dermatome is best tested at the apex of the axilla.
- The T3 dermatome is best tested at the midclavicular line and the third intercostal space.
- The T4 dermatome is best tested at the midclavicular line and the fourth intercostal space, located at the level of the nipples.
- The T5 dermatome is best tested at the midclavicular line and the fifth intercostal space, located midway between the level of the nipples and the level of the xiphisternum.
- The T6 dermatome is best tested at the midclavicular line, located at the level of the xiphisternum.
- The T7 dermatome is best tested at the midclavicular line, one quarter the distance between the level of the xiphisternum and the level of the umbilicus.
- The T8 dermatome is best tested at the midclavicular line, one half the distance between the level of the xiphisternum and the level of the umbilicus.
- The T9 dermatome is best tested at the midclavicular line, three quarters of the distance between the level of the xiphisternum and the level of the umbilicus.
- The T10 dermatome is best tested at the midclavicular line, located at the level of the umbilicus.
- The T11 dermatome is best tested at the midclavicular line, midway between the level of the umbilicus and the inguinal ligament.
- The T12 dermatome is best tested at the midclavicular line, over the midpoint of the inguinal ligament.

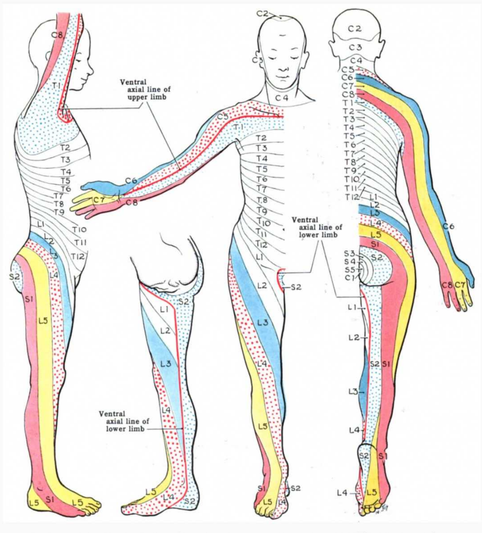


By Grant, John Charles Boileau (An atlas of anatomy, / by regions 1962) [Public domain], via Wikimedia Commons

< Previous | Next >

Something wrong?

## Question Navigator

1 Answered
2 Answered
3 Answered
4 Answered
5 Answered
6 Answered
7 Current Question
8 ...
9 ...
10 ...
11 ...
12 ...



©2014 - 2017 FRCEM Success | Website designed & hosted by Cyberfrog Design

# Anatomy: Thorax

Question 8 of 134

## The 'pump handle' movement of the thoracic wall results from which of the following movements:

a The anterior ends of the ribs moving upwards and forwards

b The shafts of the ribs moving upwards and laterally

c The posterior ends of the ribs moving upwards and backwards

d The internal intercostal muscles elevating the ribs

e Contraction of the diaphragm

< Previous | Next > | See Answer

Something wrong?

Question Navigator

1 Answered
2 Answered
3 Answered
4 Answered
5 Answered
6 Answered
7 Answered
8 Current Question
9 ...
10 ...
11 ...
12 ...



©2014 - 2017 FRCEM Success | Website designed & hosted by Cyberfrog Design

# Anatomy: Thorax

Question 8 of 134

The 'pump handle' movement of the thoracic wall results from which of the following movements:

**a)** **The anterior ends of the ribs moving upwards and forwards** ✔
**b)** The shafts of the ribs moving upwards and laterally
**c)** The posterior ends of the ribs moving upwards and backwards
**d)** The internal intercostal muscles elevating the ribs
**e)** Contraction of the diaphragm

## Answer

Because the anterior ends of the ribs are inferior to the posterior ends, when the ribs are elevated, the anterior end moves upwards and forwards, moving the sternum upwards and forwards in turn. This 'pump handle' upwards and forwards movement changes the anteroposterior (AP) dimension of the thorax.

## Notes

**Thoracic wall movements**

Movement of the ribs at the costovertebral joints in respiration results in the 'pump handle' and 'bucket handle' movements:

- Because the anterior ends of the ribs are inferior to the posterior ends, when the ribs are elevated, the anterior end moves upwards and forwards, moving the sternum upwards and forwards in turn. This 'pump handle' upwards and forwards movement changes the anteroposterior (AP) dimension of the thorax.
- Because the shafts of the ribs are lower than either the anterior or posterior end, elevation of the ribs also moves the shafts laterally. This 'bucket handle' upwards and lateral movement increases the lateral dimensions of the thorax.

Reversal of these movements i.e. depression of the ribs, will reduce the anteroposterior and transverse dimensions of the thorax.

**Inspiration**

In inspiration, elevation of the sternal ends of the ribs ('pump handle' movement), elevation of the lateral shafts of the ribs ('bucket handle' movement) and depression of the diaphragm result in expansion of the thorax in an anteroposterior, transverse and vertical direction respectively. This results in an increased intrathoracic volume and decreased intrathoracic pressure and thus air is drawn into the lungs.

Passive inspiration is produced by contraction of the diaphragm (depressing the diaphragm) and the external intercostal muscles (elevating the ribs).

The accessory respiratory muscles (including the sternocleidomastoid, the scalene muscles and the serratus anterior amongst others) aid in forceful inspiration.

**Expiration**

In expiration, depression of the ribs and elevation of the diaphragm result in a reduction of the thorax in an anteroposterior, transverse and vertical direction. This results in a decreased intrathoracic volume and increased intrathoracic pressure and thus air is forced out of the lungs.

Passive expiration is produced primarily by relaxation of the inspiratory muscles (diaphragm and external intercostal muscles) and the elastic recoil of the lungs.

Forceful expiration is primarily produced by the deeper thoracic muscles (internal and innermost intercostal muscles, subcostals and transversus thoracis) aided by contraction of the abdominal wall muscles which increase intra-abdominal pressure thus further reducing the volume of the thorax.

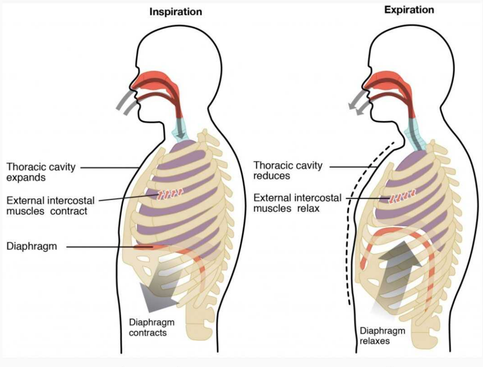


By OpenStax College [CC BY 3.0 (http://creativecommons.org/licenses/by/3.0)], via Wikimedia Commons

**Paradoxical respiration**

Normally as the diaphragm moves downwards in respiration, the abdominal wall moves outwards (together with the chest wall), and the reverse occurs in expiration.

In complete airway obstruction, the diaphragm will move down and the abdominal wall out but as inspiratory effort continues against a closed airway, increasing intrathoracic pressure will draw the chest wall paradoxically inwards (against the opposing action of the intercostal muscles). To the observer, in inspiration there is abdominal expansion with chest collapse and during expiration the reverse is seen. As inspiratory effort increases and expiration becomes active, the see-sawing pattern becomes more pronounced.

Flail chest is a loss of stability of the thoracic cage that occurs when a segment of the anterior or lateral thoracic wall moves freely because of multiple rib fractures, allowing the loose segment to move paradoxically inward on inspiration and outward on expiration. If a large enough segment of the chest is affected, ventilation is impaired.

< Previous | Next >

Something wrong?

## Question Navigator

1 Answered
2 Answered
3 Answered
4 Answered
5 Answered
6 Answered
7 Answered
8 Current Question
9 ...
10 ...
11 ...
12 ...



©2014 - 2017 FRCEM Success | Website designed & hosted by Cyberfrog Design

# Anatomy: Thorax

Question 9 of 134

A 21 year old man is brought to ED having been involved in a road traffic accident. He is hypotensive with muffled heart sounds and distended neck veins. Your consultant suspects cardiac tamponade and proceeds to perform emergency pericardiocentesis. Which of the following sites is the needle best placed to relieve the tamponade:

a Right fifth intercostal space midclavicular line

b Inferior and to the left of the xiphochondral junction

c Medial left sixth intercostal space

d Medial left seventh intercostal space

e Inferior and to the right of the xiphochondral junction

< Previous | Next > | See Answer

Something wrong?

## Question Navigator

1 Answered
2 Answered
3 Answered
4 Answered
5 Answered
6 Answered
7 Answered
8 Answered
9 Current Question
10 ...
11 ...
12 ...



©2014 - 2017 FRCEM Success | Website designed & hosted by Cyberfrog Design

# Anatomy: Thorax

Question 9 of 134

A 21 year old man is brought to ED having been involved in a road traffic accident. He is hypotensive with muffled heart sounds and distended neck veins. Your consultant suspects cardiac tamponade and proceeds to perform emergency pericardiocentesis. Which of the following sites is the needle best placed to relieve the tamponade:

a) Right fifth intercostal space midclavicular line
b) **Inferior and to the left of the xiphochondral junction** ✔
c) Medial left sixth intercostal space
d) Medial left seventh intercostal space
e) Inferior and to the right of the xiphochondral junction

## Answer

In ATLS guidance a needle should be inserted into the pericardial cavity 1 – 2 cm inferior and to the left of the xiphochondral junction (between the xiphisternum and the left costal margin) at a 45 degree angle and advanced aiming toward the tip of the left scapula. The left fifth intercostal space in the midclavicular line is an alternative site used.

## Notes

The pericardium is a fibroserous sac surrounding the heart and the roots of the great vessels in the middle mediastinum. It is composed of two main layers; the fibrous pericardium and the serous pericardium.

**Serous pericardium**

The serous pericardium itself is divided into two parts which are continuous at the roots of the great vessels; the parietal layer which lines the inner surface of the fibrous pericardium and the visceral layer which lines the heart itself.

The parietal and visceral layer of serous pericardium are separated by the pericardial cavity which normally contains a small amount of lubricating serous fluid which reduces friction during normal movement of the heart.

**Fibrous pericardium**

The fibrous pericardium is a tough, inelastic sheath which fixes the heart in position (through its attachments to the central tendon of the diaphragm, the sternum and the tunica adventitia of the great vessels) and prevents sudden overfilling and distension of the heart.

Cardiac tamponade is acute compression of the heart caused by rapid accumulation of fluid or blood in the pericardial cavity from trauma (to the heart, great vessels or pericardial vessels) or pericardial effusion. The inflexibility of the fibrous pericardium results in increased intrapericardial pressure, with subsequent compression of venous return and reduced cardiac output.

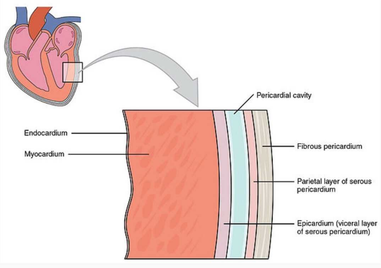


By OpenStax College [CC BY 3.0 (http://creativecommons.org/licenses/by/3.0)], via Wikimedia Commons

**Innervation**

The pericardium receives its nerve supply from the vagus nerve, the sympathetic trunks and the phrenic nerves.

Somatic sensation from the parietal pericardium is carried by somatic afferent fibres in the phrenic nerves (C3 – C5); it is for this reason that pain related to a pericardial problem may be referred to the supraclavicular region of the shoulder or the lateral neck area dermatomes for spinal cord segments C3 – C5.

**Pericardial aspiration (pericardiocentesis)**

Pericardiocentesis is a surgical puncture of the pericardial cavity for the aspiration of fluid, which is necessary to relieve the pressure of accumulated fluid in the heart.

A needle is inserted into the pericardial cavity 1 – 2 cm inferior to the left of the xiphochondral junction (between the xiphisternum and the left costal margin) at a 45 degree angle and advanced aiming toward the tip of the left scapula (site marked by cross in image below).

Complications of pericardiocentesis include:

- Aspiration of ventricular blood instead of pericardial blood
- Laceration of ventricular epicardium or myocardium
- Laceration of coronary artery or vein
- Ventricular fibrillation
- Pneumothorax secondary to lung puncture
- Puncture of great vessels with worsening pericardial tamponade
- Mediastinitis secondary to oesophageal puncture

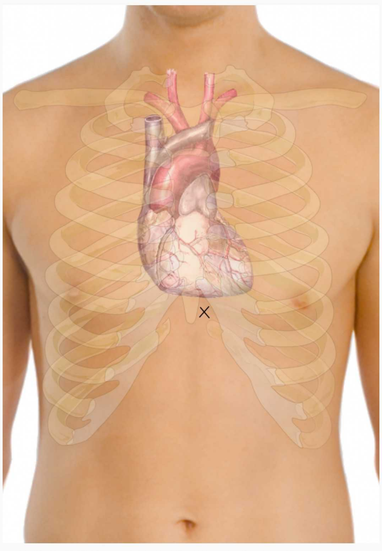

Modified by FRCEM Success. Original by Mikael Häggström (See above. All used images are in public domain.) [Public domain], via Wikimedia Commons

< Previous | Next >

Something wrong?

## Question Navigator

1 Answered
2 Answered
3 Answered
4 Answered
5 Answered
6 Answered
7 Answered
8 Answered
9 Current Question
10 ...
11 ...
12 ...



©2014 - 2017 FRCEM Success | Website designed & hosted by Cyberfrog Design

# Anatomy: Thorax

Question 10 of 134

## The hila of the lungs are located at the level of which of the following costal cartilages:

a 2nd – 3rd

b 3rd – 4th

c 3rd – 6th

d 5th – 6th

e 4th – 6th

< Previous | Next > | See Answer

Something wrong?

Question Navigator

1 Answered
2 Answered
3 Answered
4 Answered
5 Answered
6 Answered
7 Answered
8 Answered
9 Answered
10 Current Question
11 ...
12 ...



©2014 - 2017 FRCEM Success | Website designed & hosted by Cyberfrog Design

# Anatomy: Thorax

Question 10 of 134

The hila of the lungs are located at the level of which of the following costal cartilages:

**a)** 2nd – 3rd
**b)** 3rd – 4th ✔
**c)** 3rd – 6th
**d)** 5th – 6th
**e)** 4th – 6th ✖

## Answer

The hila are located at the level of the 3rd – 4th costal cartilage anteriorly, and the T5 – T7 vertebrae posteriorly.

## Notes

The lungs lie on either side of the mediastinum, each surrounded by a pleural cavity. They are suspended from the mediastinum by the root of the lung, a short tubular collection of structures.

**Lung root**

The root is lined by a layer of mediastinal pleura that reflects onto the surface of the lungs as visceral pleura. The region outlined by this pleural reflection on the medial surface of the lung is the hilum, where structures enter and leave.

The hila are located at the level of the 3rd – 4th costal cartilage anteriorly, and the T5 – T7 vertebrae posteriorly.

Each lung root contains:

- a pulmonary artery
- two pulmonary veins
- a main bronchus
- bronchial vessels,
- nerves and
- lymphatics.

Generally the pulmonary artery is superior in the lung root, the pulmonary veins are inferior and the bronchi are somewhat posterior in position.

In the mediastinum, the vagus nerves pass immediately posteriorly to the lung roots, while the phrenic nerves pass immediately anterior to them.

On the right side, the lobar bronchus to the superior lobe branches from the main bronchus in the root, whereas on the left, it branches within the lung itself.

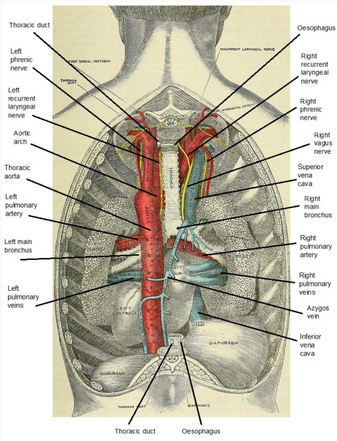


Modified by FRCEM Success. Original by Gray, Henry, 1825-1861; Carter, H. V. (Henry Vandyke), 1831-1897; Pick, T. Pickering [Thomas Pickering], 1841-1919 [No restrictions], via Wikimedia Commons

**Relations**

The medial surface of the right lung lies adjacent to:

- the heart
- the inferior vena cava
- the superior vena cava
- the azygos vein
- the oesophagus

The medial surface of the left lung lies adjacent to:

- the heart
- the aortic arch
- the thoracic aorta
- the oesophagus.

The right and left subclavian arteries and veins arch over and are related to the superior lobe of the right and left lung as they pass over the dome of the cervical pleura and into the axilla.

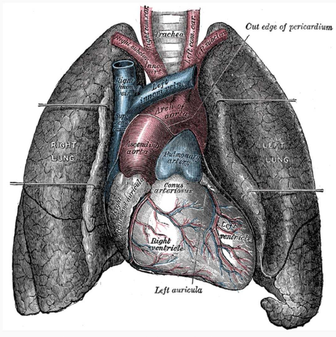


By Henry Vandyke Carter [Public domain], via Wikimedia Commons

**Blood supply**

The right and left pulmonary arteries originate from the pulmonary trunk (at the vertebral level T4/T5) and carry deoxygenated blood to the lungs.

On each side a superior and inferior pulmonary vein carries oxygenated blood from the lungs back to the heart.

The bronchi (down to the terminal bronchioles), lung roots, visceral pleura and supporting lung tissues receive their nutrient blood supply from the bronchial arteries, which arise from the descending aorta.

**Lymphatics**

Lymph from the lungs drains via hilar, tracheobronchial and mediastinal lymph nodes.

**Innervation**

The nerve supply to the lungs is from the anterior and posterior pulmonary plexus (networks of nerves derived from the sympathetic trunk and vagus nerve).

The parasympathetic nerve supply, carried by the vagus nerve, stimulates secretion from the bronchial glands, contraction of bronchial smooth muscle, and vasodilation of the pulmonary vessels. The vagus nerve also carries afferent fibres of pain, cough reflex and stretch of the lung (during inspiration).

The sympathetic nerve supply stimulates relaxation of bronchial smooth muscle, and vasoconstriction of the pulmonary vessels.

< Previous | Next >

Something wrong?

## Question Navigator

1 Answered
2 Answered
3 Answered
4 Answered
5 Answered
6 Answered
7 Answered
8 Answered
9 Answered
10 Current Question
11 ...
12 ...



©2014 - 2017 FRCEM Success | Website designed & hosted by Cyberfrog Design

# Anatomy: Thorax

Question 11 of 134

## The anterior surface of the heart is formed predominantly by which of the following:

a Right atrium

b Left atrium

c Right ventricle

d Left ventricle

e Great vessels

< Previous | Next > | See Answer

Something wrong?

Question Navigator

1 Answered
2 Answered
3 Answered
4 Answered
5 Answered
6 Answered
7 Answered
8 Answered
9 Answered
10 Answered
11 Current Question
12 ...



©2014 - 2017 FRCEM Success | Website designed & hosted by Cyberfrog Design

# Anatomy: Thorax

Question 11 of 134

The anterior surface of the heart is formed predominantly by which of the following:

**a)** Right atrium
**b)** Left atrium
**c)** **Right ventricle** ✔
**d)** Left ventricle
**e)** Great vessels

## Answer

The anterior (sternocostal) surface consists mostly of the right ventricle with some of the right atrium and some of the left ventricle.

## Notes

| Border/Surface | Main structure (contributing structures) |
|---|---|
| Apex | Left ventricle |
| Base | Left atrium (right atrium, proximal great veins) |
| Anterior surface | Right ventricle (right atrium, left ventricle) |
| Inferior surface | Left and right ventricle |
| Left pulmonary surface | Left ventricle (left atrium) |
| Right pulmonary surface | Right atrium |
| Inferior border | Right ventricle (left ventricle) |
| Left border | Left ventricle (left auricle) |
| Right border | Right atrium |
| Superior border | Both atria, roots of great vessels |

The general shape and orientation of the heart are that of a pyramid that has fallen over and is resting on one of its sides.

- The apex of this pyramid projects forwards, downwards and to the left. The apex is formed by the inferolateral part of the left ventricle and is positioned deep to the left fifth intercostal space in the midclavicular line.
- The base is facing posteriorly. The base is formed mostly by the left atrium with a small portion of the right atrium and the proximal part of the great veins, and is fixed posteriorly to the pericardial wall, opposite the bodies of the T5 – T8 vertebrae (T6 – T9 when standing). The oesophagus lies immediately posterior to the base.

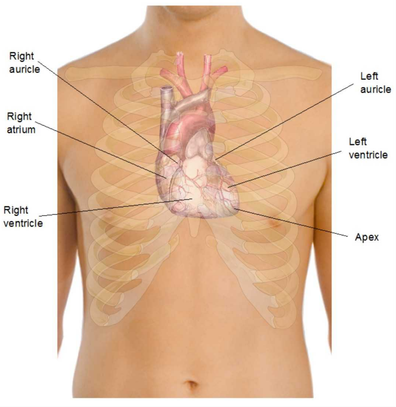


Modified by FRCEM Success. Original by Mikael Häggström (See above. All used images are in public domain.) [Public domain], via Wikimedia Commons

**Surfaces**

There are four surfaces to the upturned pyramid:

- The anterior (sternocostal) surface consists mostly of the right ventricle with some of the right atrium and some of the left ventricle.
- The inferior (diaphragmatic) surface consists of the left ventricle with a small portion of the right ventricle separated by the posterior interventricular groove.
- The left pulmonary surface consists mainly of the left ventricle and a portion of the left atrium.
- The right pulmonary surface consists of the right atrium.

**Borders**

There are four main borders separating the surfaces of the heart:

- The inferior border is formed mostly by the right ventricle and a small portion of the left ventricle near the apex.
- The left border is formed mostly by the left ventricle with a small portion of the left auricle.
- The right border is formed by the right atrium.
- The superior border is formed by both atria and the roots of the great vessels.

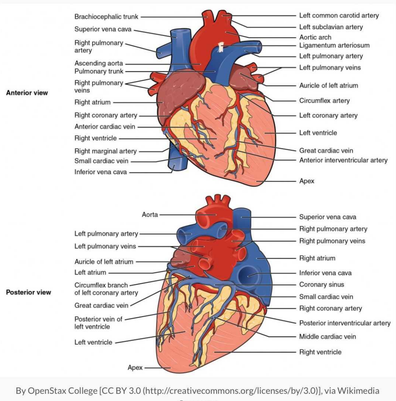


By OpenStax College [CC BY 3.0 (http://creativecommons.org/licenses/by/3.0)], via Wikimedia Commons

< Previous | Next >

Something wrong?

## Question Navigator

1 Answered
2 Answered
3 Answered
4 Answered
5 Answered
6 Answered
7 Answered
8 Answered
9 Answered
10 Answered
11 Current Question
12 ...



©2014 - 2017 FRCEM Success | Website designed & hosted by Cyberfrog Design

# Anatomy: Thorax

Question 12 of 134

## The trachea is lined with which type of epithelium:

a Simple columnar epithelium

b Stratified cuboidal epithelium

c Squamous epithelium

d Transitional epithelium

e Pseudostratified columnar epithelium

< Previous | Next > | See Answer

Something wrong?

Question Navigator

1 Answered
2 Answered
3 Answered
4 Answered
5 Answered
6 Answered
7 Answered
8 Answered
9 Answered
10 Answered
11 Answered
12 Current Question



©2014 - 2017 FRCEM Success | Website designed & hosted by Cyberfrog Design

# Anatomy: Thorax

Question 12 of 134

The trachea is lined with which type of epithelium:

**a)** Simple columnar epithelium
**b)** Stratified cuboidal epithelium
**c)** Squamous epithelium
**d)** Transitional epithelium
**e)** **Pseudostratified columnar epithelium** ✔

## Answer

The trachea and bronchi are lined by ciliated pseudostratified columnar epithelium.

## Notes

The trachea arises at the lower border of the cricoid cartilage in the neck, as a continuation of the larynx. It extends from vertebral level C6 to T4/T5 at which point it bifurcates into the right and left main bronchi (at the level of the sternal angle).

The trachea is formed anteriorly by 15 – 20 C-shaped rings of hyaline cartilage which mechanically hold the airway open whilst allowing it flexibility. The trachealis muscle connects the ends of the incomplete rings and forms the posterior wall of the trachea. The trachealis muscle is able to constrict the trachea, allowing air to be expelled with more force e.g. during coughing.

The trachea and bronchi are lined by ciliated pseudostratified columnar epithelium, interspersed by mucus-producing goblet cells. This mucous membrane functions as the mucociliary escalator, trapping particles in sticky mucus and sweeping it along the airway.

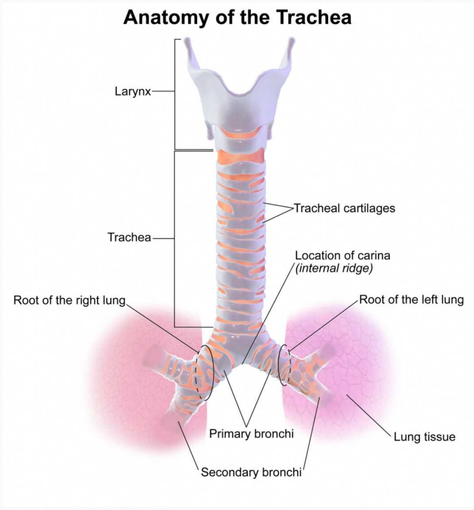


By Blausen.com staff. "Blausen gallery 2014". Wikiversity Journal of Medicine. DOI:10.15347/wjm/2014.010. ISSN 20018762. (Own work) [CC BY 3.0 (http://creativecommons.org/licenses/by/3.0)], via Wikimedia Commons

**Relations**

The trachea descends anterior to the oesophagus and inclines slightly to the right.

In the thorax, anteriorly it is related to:

- the thymic remnants
- the left brachiocephalic vein
- the aortic arch
- the brachiocephalic trunk
- the left common carotid artery
- the deep cardiac plexus.

Laterally it is related to:

- the pleura, the right vagus nerve and the brachiocephalic trunk on the right
- the left recurrent laryngeal nerve, the aortic arch and the left common carotid and subclavian vessels on the left.

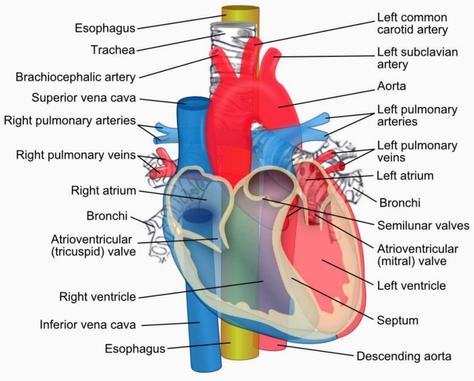


ZooFari [CC BY-SA 3.0 (http://creativecommons.org/licenses/by-sa/3.0)], via Wikimedia Commons

< Previous | Next > | Something wrong?

## Question Navigator

1 Answered
2 Answered
3 Answered
4 Answered
5 Answered
6 Answered
7 Answered
8 Answered
9 Answered
10 Answered
11 Answered
12 Current Question



©2014 - 2017 FRCEM Success | Website designed & hosted by Cyberfrog Design

# Anatomy: Thorax

Question 13 of 134

## The oesophagus ends at which of the following vertebral levels:

a T8

b T9

c T10

d T11

e T12

< Previous | Next > | See Answer

Something wrong?

Question Navigator

1 Answered
2 Answered
3 Answered
4 Answered
5 Answered
6 Answered
7 Answered
8 Answered
9 Answered
10 Answered
11 Answered
12 Answered



©2014 - 2017 FRCEM Success | Website designed & hosted by Cyberfrog Design

# Anatomy: Thorax

Question 13 of 134

The oesophagus ends at which of the following vertebral levels:

a) T8
b) T9
c) T10 ✗
d) T11 ✓
e) T12

## Answer

The oesophagus begins at the inferior border of the cricoid cartilage opposite vertebra C6, pierces the diaphragm at the esophageal hiatus at T10 and ends at the cardiac opening of the stomach opposite vertebra T11.

## Notes

**Anatomical extent**

The oesophagus is a muscular tube passing between the pharynx in the neck and the stomach in the abdomen. The oesophagus begins at the inferior border of the cricoid cartilage opposite vertebra C6, pierces the diaphragm at the esophageal hiatus at T10 and ends at the cardiac opening of the stomach opposite vertebra T11.

**Structure**

The oesophagus consists of an internal circular and external longitudinal layer of muscle. The external longitudinal layer is comprised of different muscle types in each third of the oesophagus; superior third – voluntary striated muscle, middle third – voluntary striated and smooth muscle and inferior third – smooth muscle.

**Relations**

The oesophagus descends on the anterior aspect of the bodies of the vertebrae, immediately posterior to the trachea and the recurrent laryngeal nerves, generally in the midline position. The oesophagus is crossed anteriorly by the aortic arch. As it approaches the diaphragm, the oesophagus moves anteriorly and to the left, crossing from the right side of the thoracic aorta to eventually assume a position anterior to it, before passing through the diaphragm.

Posterior to the oesophagus, the thoracic duct is on the right side inferiorly but crosses to the left more superiorly (at T5). Other structures posteriorly include portions of the hemiazygos veins and the right posterior intercostal vessels.

Anterior to the oesophagus below the tracheal bifurcation are the right pulmonary artery and the left main bronchus. The oesophagus then passes immediately posterior to the left atrium, separated from it only by pericardium. Inferior to the left atrium, the oesophagus is related to the diaphragm.

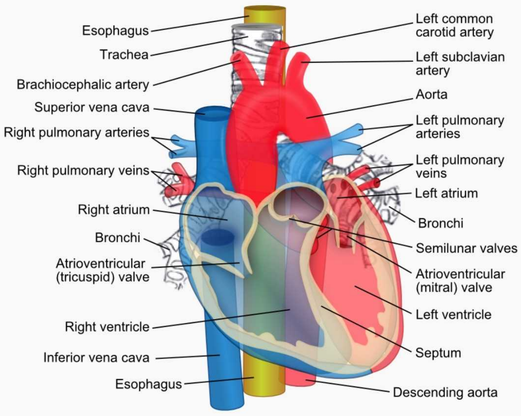


ZooFari [CC BY-SA 3.0 (http://creativecommons.org/licenses/by-sa/3.0)], via Wikimedia Commons

**Points of constriction**

As the oesophagus is a flexible muscular tube, it is compressed by surrounding structures at four locations:

- 1) the junction of the oesophagus with the pharynx in the neck (upper oesophageal sphincter formed by the cricopharyngeus muscle)
- 2) in the superior mediastinum where the oesophagus is crossed by the arch of the aorta
- 3) in the posterior mediastinum where the oesophagus is compressed by the left main bronchus
- 4) in the posterior mediastinum at the oesophageal hiatus in the diaphragm.

Clinically these compressions are important when passing instruments or assessing swallowed objects.

**Innervation**

Oesophageal innervation is complex, oesophageal branches arise from the vagus nerves and sympathetic trunks. The visceral afferents that pass through the sympathetic trunks and the splanchnic nerves are the primary participants in detection of oesophageal pain and transmission of this information to various levels of the central nervous system.

< Previous | Next >

Something wrong?

## Question Navigator

1 Answered
2 Answered
3 Answered
4 Answered
5 Answered
6 Answered
7 Answered
8 Answered
9 Answered
10 Answered
11 Answered
12 Answered



©2014 - 2017 FRCEM Success | Website designed & hosted by Cyberfrog Design

# Anatomy: Thorax

Question 14 of 134

## A 28 year old man is brought to ED with a penetrating chest wall injury in the area of the fourth costal cartilage. Which of the following pulmonary structures is present at this site:

a Right oblique fissure

b Left oblique fissure

c Right horizontal fissure

d Left horizontal fissure

e Lung apex

< Previous | Next > | See Answer

Something wrong?

## Question Navigator

1 Answered
2 Answered
3 Answered
4 Answered
5 Answered
6 Answered
7 Answered
8 Answered
9 Answered
10 Answered
11 Answered
12 Answered



©2014 - 2017 FRCEM Success | Website designed & hosted by Cyberfrog Design

# Anatomy: Thorax

Question 14 of 134

A 28 year old man is brought to ED with a penetrating chest wall injury in the area of the fourth costal cartilage. Which of the following pulmonary structures is present at this site:

**a)** Right oblique fissure
**b)** Left oblique fissure
**c)** **Right horizontal fissure** ✔
**d)** Left horizontal fissure
**e)** Lung apex

## Answer

The horizontal fissure (separating the right superior and middle lobes) extends medially from the oblique fissure at the level of the 5th rib in the midaxillary line to the sternum, along the lower border of the fourth rib.

## Notes

The lungs lie on either side of the mediastinum, each surrounded by a pleural cavity. The right lung is normally a little larger than the left lung because the middle mediastinum, containing the heart, bulges more to the left than to the right.

**Lobes and fissures**

The right lung has three lobes and two fissures; the oblique fissure separates the inferior lobe from the superior and middle lobe whilst the horizontal fissure separates the superior lobe from the middle lobe.

The left lung has two lobes separated by the oblique fissure.

The oblique fissure may be an evolutionary development to permit greater transmission of diaphragmatic excursions to the superior lobe. In this way the upper lobe can expand to a relatively greater extent for a given increase in the superoinferior diameter of the pleural cavity.

**Surface marking**

The inferior margin of the lung in quiet respiration is a line that runs between rib 6 in the midclavicular line, rib 8 in the midaxillary line and vertebra T10 posteriorly.

In quiet respiration, the approximate position of the right oblique fissure can be marked by a line on the thoracic wall that begins at the spinous process of vertebra T4, crosses the fifth intercostal space laterally and then follows the contour of rib 6 anteriorly. The horizontal fissure follows the fourth intercostal space from the sternum until it meets the oblique fissure as it crosses rib 5.

The oblique fissure in the left lung is slightly more oblique than the corresponding fissure in the right lung. In quiet respiration, the approximate position of the oblique fissure can be marked by a line on the thoracic wall that begins between the spinous processes of vertebrae T3 and T4, crosses the fifth intercostal space laterally and then follows the contour of rib 6 anteriorly.

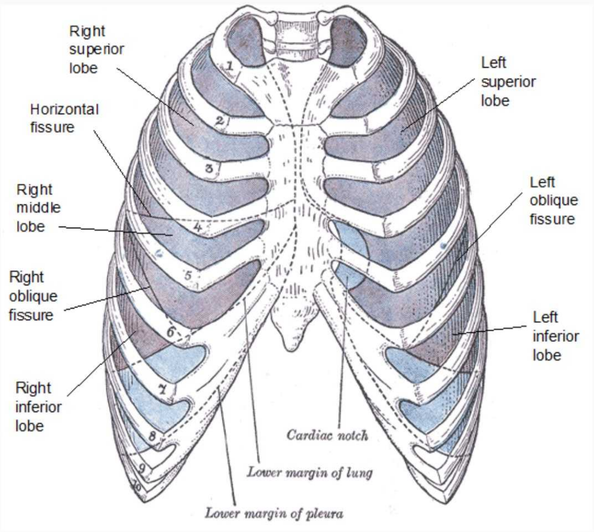


Modified by FRCEM Success. Original by Henry Vandyke Carter [Public domain], via Wikimedia Commons

## Question Navigator

1 Answered
2 Answered
3 Answered
4 Answered
5 Answered
6 Answered
7 Answered
8 Answered
9 Answered
10 Answered
11 Answered
12 Answered

< Previous | Next > | Something wrong?



©2014 - 2017 FRCEM Success | Website designed & hosted by Cyberfrog Design

# Anatomy: Thorax

Question 15 of 134

## Which of the following structures pass through the aortic opening in the diaphragm:

a Aorta and vagus nerve

b Aortic and thoracic duct

c Aorta and phrenic nerve

d Aorta and inferior vena cava

e Aorta and recurrent laryngeal nerve

< Previous | Next > | See Answer

Something wrong?

Question Navigator

1 Answered
2 Answered
3 Answered
4 Answered
5 Answered
6 Answered
7 Answered
8 Answered
9 Answered
10 Answered
11 Answered
12 Answered



©2014 - 2017 FRCEM Success | Website designed & hosted by Cyberfrog Design

# Anatomy: Thorax

Question 15 of 134

Which of the following structures pass through the aortic opening in the diaphragm:

a) Aorta and vagus nerve
b) **Aortic and thoracic duct** ✔
c) Aorta and phrenic nerve
d) Aorta and inferior vena cava
e) Aorta and recurrent laryngeal nerve

## Answer

The aortic opening in the diaphragm is at vertebral level T12 and transmits the aorta, the thoracic duct and the azygos vein.

## Notes

The diaphragm is a musculotendinous structure that separates the thoracic cavity from the abdominal cavity.

| Structure | Diaphragm |
|---|---|
| Primary function | Respiration – contraction of diaphragm flattens diaphragm increasing vertical dimension of thorax (inspiration), relaxation of diaphragm elevates diaphragm decreasing vertical dimension of thorax (expiration) |
| Secondary functions | Assists in straining movements by increasing intra-abdominal pressure, acts as functional sphincter on oesophagus preventing acid reflux |
| Peripheral attachments | Xiphoid process of sternum, costal cartilages ribs 7 – 10, ends of ribs 11 and 12, arcuate ligaments and lumbar vertebrae |
| Central attachment | Fuses with fibrous pericardium superiorly |
| Surface markings | Attachments: vertebrae T8/T9 anteriorly, vertebra T12 posteriorly, Domes: right dome 5th rib, left dome 5th intercostal space |
| Openings | Oesophageal opening at T10 (oesophagus, vagus nerve), aortic opening at T12 (aorta, thoracic duct and azygos vein), caval opening at T8 (inferior vena cava and right phrenic nerve) |
| Innervation | Phrenic nerve (C3 – C5) |

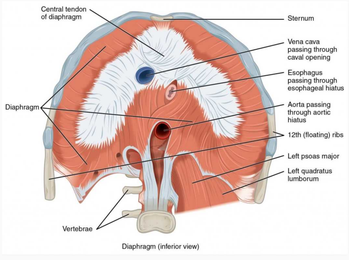


By OpenStax [CC BY 4.0 (http://creativecommons.org/licenses/by/4.0)], via Wikimedia Commons

### Function

The diaphragm performs an important function in respiration; contraction of the domes of the diaphragm in inspiration flattens the diaphragm, increasing the vertical dimension of the thorax and vice versa in expiration, with relaxation and elevation of the diaphragm reducing the vertical dimension of the thorax.

The diaphragm is also involved in non-respiratory functions; helping to expel vomit, faeces, and urine from the body by increasing intraabdominal pressure, and preventing acid reflux by exerting pressure on the oesophagus as it passes through the oesophageal opening.

### Attachments

The diaphragm is attached peripherally to:

- the xiphoid process of the sternum and the costal cartilages of ribs 7 – 10 (the costal margin) anteriorly
- the ends of ribs 11 and 12 laterally
- the arcuate ligaments and vertebrae posteriorly.

From these peripheral attachments, muscle fibres converge to form the central tendon which fuses with the fibrous pericardium superiorly.

### Surface markings

In the medial sagittal plane, the diaphragm slopes inferiorly from its anterior attachment to the xiphoid at approximately vertebral level T8/T9 to its posterior attachment to the median arcuate ligament at approximately vertebral level T12.

At rest the right dome of the diaphragm lies slightly higher than the left; this is thought to be due to the position of the liver. In normal expiration, the normal upper limits of the superior margins are the fifth rib for the right dome, the fifth intercostal space for the left dome and the xiphoid process for the central tendon.

### Diaphragmatic openings

Structures travelling between the thorax and abdomen must pass through the diaphragm via three main openings.

The oesophageal opening at vertebral level T10 transmits:

- the oesophagus
- the anterior and posterior vagal trunks
- oesophageal branches of the left gastric vessels
- a few lymphatics.

The aortic opening at vertebral level T12 transmits:

- the aorta
- the thoracic duct
- the azygos vein and sometimes the hemiazygos vein.

The caval opening at vertebral level T8 transmits:

- the inferior vena cava
- the right phrenic nerve.

### Innervation

The entire motor supply of the diaphragm is from the right and left phrenic nerves (C3 – C5) which penetrate the diaphragm and innervate it from its abdominal surface.

Damage to the phrenic nerve will result in hemiparalysis of the diaphragm. Paralysis of the diaphragm produces a paradoxical movement. The affected side of the diaphragm moves upwards during inspiration (as it is pushed superiorly by the abdominal viscera that are being actively compressed by the other half), and downwards during expiration.

A unilateral diaphragmatic paralysis is usually asymptomatic, and is most often an incidental finding on x-ray. If both sides are paralysed, the patient may experience poor exercise tolerance, orthopnoea and fatigue. Lung function tests will show a restrictive deficit.

### Diaphragmatic herniation

Diaphragmatic hernias are defined as congenital or acquired defects in the diaphragm. There are two main types of congenital diaphragmatic hernias; Bochdalek hernias and Morgagni hernias.

Acquired diaphragmatic hernias include traumatic diaphragmatic rupture, hiatus hernia and iatrogenic diaphragmatic hernias. Depending on the location and size of the defect, retroperitoneal or intra-abdominal organs and tissues can prolapse into the thoracic cavity due to the negative intrathoracic pressure.

Diaphragmatic rupture usually results from blunt abdominal trauma, which is typically associated with motor-vehicle accidents; the most commonly herniated viscera are the stomach and colon on the left side, and the liver on the right side.

In hiatus hernia, the stomach herniates through the oesophageal opening of the diaphragm, typically resulting in symptoms of acid reflux.

< Previous | Next >

Something wrong?

## Question Navigator

1 Answered
2 Answered
3 Answered
4 Answered
5 Answered
6 Answered
7 Answered
8 Answered
9 Answered
10 Answered
11 Answered
12 Answered



©2014 - 2017 FRCEM Success | Website designed & hosted by Cyberfrog Design

# Anatomy: Thorax

Question 16 of 134

## The aortic opening in the diaphragm is found at which thoracic level:

a T8

b T9

c T10

d T11

e T12

< Previous | Next > | See Answer

Something wrong?

## Question Navigator

1 Answered
2 Answered
3 Answered
4 Answered
5 Answered
6 Answered
7 Answered
8 Answered
9 Answered
10 Answered
11 Answered
12 Answered



©2014 - 2017 FRCEM Success | Website designed & hosted by Cyberfrog Design

# Anatomy: Thorax

Question 16 of 134

The aortic opening in the diaphragm is found at which thoracic level:

**a)** T8
**b)** T9
**c)** T10
**d)** T11
**e)** **T12** ✔

## Answer

The aortic opening in the diaphragm is at vertebral level T12 and transmits the aorta, the thoracic duct and the azygos vein.

## Notes

The diaphragm is a musculotendinous structure that separates the thoracic cavity from the abdominal cavity.

| Structure | Diaphragm |
|---|---|
| Primary function | Respiration – contraction of diaphragm flattens diaphragm increasing vertical dimension of thorax (inspiration), relaxation of diaphragm elevates diaphragm decreasing vertical dimension of thorax (expiration) |
| Secondary functions | Assists in straining movements by increasing intra-abdominal pressure, acts as functional sphincter on oesophagus preventing acid reflux |
| Peripheral attachments | Xiphoid process of sternum, costal cartilages ribs 7 – 10, ends of ribs 11 and 12, arcuate ligaments and lumbar vertebrae |
| Central attachment | Fuses with fibrous pericardium superiorly |
| Surface markings | Attachments: vertebrae T8/T9 anteriorly, vertebra T12 posteriorly, Domes: right dome 5th rib, left dome 5th intercostal space |
| Openings | Oesophageal opening at T10 (oesophagus, vagus nerve), aortic opening at T12 (aorta, thoracic duct and azygos vein), caval opening at T8 (inferior vena cava and right phrenic nerve) |
| Innervation | Phrenic nerve (C3 – C5) |

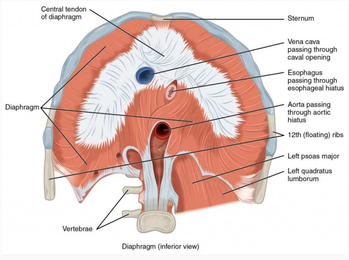


By OpenStax [CC BY 4.0 (http://creativecommons.org/licenses/by/4.0)], via Wikimedia Commons

**Function**

The diaphragm performs an important function in respiration; contraction of the domes of the diaphragm in inspiration flattens the diaphragm, increasing the vertical dimension of the thorax and vice versa in expiration, with relaxation and elevation of the diaphragm reducing the vertical dimension of the thorax.

The diaphragm is also involved in non-respiratory functions; helping to expel vomit, faeces, and urine from the body by increasing intraabdominal pressure, and preventing acid reflux by exerting pressure on the oesophagus as it passes through the oesophageal opening.

**Attachments**

The diaphragm is attached peripherally to:

- the xiphoid process of the sternum and the costal cartilages of ribs 7 – 10 (the costal margin) anteriorly
- the ends of ribs 11 and 12 laterally
- the arcuate ligaments and vertebrae posteriorly.

From these peripheral attachments, muscle fibres converge to form the central tendon which fuses with the fibrous pericardium superiorly.

**Surface markings**

In the medial sagittal plane, the diaphragm slopes inferiorly from its anterior attachment to the xiphoid at approximately vertebral level T8/T9 to its posterior attachment to the median arcuate ligament at approximately vertebral level T12.

At rest the right dome of the diaphragm lies slightly higher than the left; this is thought to be due to the position of the liver. In normal expiration, the normal upper limits of the superior margins are the fifth rib for the right dome, the fifth intercostal space for the left dome and the xiphoid process for the central tendon.

**Diaphragmatic openings**

Structures travelling between the thorax and abdomen must pass through the diaphragm via three main openings.

The oesophageal opening at vertebral level T10 transmits:

- the oesophagus
- the anterior and posterior vagal trunks
- oesophageal branches of the left gastric vessels
- a few lymphatics.

The aortic opening at vertebral level T12 transmits:

- the aorta
- the thoracic duct
- the azygos vein and sometimes the hemiazygos vein.

The caval opening at vertebral level T8 transmits:

- the inferior vena cava
- the right phrenic nerve.

**Innervation**

The entire motor supply of the diaphragm is from the right and left phrenic nerves (C3 – C5) which penetrate the diaphragm and innervate it from its abdominal surface.

Damage to the phrenic nerve will result in hemiparalysis of the diaphragm. Paralysis of the diaphragm produces a paradoxical movement. The affected side of the diaphragm moves upwards during inspiration (as it is pushed superiorly by the abdominal viscera that are being actively compressed by the other half), and downwards during expiration.

A unilateral diaphragmatic paralysis is usually asymptomatic, and is most often an incidental finding on x-ray. If both sides are paralysed, the patient may experience poor exercise tolerance, orthopnoea and fatigue. Lung function tests will show a restrictive deficit.

**Diaphragmatic herniation**

Diaphragmatic hernias are defined as congenital or acquired defects in the diaphragm. There are two main types of congenital diaphragmatic hernias; Bochdalek hernias and Morgagni hernias.

Acquired diaphragmatic hernias include traumatic diaphragmatic rupture, hiatus hernia and iatrogenic diaphragmatic hernias. Depending on the location and size of the defect, retroperitoneal or intra-abdominal organs and tissues can prolapse into the thoracic cavity due to the negative intrathoracic pressure.

Diaphragmatic rupture usually results from blunt abdominal trauma, which is typically associated with motor-vehicle accidents; the most commonly herniated viscera are the stomach and colon on the left side, and the liver on the right side.

In hiatus hernia, the stomach herniates through the oesophageal opening of the diaphragm, typically resulting in symptoms of acid reflux.

< Previous | Next >

Something wrong?

## Question Navigator

1 Answered
2 Answered
3 Answered
4 Answered
5 Answered
6 Answered
7 Answered
8 Answered
9 Answered
10 Answered
11 Answered
12 Answered



©2014 - 2017 FRCEM Success | Website designed & hosted by Cyberfrog Design

# Anatomy: Thorax

Question 17 of 134

## The ascending aorta arises from the aortic orifice at the base of the left ventricle at which of the following locations:

a Posterior to the left half of the sternum at the level of the third costal cartilage

b Posterior to the right half of the sternum at the level of the third costal cartilage

c Posterior to the left half of the sternum at the level of the fourth costal cartilage

d Posterior to the right half of the sternum at the level of the fourth costal cartilage

e Posterior to the left half of the sternum at the level of the second costal cartilage

< Previous | Next > | See Answer

Something wrong?

Question Navigator

1 Answered
2 Answered
3 Answered
4 Answered
5 Answered
6 Answered
7 Answered
8 Answered
9 Answered
10 Answered
11 Answered
12 Answered



©2014 - 2017 FRCEM Success | Website designed & hosted by Cyberfrog Design

# Anatomy: Thorax

Question 17 of 134

The ascending aorta arises from the aortic orifice at the base of the left ventricle at which of the following locations:

a) **Posterior to the left half of the sternum at the level of the third costal cartilage** ✔
b) Posterior to the right half of the sternum at the level of the third costal cartilage
c) Posterior to the left half of the sternum at the level of the fourth costal cartilage
d) Posterior to the right half of the sternum at the level of the fourth costal cartilage
e) Posterior to the left half of the sternum at the level of the second costal cartilage

## Answer

The ascending aorta arises from the aortic orifice at the base of the left ventricle, at the level of the lower edge of the third left costal cartilage, posterior to the left half of the sternum.

## Notes

The ascending aorta arises from the aortic orifice at the base of the left ventricle, at the level of the lower edge of the third left costal cartilage, posterior to the left half of the sternum. The ascending aorta ascends, moving slightly forwards and to the right, before continuing as the arch of the aorta posterior to the second right costal cartilage.

The pulmonary trunk arises from the conus arteriosus of the right ventricle slightly anterior to the aortic orifice, posterior to the left third costal cartilage. The pulmonary trunk ascends, moving posteriorly and to the left, lying initially anterior and then to the left of the ascending aorta, before bifurcating into the right and left pulmonary arteries posterior to the left second intercostal space.

The pulmonary trunk and the ascending aorta are contained within the pericardial sac, lined by serous pericardium and within a common sheath.

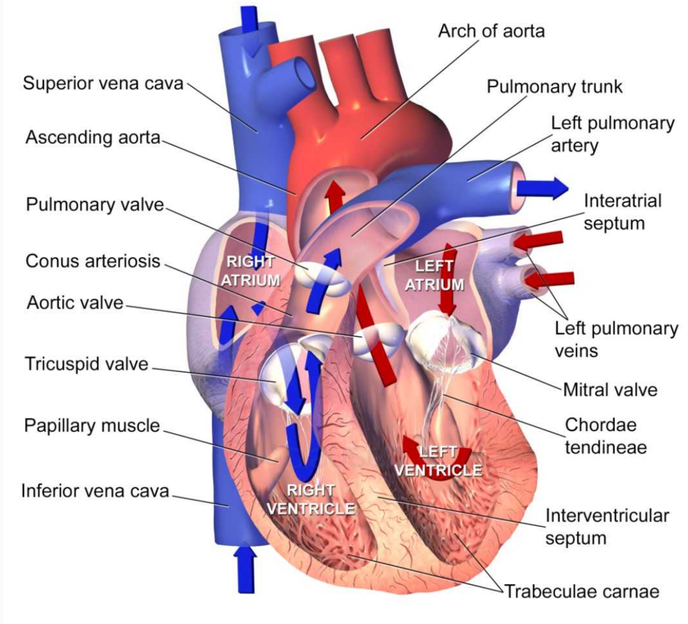


**Sectional Anatomy of the Heart**

By Blausen Medical Communications, Inc. [CC BY 3.0 (http://creativecommons.org/licenses/by/3.0)], via Wikimedia Commons

< Previous | Next > | Something wrong?

## Question Navigator

1 Answered
2 Answered
3 Answered
4 Answered
5 Answered
6 Answered
7 Answered
8 Answered
9 Answered
10 Answered
11 Answered
12 Answered



©2014 - 2017 FRCEM Success | Website designed & hosted by Cyberfrog Design

# Anatomy: Thorax

Question 18 of 134

## The caval opening in the diaphragm is found at which thoracic level:

a T8

b T9

c T10

d T11

e T12

< Previous | Next > | See Answer

Something wrong?

## Question Navigator

1 Answered
2 Answered
3 Answered
4 Answered
5 Answered
6 Answered
7 Answered
8 Answered
9 Answered
10 Answered
11 Answered
12 Answered



©2014 - 2017 FRCEM Success | Website designed & hosted by Cyberfrog Design

# Anatomy: Thorax

Question 18 of 134

The caval opening in the diaphragm is found at which thoracic level:

**a)** **T8** ✔
**b)** T9
**c)** T10
**d)** T11
**e)** T12

## Answer

The caval opening in the diaphragm is at vertebral level T8 and transits the inferior vena cava and the right phrenic nerve.

## Notes

The diaphragm is a musculotendinous structure that separates the thoracic cavity from the abdominal cavity.

| Structure | Diaphragm |
|---|---|
| Primary function | Respiration – contraction of diaphragm flattens diaphragm increasing vertical dimension of thorax (inspiration), relaxation of diaphragm elevates diaphragm decreasing vertical dimension of thorax (expiration) |
| Secondary functions | Assists in straining movements by increasing intra-abdominal pressure, acts as functional sphincter on oesophagus preventing acid reflux |
| Peripheral attachments | Xiphoid process of sternum, costal cartilages ribs 7 – 10, ends of ribs 11 and 12, arcuate ligaments and lumbar vertebrae |
| Central attachment | Fuses with fibrous pericardium superiorly |
| Surface markings | Attachments: vertebrae T8/T9 anteriorly, vertebra T12 posteriorly, Domes: right dome 5th rib, left dome 5th intercostal space |
| Openings | Oesophageal opening at T10 (oesophagus, vagus nerve), aortic opening at T12 (aorta, thoracic duct and azygos vein), caval opening at T8 (inferior vena cava and right phrenic nerve) |
| Innervation | Phrenic nerve (C3 – C5) |

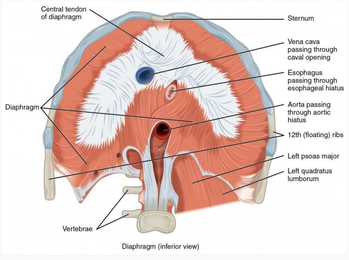


By OpenStax [CC BY 4.0 (http://creativecommons.org/licenses/by/4.0)], via Wikimedia Commons

### Function

The diaphragm performs an important function in respiration; contraction of the domes of the diaphragm in inspiration flattens the diaphragm, increasing the vertical dimension of the thorax and vice versa in expiration, with relaxation and elevation of the diaphragm reducing the vertical dimension of the thorax.

The diaphragm is also involved in non-respiratory functions; helping to expel vomit, faeces, and urine from the body by increasing intraabdominal pressure, and preventing acid reflux by exerting pressure on the oesophagus as it passes through the oesophageal opening.

### Attachments

The diaphragm is attached peripherally to:

- the xiphoid process of the sternum and the costal cartilages of ribs 7 – 10 (the costal margin) anteriorly
- the ends of ribs 11 and 12 laterally
- the arcuate ligaments and vertebrae posteriorly.

From these peripheral attachments, muscle fibres converge to form the central tendon which fuses with the fibrous pericardium superiorly.

### Surface markings

In the medial sagittal plane, the diaphragm slopes inferiorly from its anterior attachment to the xiphoid at approximately vertebral level T8/T9 to its posterior attachment to the median arcuate ligament at approximately vertebral level T12.

At rest the right dome of the diaphragm lies slightly higher than the left; this is thought to be due to the position of the liver. In normal expiration, the normal upper limits of the superior margins are the fifth rib for the right dome, the fifth intercostal space for the left dome and the xiphoid process for the central tendon.

### Diaphragmatic openings

Structures travelling between the thorax and abdomen must pass through the diaphragm via three main openings.

The oesophageal opening at vertebral level T10 transmits:

- the oesophagus
- the anterior and posterior vagal trunks
- oesophageal branches of the left gastric vessels
- a few lymphatics.

The aortic opening at vertebral level T12 transmits:

- the aorta
- the thoracic duct
- the azygos vein and sometimes the hemiazygos vein.

The caval opening at vertebral level T8 transmits:

- the inferior vena cava
- the right phrenic nerve.

### Innervation

The entire motor supply of the diaphragm is from the right and left phrenic nerves (C3 – C5) which penetrate the diaphragm and innervate it from its abdominal surface.

Damage to the phrenic nerve will result in hemiparalysis of the diaphragm. Paralysis of the diaphragm produces a paradoxical movement. The affected side of the diaphragm moves upwards during inspiration (as it is pushed superiorly by the abdominal viscera that are being actively compressed by the other half), and downwards during expiration.

A unilateral diaphragmatic paralysis is usually asymptomatic, and is most often an incidental finding on x-ray. If both sides are paralysed, the patient may experience poor exercise tolerance, orthopnoea and fatigue. Lung function tests will show a restrictive deficit.

### Diaphragmatic herniation

Diaphragmatic hernias are defined as congenital or acquired defects in the diaphragm. There are two main types of congenital diaphragmatic hernias; Bochdalek hernias and Morgagni hernias.

Acquired diaphragmatic hernias include traumatic diaphragmatic rupture, hiatus hernia and iatrogenic diaphragmatic hernias. Depending on the location and size of the defect, retroperitoneal or intra-abdominal organs and tissues can prolapse into the thoracic cavity due to the negative intrathoracic pressure.

Diaphragmatic rupture usually results from blunt abdominal trauma, which is typically associated with motor-vehicle accidents; the most commonly herniated viscera are the stomach and colon on the left side, and the liver on the right side.

In hiatus hernia, the stomach herniates through the oesophageal opening of the diaphragm, typically resulting in symptoms of acid reflux.

Question Navigator

1 Answered
2 Answered
3 Answered
4 Answered
5 Answered
6 Answered
7 Answered
8 Answered
9 Answered
10 Answered
11 Answered
12 Answered

< Previous | Next >

Something wrong?



©2014 - 2017 FRCEM Success | Website designed & hosted by Cyberfrog Design

# Anatomy: Thorax

Question 19 of 134

## The pulmonary trunk bifurcates into the right and left pulmonary arteries posterior to the:

a Left first intercostal space

b Left second intercostal space

c Left third intercostal space

d Right second intercostal space

e Right first intercostal space

< Previous | Next > | See Answer

Something wrong?

Question Navigator

1 Answered
2 Answered
3 Answered
4 Answered
5 Answered
6 Answered
7 Answered
8 Answered
9 Answered
10 Answered
11 Answered
12 Answered



©2014 - 2017 FRCEM Success | Website designed & hosted by Cyberfrog Design

# Anatomy: Thorax

Question 19 of 134

The pulmonary trunk bifurcates into the right and left pulmonary arteries posterior to the:

a) Left first intercostal space
b) **Left second intercostal space** ✔
c) Left third intercostal space
d) Right second intercostal space
e) Right first intercostal space

## Answer

The pulmonary trunk ascends, moving posteriorly and to the left, lying initially anterior and then to the left of the ascending aorta, before bifurcating into the right and left pulmonary arteries posterior to the left second intercostal space.

## Notes

The ascending aorta arises from the aortic orifice at the base of the left ventricle, at the level of the lower edge of the third left costal cartilage, posterior to the left half of the sternum. The ascending aorta ascends, moving slightly forwards and to the right, before continuing as the arch of the aorta posterior to the second right costal cartilage.

The pulmonary trunk arises from the conus arteriosus of the right ventricle slightly anterior to the aortic orifice, posterior to the left third costal cartilage. The pulmonary trunk ascends, moving posteriorly and to the left, lying initially anterior and then to the left of the ascending aorta, before bifurcating into the right and left pulmonary arteries posterior to the left second intercostal space.

The pulmonary trunk and the ascending aorta are contained within the pericardial sac, lined by serous pericardium and within a common sheath.

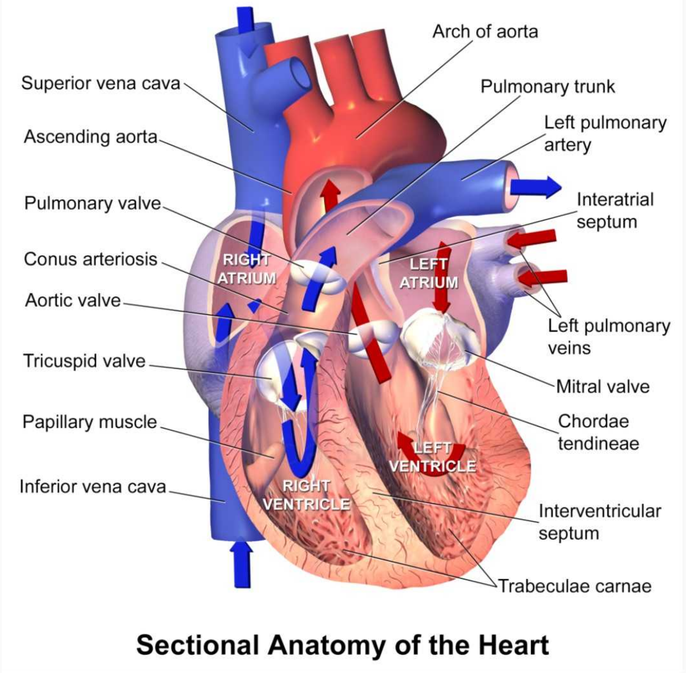


**Sectional Anatomy of the Heart**

By Blausen Medical Communications, Inc. [CC BY 3.0 (http://creativecommons.org/licenses/by/3.0)], via Wikimedia Commons

< Previous | Next > | Something wrong?

## Question Navigator

1 Answered
2 Answered
3 Answered
4 Answered
5 Answered
6 Answered
7 Answered
8 Answered
9 Answered
10 Answered
11 Answered
12 Answered



©2014 - 2017 FRCEM Success | Website designed & hosted by Cyberfrog Design

# Anatomy: Thorax

Question 20 of 134

## Posteriorly the inferior margin of the lung in quiet respiration is at which of the following vertebral levels:

a T8

b T9

c T10

d T11

e T12

< Previous | Next > | See Answer

Something wrong?

Question Navigator

1 Answered
2 Answered
3 Answered
4 Answered
5 Answered
6 Answered
7 Answered
8 Answered
9 Answered
10 Answered
11 Answered
12 Answered



©2014 - 2017 FRCEM Success | Website designed & hosted by Cyberfrog Design

# Anatomy: Thorax

Question 20 of 134

Posteriorly the inferior margin of the lung in quiet respiration is at which of the following vertebral levels:

**a)** T8
**b)** T9
**c)** **T10** ✔
**d)** T11
**e)** T12

## Answer

The inferior margin of the pleural cavity is a line that runs between rib 8 in the midclavicular line, rib 10 in the midaxillary line and vertebra T12 posteriorly. The inferior margin of the lung in quiet respiration is a line that runs between rib 6 in the midclavicular line, rib 8 in the midaxillary line and vertebra T10 posteriorly.

## Notes

Each lung is surrounded by a pleura. The pleura consists of two parts, the parietal pleura (which lines the thoracic cavity) and the visceral pleura (which lines the lungs). The two parts of the pleura are continuous with each other at the hilum of each lung. The potential space between these two parts of the pleura is called the pleural cavity.

**Pleural cavity**

The pleural cavity normally contains a small amount of lubricating fluid to allow the visceral pleura attached to the lungs to smoothly slide over the parietal pleura attached to the thoracic wall during respiration. The serous fluid also produces a surface tension, pulling the parietal and visceral pleura together. This ensures that when the thorax expands, the lung also expands, filling with air.

**Innervation**

The parietal pleura is innervated by somatic afferent fibres. The costal pleura (pleura related to the ribs and intercostal spaces) is innervated by branches of the intercostal nerves, and pain is felt in relation to the thoracic wall. The diaphragmatic pleura (covering the diaphragm) and the mediastinal pleura (covering the mediastinum) are innervated mainly by the phrenic nerves (C3 – C5), and pain is referred the the C3 – C5 dermatomes (lateral neck and supraclavicular region of shoulder).

Although the visceral pleura is innervated by visceral afferent fibres, pain is not generally elicited from this tissue.

**Surface markings**

Superiorly the pleural cavity projects as much as 3 – 4 cm above the first costal cartilage but does not extend above the neck of rib 1.

Anteriorly the pleurae approach each other posterior to the upper part of the sternum. At the lower part of the sternum the left pleura does not come as close to the midline as the right pleura because the middle mediastinum bulges to the left.

Inferiorly the pleura reflects onto the diaphragm above the costal margin. The inferior margin of the pleural cavity is a line that runs between rib 8 in the midclavicular line, rib 10 in the midaxillary line and vertebra T12 posteriorly.

The inferior margin of the lung in quiet respiration is a line that runs between rib 6 in the midclavicular line, rib 8 in the midaxillary line and vertebra T10 posteriorly.

The lungs therefore do not completely fill the pleural cavities, producing two pleural recesses, the costomediastinal and costodiaphragmatic recesses, in which fluids can collect.

The costomediastinal recess occurs on each side where the the costal pleura is opposed to mediastinal pleura, particularly on the left side in the region overlying the heart.

The costodiaphragmatic recess occurs between the costal and diaphragmatic pleura. It is the region between the inferior margin of the lung and the inferior margin of the pleural cavity and is clinically important for pleural aspiration.

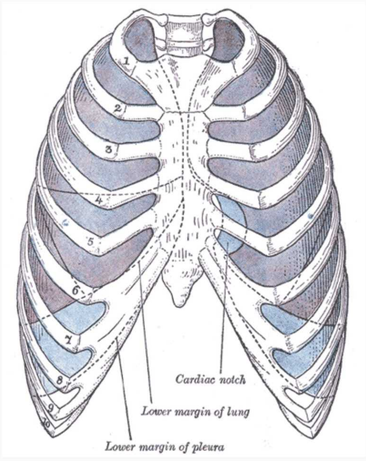


By Henry Vandyke Carter [Public domain], via Wikimedia Commons

< Previous | Next >

Something wrong?

## Question Navigator

1 Answered
2 Answered
3 Answered
4 Answered
5 Answered
6 Answered
7 Answered
8 Answered
9 Answered
10 Answered
11 Answered
12 Answered



©2014 - 2017 FRCEM Success | Website designed & hosted by Cyberfrog Design

# Anatomy: Thorax

Question 21 of 134

## Regarding the oesophagus, which of the following statements is CORRECT:

a The oesophagus begins at the inferior border of the cricoid cartilage and ends at the pyloric sphincter of the stomach.

b The oesophagus descends anterior to the trachea.

c The oesophagus descends on the anterior aspects of the bodies of the vertebrae.

d The left recurrent laryngeal nerve lies posterior to the oesophagus.

e The thoracic duct lies anterior to the oesophagus.

< Previous | Next > | See Answer

Something wrong?

Question Navigator

1 Answered
2 Answered
3 Answered
4 Answered
5 Answered
6 Answered
7 Answered
8 Answered
9 Answered
10 Answered
11 Answered
12 Answered



©2014 - 2017 FRCEM Success | Website designed & hosted by Cyberfrog Design

# Anatomy: Thorax

Question 21 of 134

Regarding the oesophagus, which of the following statements is CORRECT:

**a)**
The oesophagus begins at the inferior border of the cricoid cartilage and ends at the pyloric sphincter of the stomach.

**b)** The oesophagus descends anterior to the trachea.

**c)** **The oesophagus descends on the anterior aspects of the bodies of the vertebrae.** ✔

**d)** The left recurrent laryngeal nerve lies posterior to the oesophagus.

**e)** The thoracic duct lies anterior to the oesophagus.

## Answer

The oesophagus begins at the inferior border of the cricoid cartilage opposite vertebra C6, pierces the diaphragm at the esophageal hiatus at T10 and ends at the cardiac opening of the stomach opposite vertebra T11. The oesophagus descends on the anterior aspect of the bodies of the vertebrae, immediately posterior to the trachea and the recurrent laryngeal nerves, generally in the midline position. Posterior to the oesophagus, the thoracic duct is on the right side inferiorly but crosses to the left more superiorly (at T5).

## Notes

### Anatomical extent

The oesophagus is a muscular tube passing between the pharynx in the neck and the stomach in the abdomen. The oesophagus begins at the inferior border of the cricoid cartilage opposite vertebra C6, pierces the diaphragm at the esophageal hiatus at T10 and ends at the cardiac opening of the stomach opposite vertebra T11.

### Structure

The oesophagus consists of an internal circular and external longitudinal layer of muscle. The external longitudinal layer is comprised of different muscle types in each third of the oesophagus; superior third – voluntary striated muscle, middle third – voluntary striated and smooth muscle and inferior third – smooth muscle.

### Relations

The oesophagus descends on the anterior aspect of the bodies of the vertebrae, immediately posterior to the trachea and the recurrent laryngeal nerves, generally in the midline position. The oesophagus is crossed anteriorly by the aortic arch. As it approaches the diaphragm, the oesophagus moves anteriorly and to the left, crossing from the right side of the thoracic aorta to eventually assume a position anterior to it, before passing through the diaphragm.

Posterior to the oesophagus, the thoracic duct is on the right side inferiorly but crosses to the left more superiorly (at T5). Other structures posteriorly include portions of the hemiazygos veins and the right posterior intercostal vessels.

Anterior to the oesophagus below the tracheal bifurcation are the right pulmonary artery and the left main bronchus. The oesophagus then passes immediately posterior to the left atrium, separated from it only by pericardium. Inferior to the left atrium, the oesophagus is related to the diaphragm.

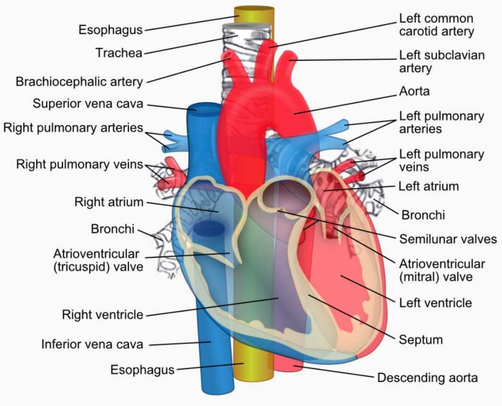


ZooFari [CC BY-SA 3.0 (http://creativecommons.org/licenses/by-sa/3.0)], via Wikimedia Commons

### Points of constriction

As the oesophagus is a flexible muscular tube, it is compressed by surrounding structures at four locations:

- 1) the junction of the oesophagus with the pharynx in the neck (upper oesophageal sphincter formed by the cricopharyngeus muscle)
- 2) in the superior mediastinum where the oesophagus is crossed by the arch of the aorta
- 3) in the posterior mediastinum where the oesophagus is compressed by the left main bronchus
- 4) in the posterior mediastinum at the oesophageal hiatus in the diaphragm.

Clinically these compressions are important when passing instruments or assessing swallowed objects.

### Innervation

Oesophageal innervation is complex, oesophageal branches arise from the vagus nerves and sympathetic trunks. The visceral afferents that pass through the sympathetic trunks and the splanchnic nerves are the primary participants in detection of oesophageal pain and transmission of this information to various levels of the central nervous system.

< Previous | Next >

Something wrong?

## Question Navigator

1 Answered
2 Answered
3 Answered
4 Answered
5 Answered
6 Answered
7 Answered
8 Answered
9 Answered
10 Answered
11 Answered
12 Answered



©2014 - 2017 FRCEM Success | Website designed & hosted by Cyberfrog Design

# Anatomy: Thorax

Question 22 of 134

## The trachea arises at the lower border of the cricoid cartilage in the neck at which vertebral level:

a C5

b C6

c C7

d T1

e T2

< Previous | Next > | See Answer

Something wrong?

Question Navigator

1 Answered
2 Answered
3 Answered
4 Answered
5 Answered
6 Answered
7 Answered
8 Answered
9 Answered
10 Answered
11 Answered
12 Answered



©2014 - 2017 FRCEM Success | Website designed & hosted by Cyberfrog Design

# Anatomy: Thorax

Question 22 of 134

The trachea arises at the lower border of the cricoid cartilage in the neck at which vertebral level:

**a)** C5
**b)** C6 ✔
**c)** C7
**d)** T1
**e)** T2

## Answer

The trachea arises as a continuation of the larynx at vertebral level C6.

## Notes

The trachea arises at the lower border of the cricoid cartilage in the neck, as a continuation of the larynx. It extends from vertebral level C6 to T4/T5 at which point it bifurcates into the right and left main bronchi (at the level of the sternal angle).

The trachea is formed anteriorly by 15 – 20 C-shaped rings of hyaline cartilage which mechanically hold the airway open whilst allowing it flexibility. The trachealis muscle connects the ends of the incomplete rings and forms the posterior wall of the trachea. The trachealis muscle is able to constrict the trachea, allowing air to be expelled with more force e.g. during coughing.

The trachea and bronchi are lined by ciliated pseudostratified columnar epithelium, interspersed by mucus-producing goblet cells. This mucous membrane functions as the mucociliary escalator, trapping particles in sticky mucus and sweeping it along the airway.

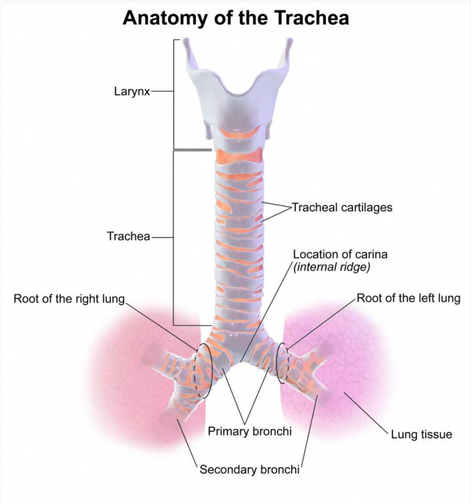


By Blausen.com staff. "Blausen gallery 2014". Wikiversity Journal of Medicine. DOI:10.15347/wjm/2014.010. ISSN 20018762. (Own work) [CC BY 3.0 (http://creativecommons.org/licenses/by/3.0)], via Wikimedia Commons

**Relations**

The trachea descends anterior to the oesophagus and inclines slightly to the right.

In the thorax, anteriorly it is related to:

- the thymic remnants
- the left brachiocephalic vein
- the aortic arch
- the brachiocephalic trunk
- the left common carotid artery
- the deep cardiac plexus.

Laterally it is related to:

- the pleura, the right vagus nerve and the brachiocephalic trunk on the right
- the left recurrent laryngeal nerve, the aortic arch and the left common carotid and subclavian vessels on the left.

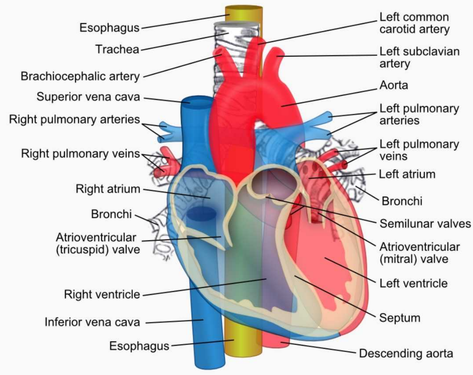


ZooFari [CC BY-SA 3.0 (http://creativecommons.org/licenses/by-sa/3.0)], via Wikimedia Commons

< Previous | Next >

Something wrong?

## Question Navigator

1 Answered
2 Answered
3 Answered
4 Answered
5 Answered
6 Answered
7 Answered
8 Answered
9 Answered
10 Answered
11 Answered
12 Answered



©2014 - 2017 FRCEM Success | Website designed & hosted by Cyberfrog Design

# Anatomy: Thorax

Question 23 of 134

## The superior border of the heart is formed predominantly by which of the following:

a Right atrium

b Left atrium

c Right ventricle

d Left ventricle

e Right and left atria

< Previous | Next > | See Answer

Something wrong?

Question Navigator

1 Answered
2 Answered
3 Answered
4 Answered
5 Answered
6 Answered
7 Answered
8 Answered
9 Answered
10 Answered
11 Answered
12 Answered



©2014 - 2017 FRCEM Success | Website designed & hosted by Cyberfrog Design

# Anatomy: Thorax

Question 23 of 134

The superior border of the heart is formed predominantly by which of the following:

a) **Right atrium** ✖
b) Left atrium
c) Right ventricle
d) Left ventricle
e) Right and left atria ✔

## Answer

The superior border is formed by both atria and the roots of the great vessels.

## Notes

| Border/Surface | Main structure (contributing structures) |
|---|---|
| Apex | Left ventricle |
| Base | Left atrium (right atrium, proximal great veins) |
| Anterior surface | Right ventricle (right atrium, left ventricle) |
| Inferior surface | Left and right ventricle |
| Left pulmonary surface | Left ventricle (left atrium) |
| Right pulmonary surface | Right atrium |
| Inferior border | Right ventricle (left ventricle) |
| Left border | Left ventricle (left auricle) |
| Right border | Right atrium |
| Superior border | Both atria, roots of great vessels |

The general shape and orientation of the heart are that of a pyramid that has fallen over and is resting on one of its sides.

- The apex of this pyramid projects forwards, downwards and to the left. The apex is formed by the inferolateral part of the left ventricle and is positioned deep to the left fifth intercostal space in the midclavicular line.
- The base is facing posteriorly. The base is formed mostly by the left atrium with a small portion of the right atrium and the proximal part of the great veins, and is fixed posteriorly to the pericardial wall, opposite the bodies of the T5 – T8 vertebrae (T6 – T9 when standing). The oesophagus lies immediately posterior to the base.

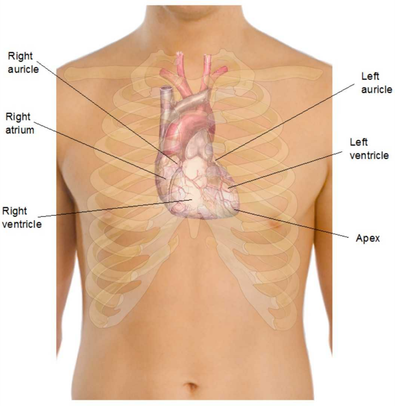


Modified by FRCEM Success. Original by Mikael Häggström (See above. All used images are in public domain.) [Public domain], via Wikimedia Commons

**Surfaces**

There are four surfaces to the upturned pyramid:

- The anterior (sternocostal) surface consists mostly of the right ventricle with some of the right atrium and some of the left ventricle.
- The inferior (diaphragmatic) surface consists of the left ventricle with a small portion of the right ventricle separated by the posterior interventricular groove.
- The left pulmonary surface consists mainly of the left ventricle and a portion of the left atrium.
- The right pulmonary surface consists of the right atrium.

**Borders**

There are four main borders separating the surfaces of the heart:

- The inferior border is formed mostly by the right ventricle and a small portion of the left ventricle near the apex.
- The left border is formed mostly by the left ventricle with a small portion of the left auricle.
- The right border is formed by the right atrium.
- The superior border is formed by both atria and the roots of the great vessels.

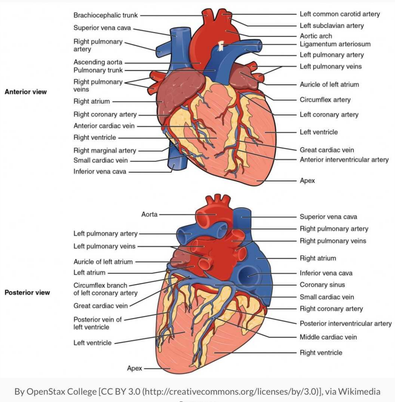


By OpenStax College [CC BY 3.0 (http://creativecommons.org/licenses/by/3.0)], via Wikimedia Commons

< Previous | Next >

Something wrong?

Question Navigator

1 Answered
2 Answered
3 Answered
4 Answered
5 Answered
6 Answered
7 Answered
8 Answered
9 Answered
10 Answered
11 Answered
12 Answered



©2014 - 2017 FRCEM Success | Website designed & hosted by Cyberfrog Design

# Anatomy: Thorax

Question 24 of 134

## The oesophageal opening in the diaphragm is found at which thoracic level:

a T8

b T9

c T10

d T11

e T12

< Previous | Next > | See Answer

Something wrong?

Question Navigator

1 Answered
2 Answered
3 Answered
4 Answered
5 Answered
6 Answered
7 Answered
8 Answered
9 Answered
10 Answered
11 Answered
12 Answered



©2014 - 2017 FRCEM Success | Website designed & hosted by Cyberfrog Design

# Anatomy: Thorax

Question 24 of 134

The oesophageal opening in the diaphragm is found at which thoracic level:

**a)** T8
**b)** T9
**c)** **T10** ✔
**d)** T11
**e)** T12

## Answer

The oesophageal opening in the diaphragm is a vertebral level T10 and transmits the oesophagus, the anterior and posterior vagal trunks, oesophageal branches of the left gastric vessels and a few lymphatics.

## Notes

The diaphragm is a musculotendinous structure that separates the thoracic cavity from the abdominal cavity.

| Structure | Diaphragm |
|---|---|
| Primary function | Respiration – contraction of diaphragm flattens diaphragm increasing vertical dimension of thorax (inspiration), relaxation of diaphragm elevates diaphragm decreasing vertical dimension of thorax (expiration) |
| Secondary functions | Assists in straining movements by increasing intra-abdominal pressure, acts as functional sphincter on oesophagus preventing acid reflux |
| Peripheral attachments | Xiphoid process of sternum, costal cartilages ribs 7 – 10, ends of ribs 11 and 12, arcuate ligaments and lumbar vertebrae |
| Central attachment | Fuses with fibrous pericardium superiorly |
| Surface markings | Attachments: vertebrae T8/T9 anteriorly, vertebra T12 posteriorly, Domes: right dome 5th rib, left dome 5th intercostal space |
| Openings | Oesophageal opening at T10 (oesophagus, vagus nerve), aortic opening at T12 (aorta, thoracic duct and azygos vein), caval opening at T8 (inferior vena cava and right phrenic nerve) |
| Innervation | Phrenic nerve (C3 – C5) |

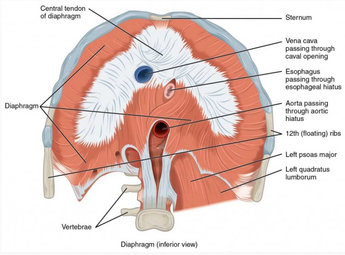


By OpenStax [CC BY 4.0 (http://creativecommons.org/licenses/by/4.0)], via Wikimedia Commons

### Function

The diaphragm performs an important function in respiration; contraction of the domes of the diaphragm in inspiration flattens the diaphragm, increasing the vertical dimension of the thorax and vice versa in expiration, with relaxation and elevation of the diaphragm reducing the vertical dimension of the thorax.

The diaphragm is also involved in non-respiratory functions; helping to expel vomit, faeces, and urine from the body by increasing intraabdominal pressure, and preventing acid reflux by exerting pressure on the oesophagus as it passes through the oesophageal opening.

### Attachments

The diaphragm is attached peripherally to:

- the xiphoid process of the sternum and the costal cartilages of ribs 7 – 10 (the costal margin) anteriorly
- the ends of ribs 11 and 12 laterally
- the arcuate ligaments and vertebrae posteriorly.

From these peripheral attachments, muscle fibres converge to form the central tendon which fuses with the fibrous pericardium superiorly.

### Surface markings

In the medial sagittal plane, the diaphragm slopes inferiorly from its anterior attachment to the xiphoid at approximately vertebral level T8/T9 to its posterior attachment to the median arcuate ligament at approximately vertebral level T12.

At rest the right dome of the diaphragm lies slightly higher than the left; this is thought to be due to the position of the liver. In normal expiration, the normal upper limits of the superior margins are the fifth rib for the right dome, the fifth intercostal space for the left dome and the xiphoid process for the central tendon.

### Diaphragmatic openings

Structures travelling between the thorax and abdomen must pass through the diaphragm via three main openings.

The oesophageal opening at vertebral level T10 transmits:

- the oesophagus
- the anterior and posterior vagal trunks
- oesophageal branches of the left gastric vessels
- a few lymphatics.

The aortic opening at vertebral level T12 transmits:

- the aorta
- the thoracic duct
- the azygos vein and sometimes the hemiazygos vein.

The caval opening at vertebral level T8 transmits:

- the inferior vena cava
- the right phrenic nerve.

### Innervation

The entire motor supply of the diaphragm is from the right and left phrenic nerves (C3 – C5) which penetrate the diaphragm and innervate it from its abdominal surface.

Damage to the phrenic nerve will result in hemiparalysis of the diaphragm. Paralysis of the diaphragm produces a paradoxical movement. The affected side of the diaphragm moves upwards during inspiration (as it is pushed superiorly by the abdominal viscera that are being actively compressed by the other half), and downwards during expiration.

A unilateral diaphragmatic paralysis is usually asymptomatic, and is most often an incidental finding on x-ray. If both sides are paralysed, the patient may experience poor exercise tolerance, orthopnoea and fatigue. Lung function tests will show a restrictive deficit.

### Diaphragmatic herniation

Diaphragmatic hernias are defined as congenital or acquired defects in the diaphragm. There are two main types of congenital diaphragmatic hernias; Bochdalek hernias and Morgagni hernias.

Acquired diaphragmatic hernias include traumatic diaphragmatic rupture, hiatus hernia and iatrogenic diaphragmatic hernias. Depending on the location and size of the defect, retroperitoneal or intra-abdominal organs and tissues can prolapse into the thoracic cavity due to the negative intrathoracic pressure.

Diaphragmatic rupture usually results from blunt abdominal trauma, which is typically associated with motor-vehicle accidents; the most commonly herniated viscera are the stomach and colon on the left side, and the liver on the right side.

In hiatus hernia, the stomach herniates through the oesophageal opening of the diaphragm, typically resulting in symptoms of acid reflux.

< Previous | Next >

Something wrong?

## Question Navigator

1 Answered
2 Answered
3 Answered
4 Answered
5 Answered
6 Answered
7 Answered
8 Answered
9 Answered
10 Answered
11 Answered
12 Answered



©2014 - 2017 FRCEM Success | Website designed & hosted by Cyberfrog Design

# Anatomy: Thorax

Question 25 of 134

## True ribs are defined by which of the following features:

a The head of the rib has two articular facets

b The tubercle of the rib articulates with the transverse process of the corresponding vertebrae

c Anteriorly, the rib attaches directly to the sternum

d Anteriorly, the rib attaches to the costal cartilage of the rib above it

e The inferior margin of the internal surface of the body is marked by a costal groove

< Previous | Next > | See Answer

Something wrong?

## Question Navigator

1 Answered
2 Answered
3 Answered
4 Answered
5 Answered
6 Answered
7 Answered
8 Answered
9 Answered
10 Answered
11 Answered
12 Answered



©2014 - 2017 FRCEM Success | Website designed & hosted by Cyberfrog Design

# Anatomy: Thorax

Question 25 of 134

True ribs are defined by which of the following features:

**a)** The head of the rib has two articular facets
**b)** The tubercle of the rib articulates with the transverse process of the corresponding vertebrae
**c)** **Anteriorly, the rib attaches directly to the sternum** ✔
**d)** Anteriorly, the rib attaches to the costal cartilage of the rib above it
**e)** The inferior margin of the internal surface of the body is marked by a costal groove

## Answer

The true ribs (1 – 7) are distinguished by their anterior attachment directly to the sternum.

## Notes

There are twelve pairs of ribs, each terminating anteriorly in a costal cartilage.

**True and False ribs**

The ribs are divided into 'true' and 'false' ribs based on their anterior attachments:

- The true ribs (1 – 7) attach directly to the sternum anteriorly.
- The false ribs (8 – 12) can be further divided into those that attach to the costal cartilage of the rib above them (8 – 10) and the floating ribs (11 + 12) that do not have any anterior attachments.

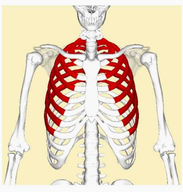

By Anatomography (en:Anatomography (setting page of this image)) [CC BY-SA 2.1 jp (http://creativecommons.org/licenses/by-sa/2.1/jp/deed.en)], via Wikimedia Commons

By Anatomography (en:Anatomography (setting page of this image)) [CC BY-SA 2.1 jp (http://creativecommons.org/licenses/by-sa/2.1/jp/deed.en)], via Wikimedia Commons

**Thoracic vertebrae**

Posteriorly, all of the ribs articulate with the thoracic vertebrae of the spine.

Each typical rib forms two joints posteriorly:

- the costotransverse joint (between the tubercle of the rib and the transverse process of the corresponding vertebra)
- the costovertebral joint (between the two facets on the head of the rib and the superior costal facet on the body of the corresponding vertebra, and the inferior costal facet on the body of the vertebra above).

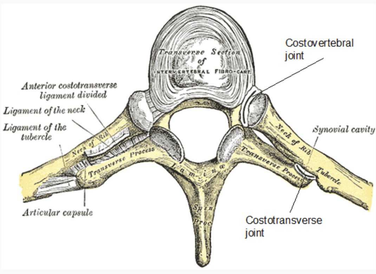


Modified by FRCEM Success. Original by Henry Vandyke Carter [Public domain], via Wikimedia Commons

**Typical ribs**

The typical rib consists of a head, a neck and a body:

- The head of the rib has two articular facets which articulate with the superior costal facet on the body of the corresponding vertebra, and the inferior costal facet on the body of the vertebra above.
- The neck of the rib connects the head to the body. Where the neck meets the body, there is a tubercle which articulates with the transverse process of the corresponding vertebra.
- The body of the rib is flat and curved.

The inferior margin of the internal surface of the body is marked by the costal groove which protects the neurovascular structures which run within it.

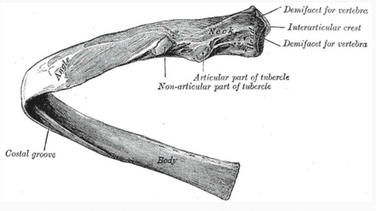


Modified by FRCEM Success. Original by Henry Vandyke Carter [Public domain], via Wikimedia Commons

**Atypical ribs**

The atypical ribs consist of ribs 1, 2, 10, 11 and 12.

| Atypical rib | Features |
|---|---|
| Rib 1 | Shorter and wider, single facet for articulation with T1, scalene tubercle |
| Rib 2 | Flat, roughened area for attachment of serratus anterior muscle |
| Rib 10 | Single facet for articulation with T10 |
| Rib 11 | No neck, single facet for articulation with T11 |
| Rib 12 | No neck, single facet for articulation with T12 |

- Rib 1 is shorter and wider than the other ribs. The head of rib 1 has only one facet for articulation with the body of its own vertebra (T1); it does NOT articulate with vertebra C7. The superior surface of rib 1 is characterised by the scalene tubercle about midway along the body, which separates two smooth grooves in the rib made by the subclavian vein anteriorly and the subclavian artery posteriorly.
- Like rib 1, rib 2 is flat but twice as long. It has a roughened area on its upper surface where the serratus anterior muscle attaches.
- The head of rib 10 only has a single facet for articulation with the body of its own vertebra (T10).
- Ribs 11 and 12 have no neck, and have only one facet for articulation with the bodies of their own vertebrae (T11 and T12).

< Previous | Next >

Something wrong?

## Question Navigator

1 Answered
2 Answered
3 Answered
4 Answered
5 Answered
6 Answered
7 Answered
8 Answered
9 Answered
10 Answered
11 Answered
12 Answered



©2014 - 2017 FRCEM Success | Website designed & hosted by Cyberfrog Design

# Anatomy: Thorax

Question 26 of 134

## Normal quiet expiration is achieved by contraction of which of the following structures:

a External intercostal muscles

b Internal and innermost intercostal muscles

c Diaphragm

d Elastic tissue in lungs and thoracic wall

e Serratus anterior muscles

< Previous | Next > | See Answer

Something wrong?

Question Navigator

1 Answered
2 Answered
3 Answered
4 Answered
5 Answered
6 Answered
7 Answered
8 Answered
9 Answered
10 Answered
11 Answered
12 Answered



©2014 - 2017 FRCEM Success | Website designed & hosted by Cyberfrog Design

# Anatomy: Thorax

Question 26 of 134

Normal quiet expiration is achieved by contraction of which of the following structures:

a) External intercostal muscles
b) Internal and innermost intercostal muscles
c) Diaphragm
d) **Elastic tissue in lungs and thoracic wall** ✔
e) Serratus anterior muscles

## Answer

Passive expiration is produced primarily by relaxation of the inspiratory muscles (diaphragm and external intercostal muscles) and the elastic recoil of the lungs.

## Notes

**Thoracic wall movements**

Movement of the ribs at the costovertebral joints in respiration results in the 'pump handle' and 'bucket handle' movements:

- Because the anterior ends of the ribs are inferior to the posterior ends, when the ribs are elevated, the anterior end moves upwards and forwards, moving the sternum upwards and forwards in turn. This 'pump handle' upwards and forwards movement changes the anteroposterior (AP) dimension of the thorax.
- Because the shafts of the ribs are lower than either the anterior or posterior end, elevation of the ribs also moves the shafts laterally. This 'bucket handle' upwards and lateral movement increases the lateral dimensions of the thorax.

Reversal of these movements i.e. depression of the ribs, will reduce the anteroposterior and transverse dimensions of the thorax.

**Inspiration**

In inspiration, elevation of the sternal ends of the ribs ('pump handle' movement), elevation of the lateral shafts of the ribs ('bucket handle' movement) and depression of the diaphragm result in expansion of the thorax in an anteroposterior, transverse and vertical direction respectively. This results in an increased intrathoracic volume and decreased intrathoracic pressure and thus air is drawn into the lungs.

Passive inspiration is produced by contraction of the diaphragm (depressing the diaphragm) and the external intercostal muscles (elevating the ribs).

The accessory respiratory muscles (including the sternocleidomastoid, the scalene muscles and the serratus anterior amongst others) aid in forceful inspiration.

**Expiration**

In expiration, depression of the ribs and elevation of the diaphragm result in a reduction of the thorax in an anteroposterior, transverse and vertical direction. This results in a decreased intrathoracic volume and increased intrathoracic pressure and thus air is forced out of the lungs.

Passive expiration is produced primarily by relaxation of the inspiratory muscles (diaphragm and external intercostal muscles) and the elastic recoil of the lungs.

Forceful expiration is primarily produced by the deeper thoracic muscles (internal and innermost intercostal muscles, subcostals and transversus thoracis) aided by contraction of the abdominal wall muscles which increase intra-abdominal pressure thus further reducing the volume of the thorax.

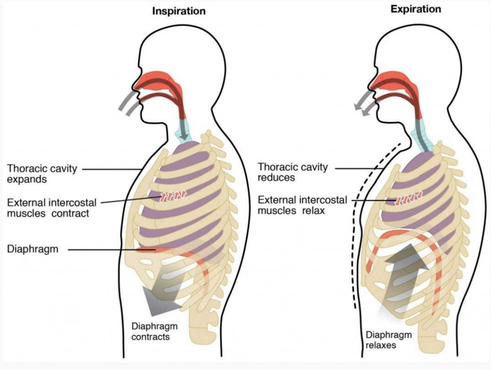


By OpenStax College [CC BY 3.0 (http://creativecommons.org/licenses/by/3.0)], via Wikimedia Commons

**Paradoxical respiration**

Normally as the diaphragm moves downwards in respiration, the abdominal wall moves outwards (together with the chest wall), and the reverse occurs in expiration.

In complete airway obstruction, the diaphragm will move down and the abdominal wall out but as inspiratory effort continues against a closed airway, increasing intrathoracic pressure will draw the chest wall paradoxically inwards (against the opposing action of the intercostal muscles). To the observer, in inspiration there is abdominal expansion with chest collapse and during expiration the reverse is seen. As inspiratory effort increases and expiration becomes active, the see-sawing pattern becomes more pronounced.

Flail chest is a loss of stability of the thoracic cage that occurs when a segment of the anterior or lateral thoracic wall moves freely because of multiple rib fractures, allowing the loose segment to move paradoxically inward on inspiration and outward on expiration. If a large enough segment of the chest is affected, ventilation is impaired.

< Previous | Next >

Something wrong?

## Question Navigator

1 Answered
2 Answered
3 Answered
4 Answered
5 Answered
6 Answered
7 Answered
8 Answered
9 Answered
10 Answered
11 Answered
12 Answered



©2014 - 2017 FRCEM Success | Website designed & hosted by Cyberfrog Design

# Anatomy: Thorax

Question 27 of 134

A 64 year old man presents to ED complaining of right sided chest pain that is worse on coughing. Which of the following nerves is most likely responsible for the sensation of pain:

a Phrenic nerve

b Vagus nerve

c Thoracic intercostal nerves

d Subcostal nerve

e Recurrent laryngeal nerve

< Previous | Next > | See Answer

Something wrong?

## Question Navigator

1 Answered
2 Answered
3 Answered
4 Answered
5 Answered
6 Answered
7 Answered
8 Answered
9 Answered
10 Answered
11 Answered
12 Answered



©2014 - 2017 FRCEM Success | Website designed & hosted by Cyberfrog Design

# Anatomy: Thorax

Question 27 of 134

A 64 year old man presents to ED complaining of right sided chest pain that is worse on coughing. Which of the following nerves is most likely responsible for the sensation of pain:

a) Phrenic nerve ✗
b) Vagus nerve
c) Thoracic intercostal nerves ✓
d) Subcostal nerve
e) Recurrent laryngeal nerve

## Answer

The parietal pleura is innervated by somatic afferent fibres. The costal pleura (pleura related to the ribs and intercostal spaces) is innervated by branches of the intercostal nerves, and pain is felt in relation to the thoracic wall. The diaphragmatic pleura (covering the diaphragm) and the mediastinal pleura (covering the mediastinum) are innervated mainly by the phrenic nerves (C3 – C5), and pain is referred the the C3 – C5 dermatomes (lateral neck and supraclavicular region of shoulder).

## Notes

Each lung is surrounded by a pleura. The pleura consists of two parts, the parietal pleura (which lines the thoracic cavity) and the visceral pleura (which lines the lungs). The two parts of the pleura are continuous with each other at the hilum of each lung. The potential space between these two parts of the pleura is called the pleural cavity.

**Pleural cavity**

The pleural cavity normally contains a small amount of lubricating fluid to allow the visceral pleura attached to the lungs to smoothly slide over the parietal pleura attached to the thoracic wall during respiration. The serous fluid also produces a surface tension, pulling the parietal and visceral pleura together. This ensures that when the thorax expands, the lung also expands, filling with air.

**Innervation**

The parietal pleura is innervated by somatic afferent fibres. The costal pleura (pleura related to the ribs and intercostal spaces) is innervated by branches of the intercostal nerves, and pain is felt in relation to the thoracic wall. The diaphragmatic pleura (covering the diaphragm) and the mediastinal pleura (covering the mediastinum) are innervated mainly by the phrenic nerves (C3 – C5), and pain is referred the the C3 – C5 dermatomes (lateral neck and supraclavicular region of shoulder).

Although the visceral pleura is innervated by visceral afferent fibres, pain is not generally elicited from this tissue.

**Surface markings**

Superiorly the pleural cavity projects as much as 3 – 4 cm above the first costal cartilage but does not extend above the neck of rib 1.

Anteriorly the pleurae approach each other posterior to the upper part of the sternum. At the lower part of the sternum the left pleura does not come as close to the midline as the right pleura because the middle mediastinum bulges to the left.

Inferiorly the pleura reflects onto the diaphragm above the costal margin. The inferior margin of the pleural cavity is a line that runs between rib 8 in the midclavicular line, rib 10 in the midaxillary line and vertebra T12 posteriorly.

The inferior margin of the lung in quiet respiration is a line that runs between rib 6 in the midclavicular line, rib 8 in the midaxillary line and vertebra T10 posteriorly.

The lungs therefore do not completely fill the pleural cavities, producing two pleural recesses, the costomediastinal and costodiaphragmatic recesses, in which fluids can collect.

The costomediastinal recess occurs on each side where the the costal pleura is opposed to mediastinal pleura, particularly on the left side in the region overlying the heart.

The costodiaphragmatic recess occurs between the costal and diaphragmatic pleura. It is the region between the inferior margin of the lung and the inferior margin of the pleural cavity and is clinically important for pleural aspiration.

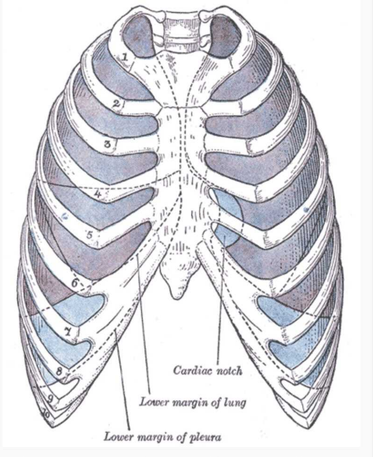


By Henry Vandyke Carter [Public domain], via Wikimedia Commons

< Previous | Next >

Something wrong?

## Question Navigator

1 Answered
2 Answered
3 Answered
4 Answered
5 Answered
6 Answered
7 Answered
8 Answered
9 Answered
10 Answered
11 Answered
12 Answered



©2014 - 2017 FRCEM Success | Website designed & hosted by Cyberfrog Design

# Anatomy: Thorax

Question 28 of 134

A 59 year old woman presents to ED complaining of sudden onset central crushing chest pain radiating down her left arm. ECG is suggestive of posterior myocardial infarction. Which of the following nerves is responsible for the radiating arm pain:

a Phrenic

b Long thoracic

c Intercostobrachial

d Vagus

e Cardiopulmonary

< Previous | Next > | See Answer

Something wrong?

## Question Navigator

1 Answered
2 Answered
3 Answered
4 Answered
5 Answered
6 Answered
7 Answered
8 Answered
9 Answered
10 Answered
11 Answered
12 Answered



©2014 - 2017 FRCEM Success | Website designed & hosted by Cyberfrog Design

# Anatomy: Thorax

Question 28 of 134

A 59 year old woman presents to ED complaining of sudden onset central crushing chest pain radiating down her left arm. ECG is suggestive of posterior myocardial infarction. Which of the following nerves is responsible for the radiating arm pain:

a) Phrenic
b) Long thoracic
c) Intercostobrachial ✔
d) **Vagus** ✘
e) Cardiopulmonary

## Answer

The intercostobrachial nerve is the lateral cutaneous branch of the second intercostal nerve. It supplies skin over the thoracic wall and the medial aspect of the arm and axilla.

## Notes

| Dermatome | Landmark |
|---|---|
| T1 | Medial antecubital fossa |
| T2 | Apex of axilla |
| T3 | Third intercostal space |
| T4 | Level of nipples (fourth intercostal space) |
| T5 | Fifth intercostal space |
| T6 | Level of xiphisternum |
| T7 | One-quarter distance between xiphisternum and umbilicus |
| T8 | One-half distance between xiphisternum and umbilicus |
| T9 | Three-quarter distance between xiphisternum and umbilicus |
| T10 | Level of umbilicus |
| T11 | Midway between umbilicus and inguinal ligament |
| T12 | Midpoint of inguinal ligament |

**Dermatome assessment**

- The T1 dermatome is best tested on the medial (ulnar) side of the antecubital fossa, just proximal to the medial epicondyle of the humerus.
- The T2 dermatome is best tested at the apex of the axilla.
- The T3 dermatome is best tested at the midclavicular line and the third intercostal space.
- The T4 dermatome is best tested at the midclavicular line and the fourth intercostal space, located at the level of the nipples.
- The T5 dermatome is best tested at the midclavicular line and the fifth intercostal space, located midway between the level of the nipples and the level of the xiphisternum.
- The T6 dermatome is best tested at the midclavicular line, located at the level of the xiphisternum.
- The T7 dermatome is best tested at the midclavicular line, one quarter the distance between the level of the xiphisternum and the level of the umbilicus.
- The T8 dermatome is best tested at the midclavicular line, one half the distance between the level of the xiphisternum and the level of the umbilicus.
- The T9 dermatome is best tested at the midclavicular line, three quarters of the distance between the level of the xiphisternum and the level of the umbilicus.
- The T10 dermatome is best tested at the midclavicular line, located at the level of the umbilicus.
- The T11 dermatome is best tested at the midclavicular line, midway between the level of the umbilicus and the inguinal ligament.
- The T12 dermatome is best tested at the midclavicular line, over the midpoint of the inguinal ligament.

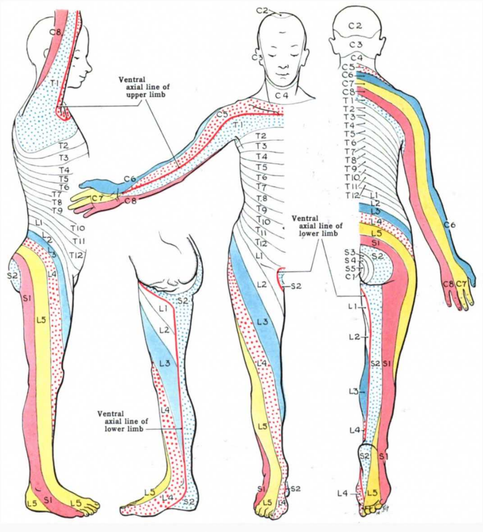


By Grant, John Charles Boileau (An atlas of anatomy, / by regions 1962) [Public domain], via Wikimedia Commons

< Previous | Next > | Something wrong?

## Question Navigator

1 Answered
2 Answered
3 Answered
4 Answered
5 Answered
6 Answered
7 Answered
8 Answered
9 Answered
10 Answered
11 Answered
12 Answered



©2014 - 2017 FRCEM Success | Website designed & hosted by Cyberfrog Design

# Anatomy: Thorax

Question 29 of 134

## The following structures all lie posterior to the oesophagus except for the:

a Thoracic vertebrae

b Thoracic duct

c Hemiazygos veins

d Right posterior intercostal vessels

e Right recurrent laryngeal nerve

< Previous | Next > | See Answer

Something wrong?

Question Navigator

1 Answered
2 Answered
3 Answered
4 Answered
5 Answered
6 Answered
7 Answered
8 Answered
9 Answered
10 Answered
11 Answered
12 Answered



©2014 - 2017 FRCEM Success | Website designed & hosted by Cyberfrog Design

# Anatomy: Thorax

Question 29 of 134

The following structures all lie posterior to the oesophagus except for the:

a) Thoracic vertebrae
b) Thoracic duct
c) Hemiazygos veins
d) Right posterior intercostal vessels
e) **Right recurrent laryngeal nerve** ✔

## Answer

The recurrent laryngeal nerves ascend in a groove between the trachea anteriorly and the oesophagus posteriorly.

## Notes

**Anatomical extent**

The oesophagus is a muscular tube passing between the pharynx in the neck and the stomach in the abdomen. The oesophagus begins at the inferior border of the cricoid cartilage opposite vertebra C6, pierces the diaphragm at the esophageal hiatus at T10 and ends at the cardiac opening of the stomach opposite vertebra T11.

**Structure**

The oesophagus consists of an internal circular and external longitudinal layer of muscle. The external longitudinal layer is comprised of different muscle types in each third of the oesophagus; superior third – voluntary striated muscle, middle third – voluntary striated and smooth muscle and inferior third – smooth muscle.

**Relations**

The oesophagus descends on the anterior aspect of the bodies of the vertebrae, immediately posterior to the trachea and the recurrent laryngeal nerves, generally in the midline position. The oesophagus is crossed anteriorly by the aortic arch. As it approaches the diaphragm, the oesophagus moves anteriorly and to the left, crossing from the right side of the thoracic aorta to eventually assume a position anterior to it, before passing through the diaphragm.

Posterior to the oesophagus, the thoracic duct is on the right side inferiorly but crosses to the left more superiorly (at T5). Other structures posteriorly include portions of the hemiazygos veins and the right posterior intercostal vessels.

Anterior to the oesophagus below the tracheal bifurcation are the right pulmonary artery and the left main bronchus. The oesophagus then passes immediately posterior to the left atrium, separated from it only by pericardium. Inferior to the left atrium, the oesophagus is related to the diaphragm.

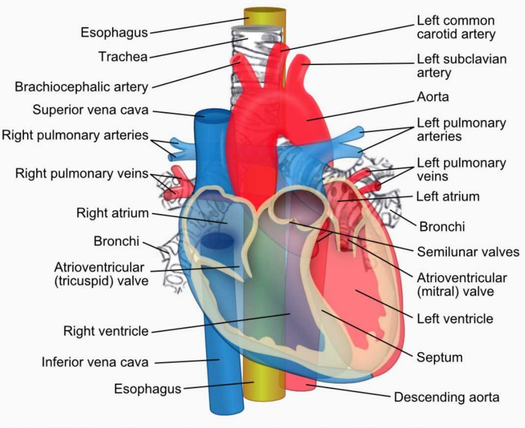


ZooFari [CC BY-SA 3.0 (http://creativecommons.org/licenses/by-sa/3.0)], via Wikimedia Commons

**Points of constriction**

As the oesophagus is a flexible muscular tube, it is compressed by surrounding structures at four locations:

- 1) the junction of the oesophagus with the pharynx in the neck (upper oesophageal sphincter formed by the cricopharyngeus muscle)
- 2) in the superior mediastinum where the oesophagus is crossed by the arch of the aorta
- 3) in the posterior mediastinum where the oesophagus is compressed by the left main bronchus
- 4) in the posterior mediastinum at the oesophageal hiatus in the diaphragm.

Clinically these compressions are important when passing instruments or assessing swallowed objects.

**Innervation**

Oesophageal innervation is complex, oesophageal branches arise from the vagus nerves and sympathetic trunks. The visceral afferents that pass through the sympathetic trunks and the splanchnic nerves are the primary participants in detection of oesophageal pain and transmission of this information to various levels of the central nervous system.

< Previous | Next >

Something wrong?

## Question Navigator

1 Answered
2 Answered
3 Answered
4 Answered
5 Answered
6 Answered
7 Answered
8 Answered
9 Answered
10 Answered
11 Answered
12 Answered



©2014 - 2017 FRCEM Success | Website designed & hosted by Cyberfrog Design

# Anatomy: Thorax

Question 30 of 134

## Regarding the lungs, which of the following statements is CORRECT:

a The bronchial tree and supporting lung tissues receive their nutrient blood supply from the pulmonary artery.

b Each lung has two pulmonary veins that carry oxygenated blood back to the heart.

c Lymph from the lungs drains to axillary nodes.

d The visceral afferent fibres of the lungs travel with the sympathetic trunk.

e Parasympathetic innervation causes relaxation of bronchial smooth muscle.

< Previous | Next > | See Answer

Something wrong?

### Question Navigator

1 Answered
2 Answered
3 Answered
4 Answered
5 Answered
6 Answered
7 Answered
8 Answered
9 Answered
10 Answered
11 Answered
12 Answered



©2014 - 2017 FRCEM Success | Website designed & hosted by Cyberfrog Design

# Anatomy: Thorax

Question 30 of 134

Regarding the lungs, which of the following statements is CORRECT:

**a)**
The bronchial tree and supporting lung tissues receive their nutrient blood supply from the pulmonary artery.

**b)** ✔
**Each lung has two pulmonary veins that carry oxygenated blood back to the heart.**

**c)** Lymph from the lungs drains to axillary nodes.

**d)** The visceral afferent fibres of the lungs travel with the sympathetic trunk.

**e)** Parasympathetic innervation causes relaxation of bronchial smooth muscle.

## Answer

The pulmonary arteries carry deoxygenated blood to the lungs while the pulmonary veins carry oxygenated blood from the lungs back to the heart. The bronchial tree, lung roots and supporting lung tissues receive their nutrient blood supply from the bronchial arteries. Lymph from the lungs drains via hilar, tracheobronchial and mediastinal lymph nodes. Parasympathetic fibres are carried in the vagus nerve which also carries visceral afferent fibres. Parasympathetic supply causes bronchial smooth muscle contraction.

## Notes

The lungs lie on either side of the mediastinum, each surrounded by a pleural cavity. They are suspended from the mediastinum by the root of the lung, a short tubular collection of structures.

**Lung root**

The root is lined by a layer of mediastinal pleura that reflects onto the surface of the lungs as visceral pleura. The region outlined by this pleural reflection on the medial surface of the lung is the hilum, where structures enter and leave.

The hila are located at the level of the 3rd – 4th costal cartilage anteriorly, and the T5 – T7 vertebrae posteriorly.

Each lung root contains:

- a pulmonary artery
- two pulmonary veins
- a main bronchus
- bronchial vessels,
- nerves and
- lymphatics.

Generally the pulmonary artery is superior in the lung root, the pulmonary veins are inferior and the bronchi are somewhat posterior in position.

In the mediastinum, the vagus nerves pass immediately posteriorly to the lung roots, while the phrenic nerves pass immediately anterior to them.

On the right side, the lobar bronchus to the superior lobe branches from the main bronchus in the root, whereas on the left, it branches within the lung itself.

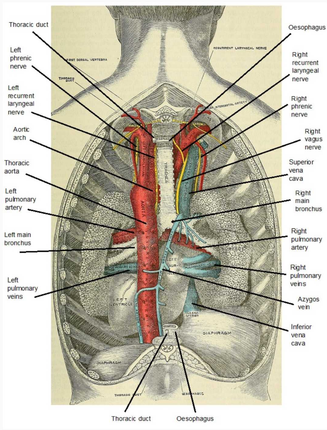


Modified by FRCEM Success. Original by Gray, Henry, 1825-1861; Carter, H. V. (Henry Vandyke), 1831-1897; Pick, T. Pickering (Thomas Pickering), 1841-1919 [No restrictions], via Wikimedia Commons

**Relations**

The medial surface of the right lung lies adjacent to:

- the heart
- the inferior vena cava
- the superior vena cava
- the azygos vein
- the oesophagus

The medial surface of the left lung lies adjacent to:

- the heart
- the aortic arch
- the thoracic aorta
- the oesophagus.

The right and left subclavian arteries and veins arch over and are related to the superior lobe of the right and left lung as they pass over the dome of the cervical pleura and into the axilla.

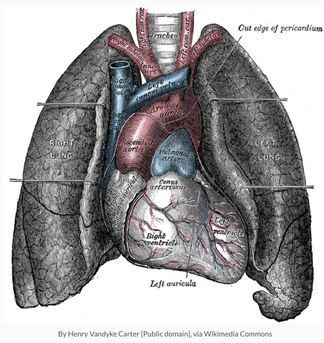


By Henry Vandyke Carter [Public domain], via Wikimedia Commons

**Blood supply**

The right and left pulmonary arteries originate from the pulmonary trunk (at the vertebral level T4/T5) and carry deoxygenated blood to the lungs.

On each side a superior and inferior pulmonary vein carries oxygenated blood from the lungs back to the heart.

The bronchi (down to the terminal bronchioles), lung roots, visceral pleura and supporting lung tissues receive their nutrient blood supply from the bronchial arteries, which arise from the descending aorta.

**Lymphatics**

Lymph from the lungs drains via hilar, tracheobronchial and mediastinal lymph nodes.

**Innervation**

The nerve supply to the lungs is from the anterior and posterior pulmonary plexus (networks of nerves derived from the sympathetic trunk and vagus nerve).

The parasympathetic nerve supply, carried by the vagus nerve, stimulates secretion from the bronchial glands, contraction of bronchial smooth muscle, and vasodilation of the pulmonary vessels. The vagus nerve also carries afferent fibres of pain, cough reflex and stretch of the lung (during inspiration).

The sympathetic nerve supply stimulates relaxation of bronchial smooth muscle, and vasoconstriction of the pulmonary vessels.

Question Navigator

1 Answered
2 Answered
3 Answered
4 Answered
5 Answered
6 Answered
7 Answered
8 Answered
9 Answered
10 Answered
11 Answered
12 Answered

< Previous | Next >

Something wrong?



©2014 - 2017 FRCEM Success | Website designed & hosted by Cyberfrog Design

# Anatomy: Thorax

Question 31 of 134

## Regarding the ribs, which of the following statements is INCORRECT:

a The floating ribs have no anterior attachments.

b Posteriorly, all of the ribs articulate with the thoracic vertebrae.

c The costal groove is found on the superior margin of the internal surface of the body of the rib.

d The typical rib consists of a head, a neck and a body.

e The tubercle of the rib is located where the neck meets the body.

< Previous | Next > | See Answer

Something wrong?

Question Navigator

1 Answered
2 Answered
3 Answered
4 Answered
5 Answered
6 Answered
7 Answered
8 Answered
9 Answered
10 Answered
11 Answered
12 Answered



©2014 - 2017 FRCEM Success | Website designed & hosted by Cyberfrog Design

# Anatomy: Thorax

Question 31 of 134

Regarding the ribs, which of the following statements is INCORRECT:

**a)** The floating ribs have no anterior attachments.
**b)** Posteriorly, all of the ribs articulate with the thoracic vertebrae.
**c)** ✔
**The costal groove is found on the superior margin of the internal surface of the body of the rib.**
**d)** The typical rib consists of a head, a neck and a body.
**e)** The tubercle of the rib is located where the neck meets the body.

## Answer

The inferior margin of the internal surface of the body of the rib is marked by the costal groove which protects the intercostal neurovascular structures which run within it.

## Notes

There are twelve pairs of ribs, each terminating anteriorly in a costal cartilage.

**True and False ribs**

The ribs are divided into 'true' and 'false' ribs based on their anterior attachments:

- The true ribs (1 – 7) attach directly to the sternum anteriorly.
- The false ribs (8 – 12) can be further divided into those that attach to the costal cartilage of the rib above them (8 – 10) and the floating ribs (11 + 12) that do not have any anterior attachments.

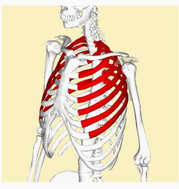

By Anatomography (en:Anatomography (setting page of this image)) [CC BY-SA 2.1 jp (http://creativecommons.org/licenses/by-sa/2.1/jp/deed.en)], via Wikimedia Commons

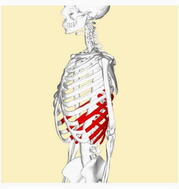

By Anatomography (en:Anatomography (setting page of this image)) [CC BY-SA 2.1 jp (http://creativecommons.org/licenses/by-sa/2.1/jp/deed.en)], via Wikimedia Commons

**Thoracic vertebrae**

Posteriorly, all of the ribs articulate with the thoracic vertebrae of the spine.

Each typical rib forms two joints posteriorly:

- the costotransverse joint (between the tubercle of the rib and the transverse process of the corresponding vertebra)
- the costovertebral joint (between the two facets on the head of the rib and the superior costal facet on the body of the corresponding vertebra, and the inferior costal facet on the body of the vertebra above).

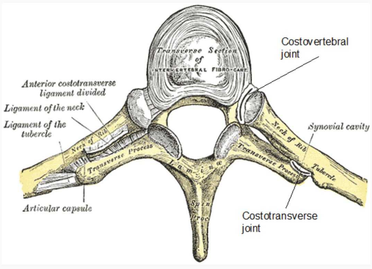


Modified by FRCEM Success. Original by Henry Vandyke Carter [Public domain], via Wikimedia Commons

**Typical ribs**

The typical rib consists of a head, a neck and a body:

- The head of the rib has two articular facets which articulate with the superior costal facet on the body of the corresponding vertebra, and the inferior costal facet on the body of the vertebra above.
- The neck of the rib connects the head to the body. Where the neck meets the body, there is a tubercle which articulates with the transverse process of the corresponding vertebra.
- The body of the rib is flat and curved.

The inferior margin of the internal surface of the body is marked by the costal groove which protects the neurovascular structures which run within it.

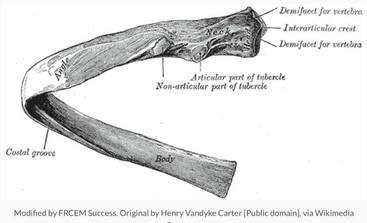


Modified by FRCEM Success. Original by Henry Vandyke Carter [Public domain], via Wikimedia Commons

**Atypical ribs**

The atypical ribs consist of ribs 1, 2, 10, 11 and 12.

| Atypical rib | Features |
|---|---|
| Rib 1 | Shorter and wider, single facet for articulation with T1, scalene tubercle |
| Rib 2 | Flat, roughened area for attachment of serratus anterior muscle |
| Rib 10 | Single facet for articulation with T10 |
| Rib 11 | No neck, single facet for articulation with T11 |
| Rib 12 | No neck, single facet for articulation with T12 |

- Rib 1 is shorter and wider than the other ribs. The head of rib 1 has only one facet for articulation with the body of its own vertebra (T1); it does NOT articulate with vertebra C7. The superior surface of rib 1 is characterised by the scalene tubercle about midway along the body, which separates two smooth grooves in the rib made by the subclavian vein anteriorly and the subclavian artery posteriorly.
- Like rib 1, rib 2 is flat but twice as long. It has a roughened area on its upper surface where the serratus anterior muscle attaches.
- The head of rib 10 only has a single facet for articulation with the body of its own vertebra (T10).
- Ribs 11 and 12 have no neck, and have only one facet for articulation with the bodies of their own vertebrae (T11 and T12).

< Previous | Next >

Something wrong?

## Question Navigator

1 Answered
2 Answered
3 Answered
4 Answered
5 Answered
6 Answered
7 Answered
8 Answered
9 Answered
10 Answered
11 Answered
12 Answered



©2014 - 2017 FRCEM Success | Website designed & hosted by Cyberfrog Design

# Anatomy: Thorax

Question 32 of 134

## The 'bucket handle' movement of the thoracic wall results from which of the following movements:

a The anterior ends of the ribs moving upwards and forwards

b The sternum moving upwards and forwards

c The shafts of the ribs moving upwards and laterally

d The posterior ends of the ribs moving upwards and backwards

e The clavicle moving upwards

< Previous | Next > | See Answer

Something wrong?

Question Navigator

1 Answered
2 Answered
3 Answered
4 Answered
5 Answered
6 Answered
7 Answered
8 Answered
9 Answered
10 Answered
11 Answered
12 Answered



©2014 - 2017 FRCEM Success | Website designed & hosted by Cyberfrog Design

# Anatomy: Thorax

Question 32 of 134

The 'bucket handle' movement of the thoracic wall results from which of the following movements:

**a)** The anterior ends of the ribs moving upwards and forwards
**b)** The sternum moving upwards and forwards
**c)** **The shafts of the ribs moving upwards and laterally** ✔
**d)** The posterior ends of the ribs moving upwards and backwards
**e)** The clavicle moving upwards

## Answer

Because the shafts of the ribs are lower than either the anterior or posterior end, elevation of the ribs also moves the shafts laterally. This 'bucket handle' upwards and lateral movement increases the lateral dimensions of the thorax.

## Notes

**Thoracic wall movements**

Movement of the ribs at the costovertebral joints in respiration results in the 'pump handle' and 'bucket handle' movements:

- Because the anterior ends of the ribs are inferior to the posterior ends, when the ribs are elevated, the anterior end moves upwards and forwards, moving the sternum upwards and forwards in turn. This 'pump handle' upwards and forwards movement changes the anteroposterior (AP) dimension of the thorax.
- Because the shafts of the ribs are lower than either the anterior or posterior end, elevation of the ribs also moves the shafts laterally. This 'bucket handle' upwards and lateral movement increases the lateral dimensions of the thorax.

Reversal of these movements i.e. depression of the ribs, will reduce the anteroposterior and transverse dimensions of the thorax.

**Inspiration**

In inspiration, elevation of the sternal ends of the ribs ('pump handle' movement), elevation of the lateral shafts of the ribs ('bucket handle' movement) and depression of the diaphragm result in expansion of the thorax in an anteroposterior, transverse and vertical direction respectively. This results in an increased intrathoracic volume and decreased intrathoracic pressure and thus air is drawn into the lungs.

Passive inspiration is produced by contraction of the diaphragm (depressing the diaphragm) and the external intercostal muscles (elevating the ribs).

The accessory respiratory muscles (including the sternocleidomastoid, the scalene muscles and the serratus anterior amongst others) aid in forceful inspiration.

**Expiration**

In expiration, depression of the ribs and elevation of the diaphragm result in a reduction of the thorax in an anteroposterior, transverse and vertical direction. This results in a decreased intrathoracic volume and increased intrathoracic pressure and thus air is forced out of the lungs.

Passive expiration is produced primarily by relaxation of the inspiratory muscles (diaphragm and external intercostal muscles) and the elastic recoil of the lungs.

Forceful expiration is primarily produced by the deeper thoracic muscles (internal and innermost intercostal muscles, subcostals and transversus thoracis) aided by contraction of the abdominal wall muscles which increase intra-abdominal pressure thus further reducing the volume of the thorax.

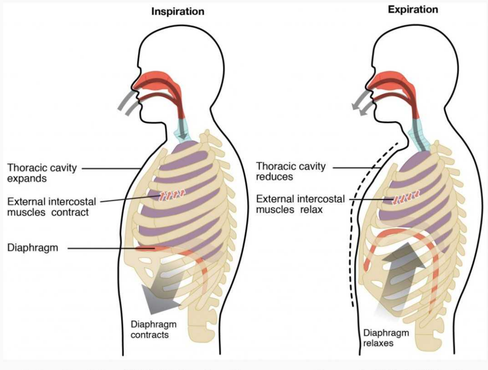


By OpenStax College [CC BY 3.0 (http://creativecommons.org/licenses/by/3.0)], via Wikimedia Commons

**Paradoxical respiration**

Normally as the diaphragm moves downwards in respiration, the abdominal wall moves outwards (together with the chest wall), and the reverse occurs in expiration.

In complete airway obstruction, the diaphragm will move down and the abdominal wall out but as inspiratory effort continues against a closed airway, increasing intrathoracic pressure will draw the chest wall paradoxically inwards (against the opposing action of the intercostal muscles). To the observer, in inspiration there is abdominal expansion with chest collapse and during expiration the reverse is seen. As inspiratory effort increases and expiration becomes active, the see-sawing pattern becomes more pronounced.

Flail chest is a loss of stability of the thoracic cage that occurs when a segment of the anterior or lateral thoracic wall moves freely because of multiple rib fractures, allowing the loose segment to move paradoxically inward on inspiration and outward on expiration. If a large enough segment of the chest is affected, ventilation is impaired.

< Previous | Next >

Something wrong?

## Question Navigator

1 Answered
2 Answered
3 Answered
4 Answered
5 Answered
6 Answered
7 Answered
8 Answered
9 Answered
10 Answered
11 Answered
12 Answered



©2014 - 2017 FRCEM Success | Website designed & hosted by Cyberfrog Design

# Anatomy: Thorax

Question 33 of 134

## Regarding the thoracic inlet, which of the following statements is CORRECT:

a The thoracic inlet is bordered posteriorly by the body of vertebra C7.

b At the thoracic inlet, the recurrent laryngeal nerve lies posterior to the trachea.

c At the thoracic inlet, the thoracic duct lies to the right of the oesophagus.

d At the thoracic inlet, the oesophagus lies anterior to the trachea.

e The thoracic inlet is bordered anteriorly by the xiphisternum.

< Previous | Next > | See Answer

Something wrong?

Question Navigator

1 Answered
2 Answered
3 Answered
4 Answered
5 Answered
6 Answered
7 Answered
8 Answered
9 Answered
10 Answered
11 Answered
12 Answered



©2014 - 2017 FRCEM Success | Website designed & hosted by Cyberfrog Design

# Anatomy: Thorax

Question 33 of 134

Regarding the thoracic inlet, which of the following statements is CORRECT:

a) The thoracic inlet is bordered posteriorly by the body of vertebra C7.
b) At the thoracic inlet, the recurrent laryngeal nerve lies posterior to the trachea.
c) **At the thoracic inlet, the thoracic duct lies to the right of the oesophagus.**
d) At the thoracic inlet, the oesophagus lies anterior to the trachea.
e) The thoracic inlet is bordered anteriorly by the xiphisternum.

## Answer

The recurrent laryngeal nerve ascends through the thoracic inlet in the tracheo-oesophageal sulcus between the trachea anteriorly and the oesophagus posteriorly.

## Notes

The thoracic inlet is bordered anteriorly by the manubrium of the sternum and the first costal cartilages, laterally by the first ribs and posteriorly by the body of vertebra T1.

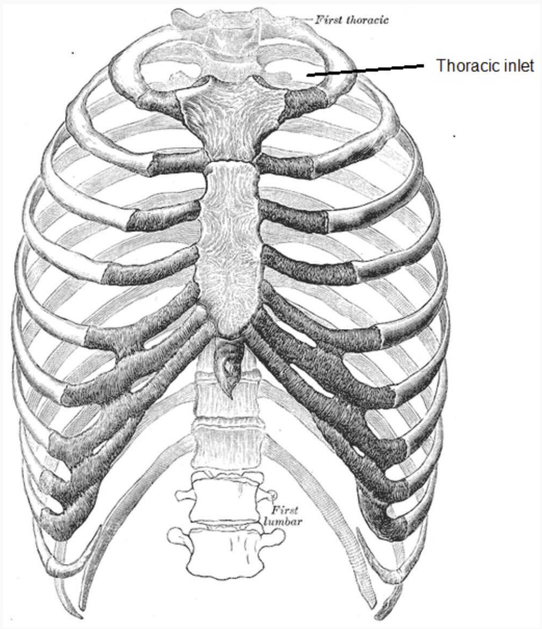


Modified by FRCEM Success. Original by Henry Vandyke Carter [Public domain], via Wikimedia Commons

At the thoracic inlet, the superior aspects of the pleural cavities lie on either side of the entrance to the mediastinum, extending approximately 2 – 3 cm above rib I and the costal cartilage into the neck.

The thoracic inlet is traversed in the median plane by (from anterior to posterior):

- the sternohyoid muscle
- the sternothyroid muscle
- the thymic remnants
- the inferior thyroid veins
- the trachea
- the recurrent laryngeal nerves (in the tracheo-oesophageal sulcus)
- the oesophagus
- the thoracic duct (displaced slightly to the left)
- the longus colli muscles
- the anterior longitudinal ligament.

To the left, it is traversed by (from anterior to posterior):

- the left brachiocephalic vein
- the left vagus and left phrenic nerves
- the left common carotid artery and the left subclavian artery.

To the right, it is traversed by (from anterior to posterior):

- the right brachiocephalic vein
- the right vagus and right phrenic nerves
- the brachiocephalic trunk.

< Previous | Next >

Something wrong?

## Question Navigator

1 Answered
2 Answered
3 Answered
4 Answered
5 Answered
6 Answered
7 Answered
8 Answered
9 Answered
10 Answered
11 Answered
12 Answered



©2014 - 2017 FRCEM Success | Website designed & hosted by Cyberfrog Design

# Anatomy: Thorax

Question 34 of 134

## Which of the following ribs are classed as 'false ribs':

a Ribs 1 – 3

b Ribs 4 – 8

c Ribs 11 – 12

d Ribs 5 – 10

e Ribs 8 – 12

< Previous | Next > | See Answer

Something wrong?

Question Navigator

1 Answered
2 Answered
3 Answered
4 Answered
5 Answered
6 Answered
7 Answered
8 Answered
9 Answered
10 Answered
11 Answered
12 Answered



©2014 - 2017 FRCEM Success | Website designed & hosted by Cyberfrog Design

# Anatomy: Thorax

Question 34 of 134

Which of the following ribs are classed as 'false ribs':

**a)** Ribs 1 – 3
**b)** Ribs 4 – 8
**c)** Ribs 11 – 12
**d)** Ribs 5 – 10
**e)** **Ribs 8 – 12** ✔

## Answer

Ribs 8 – 12 are classed as false ribs because they don't attach directly to the sternum. The false ribs (8 – 12) can be further divided into those that attach to the costal cartilage of the rib above them (8 – 10) and the floating ribs (11 + 12) that do not have any anterior attachments.

## Notes

There are twelve pairs of ribs, each terminating anteriorly in a costal cartilage.

**True and False ribs**

The ribs are divided into 'true' and 'false' ribs based on their anterior attachments:

- The true ribs (1 – 7) attach directly to the sternum anteriorly.
- The false ribs (8 – 12) can be further divided into those that attach to the costal cartilage of the rib above them (8 – 10) and the floating ribs (11 + 12) that do not have any anterior attachments.

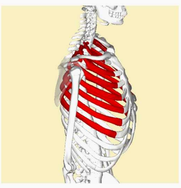

By Anatomography (en:Anatomography (setting page of this image)) [CC BY-SA 2.1 jp (http://creativecommons.org/licenses/by-sa/2.1/jp/deed.en)], via Wikimedia Commons

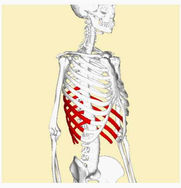

By Anatomography (en:Anatomography (setting page of this image)) [CC BY-SA 2.1 jp (http://creativecommons.org/licenses/by-sa/2.1/jp/deed.en)], via Wikimedia Commons

**Thoracic vertebrae**

Posteriorly, all of the ribs articulate with the thoracic vertebrae of the spine.

Each typical rib forms two joints posteriorly:

- the costotransverse joint (between the tubercle of the rib and the transverse process of the corresponding vertebra)
- the costovertebral joint (between the two facets on the head of the rib and the superior costal facet on the body of the corresponding vertebra, and the inferior costal facet on the body of the vertebra above).

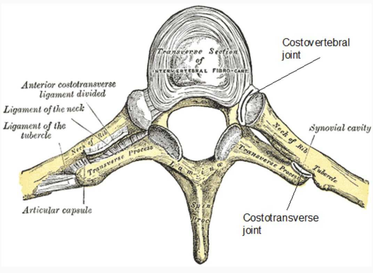


Modified by FRCEM Success. Original by Henry Vandyke Carter [Public domain], via Wikimedia Commons

**Typical ribs**

The typical rib consists of a head, a neck and a body:

- The head of the rib has two articular facets which articulate with the superior costal facet on the body of the corresponding vertebra, and the inferior costal facet on the body of the vertebra above.
- The neck of the rib connects the head to the body. Where the neck meets the body, there is a tubercle which articulates with the transverse process of the corresponding vertebra.
- The body of the rib is flat and curved.

The inferior margin of the internal surface of the body is marked by the costal groove which protects the neurovascular structures which run within it.

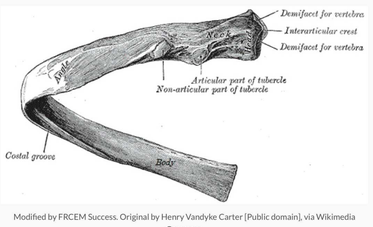


Modified by FRCEM Success. Original by Henry Vandyke Carter [Public domain], via Wikimedia Commons

**Atypical ribs**

The atypical ribs consist of ribs 1, 2, 10, 11 and 12.

| Atypical rib | Features |
|---|---|
| Rib 1 | Shorter and wider, single facet for articulation with T1, scalene tubercle |
| Rib 2 | Flat, roughened area for attachment of serratus anterior muscle |
| Rib 10 | Single facet for articulation with T10 |
| Rib 11 | No neck, single facet for articulation with T11 |
| Rib 12 | No neck, single facet for articulation with T12 |

- Rib 1 is shorter and wider than the other ribs. The head of rib 1 has only one facet for articulation with the body of its own vertebra (T1); it does NOT articulate with vertebra C7. The superior surface of rib 1 is characterised by the scalene tubercle about midway along the body, which separates two smooth grooves in the rib made by the subclavian vein anteriorly and the subclavian artery posteriorly.
- Like rib 1, rib 2 is flat but twice as long. It has a roughened area on its upper surface where the serratus anterior muscle attaches.
- The head of rib 10 only has a single facet for articulation with the body of its own vertebra (T10).
- Ribs 11 and 12 have no neck, and have only one facet for articulation with the bodies of their own vertebrae (T11 and T12).

< Previous | Next >

Something wrong?

## Question Navigator

1 Answered
2 Answered
3 Answered
4 Answered
5 Answered
6 Answered
7 Answered
8 Answered
9 Answered
10 Answered
11 Answered
12 Answered



©2014 - 2017 FRCEM Success | Website designed & hosted by Cyberfrog Design

# Anatomy: Thorax

Question 35 of 134

## The left pulmonary surface of the heart is formed predominantly by which of the following:

a Right atrium

b Left atrium

c Right ventricle

d Left ventricle

e Great vessels

< Previous | Next > | See Answer

Something wrong?

## Question Navigator

1 Answered
2 Answered
3 Answered
4 Answered
5 Answered
6 Answered
7 Answered
8 Answered
9 Answered
10 Answered
11 Answered
12 Answered



©2014 - 2017 FRCEM Success | Website designed & hosted by Cyberfrog Design

# Anatomy: Thorax

Question 35 of 134

The left pulmonary surface of the heart is formed predominantly by which of the following:

**a)** Right atrium
**b)** Left atrium
**c)** Right ventricle
**d)** **Left ventricle** ✔
**e)** Great vessels

## Answer

The left pulmonary surface consists mainly of the left ventricle and a portion of the left atrium.

## Notes

| Border/Surface | Main structure (contributing structures) |
|---|---|
| Apex | Left ventricle |
| Base | Left atrium (right atrium, proximal great veins) |
| Anterior surface | Right ventricle (right atrium, left ventricle) |
| Inferior surface | Left and right ventricle |
| Left pulmonary surface | Left ventricle (left atrium) |
| Right pulmonary surface | Right atrium |
| Inferior border | Right ventricle (left ventricle) |
| Left border | Left ventricle (left auricle) |
| Right border | Right atrium |
| Superior border | Both atria, roots of great vessels |

The general shape and orientation of the heart are that of a pyramid that has fallen over and is resting on one of its sides.

- The apex of this pyramid projects forwards, downwards and to the left. The apex is formed by the inferolateral part of the left ventricle and is positioned deep to the left fifth intercostal space in the midclavicular line.
- The base is facing posteriorly. The base is formed mostly by the left atrium with a small portion of the right atrium and the proximal part of the great veins, and is fixed posteriorly to the pericardial wall, opposite the bodies of the T5 – T8 vertebrae (T6 – T9 when standing). The oesophagus lies immediately posterior to the base.

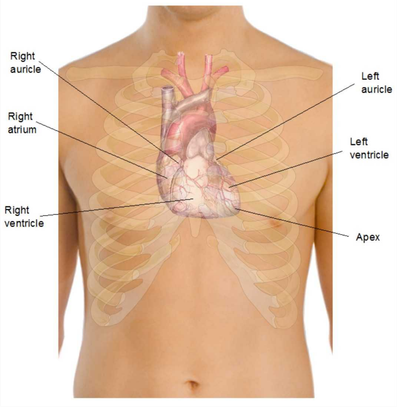


Modified by FRCEM Success. Original by Mikael Häggström (See above. All used images are in public domain.) [Public domain], via Wikimedia Commons

**Surfaces**

There are four surfaces to the upturned pyramid:

- The anterior (sternocostal) surface consists mostly of the right ventricle with some of the right atrium and some of the left ventricle.
- The inferior (diaphragmatic) surface consists of the left ventricle with a small portion of the right ventricle separated by the posterior interventricular groove.
- The left pulmonary surface consists mainly of the left ventricle and a portion of the left atrium.
- The right pulmonary surface consists of the right atrium.

**Borders**

There are four main borders separating the surfaces of the heart:

- The inferior border is formed mostly by the right ventricle and a small portion of the left ventricle near the apex.
- The left border is formed mostly by the left ventricle with a small portion of the left auricle.
- The right border is formed by the right atrium.
- The superior border is formed by both atria and the roots of the great vessels.

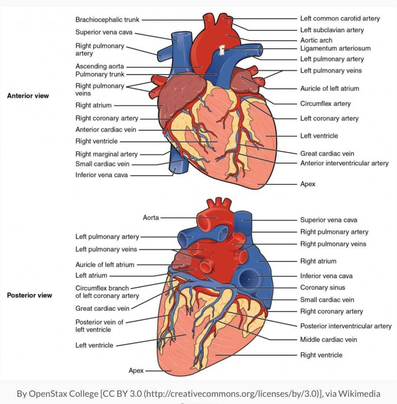


By OpenStax College [CC BY 3.0 (http://creativecommons.org/licenses/by/3.0)], via Wikimedia Commons

< Previous | Next >

Something wrong?

## Question Navigator

1 Answered
2 Answered
3 Answered
4 Answered
5 Answered
6 Answered
7 Answered
8 Answered
9 Answered
10 Answered
11 Answered
12 Answered



©2014 - 2017 FRCEM Success | Website designed & hosted by Cyberfrog Design

# Anatomy: Thorax

Question 36 of 134

## The T6 dermatome is best tested at which of the following landmarks:

a At the level of the nipples

b In the fifth intercostal space

c In the sixth intercostal space

d At the level of the xiphisternum

e At a point midway between the level of the nipples and the level of the xiphisternum

< Previous | Next > | See Answer

Something wrong?

## Question Navigator

1 Answered
2 Answered
3 Answered
4 Answered
5 Answered
6 Answered
7 Answered
8 Answered
9 Answered
10 Answered
11 Answered
12 Answered



©2014 - 2017 FRCEM Success | Website designed & hosted by Cyberfrog Design

# Anatomy: Thorax

Question 36 of 134

The T6 dermatome is best tested at which of the following landmarks:

a) At the level of the nipples
b) In the fifth intercostal space
c) In the sixth intercostal space
d) At the level of the xiphisternum ✔
e) ✖

**At a point midway between the level of the nipples and the level of the xiphisternum**

## Answer

The T6 dermatome is best tested at the midclavicular line, located at the level of the xiphisternum.

## Notes

| Dermatome | Landmark |
|---|---|
| T1 | Medial antecubital fossa |
| T2 | Apex of axilla |
| T3 | Third intercostal space |
| T4 | Level of nipples (fourth intercostal space) |
| T5 | Fifth intercostal space |
| T6 | Level of xiphisternum |
| T7 | One-quarter distance between xiphisternum and umbilicus |
| T8 | One-half distance between xiphisternum and umbilicus |
| T9 | Three-quarter distance between xiphisternum and umbilicus |
| T10 | Level of umbilicus |
| T11 | Midway between umbilicus and inguinal ligament |
| T12 | Midpoint of inguinal ligament |

Dermatome assessment

- The T1 dermatome is best tested on the medial (ulnar) side of the antecubital fossa, just proximal to the medial epicondyle of the humerus.
- The T2 dermatome is best tested at the apex of the axilla.
- The T3 dermatome is best tested at the midclavicular line and the third intercostal space.
- The T4 dermatome is best tested at the midclavicular line and the fourth intercostal space, located at the level of the nipples.
- The T5 dermatome is best tested at the midclavicular line and the fifth intercostal space, located midway between the level of the nipples and the level of the xiphisternum.
- The T6 dermatome is best tested at the midclavicular line, located at the level of the xiphisternum.
- The T7 dermatome is best tested at the midclavicular line, one quarter the distance between the level of the xiphisternum and the level of the umbilicus.
- The T8 dermatome is best tested at the midclavicular line, one half the distance between the level of the xiphisternum and the level of the umbilicus.
- The T9 dermatome is best tested at the midclavicular line, three quarters of the distance between the level of the xiphisternum and the level of the umbilicus.
- The T10 dermatome is best tested at the midclavicular line, located at the level of the umbilicus.
- The T11 dermatome is best tested at the midclavicular line, midway between the level of the umbilicus and the inguinal ligament.
- The T12 dermatome is best tested at the midclavicular line, over the midpoint of the inguinal ligament.

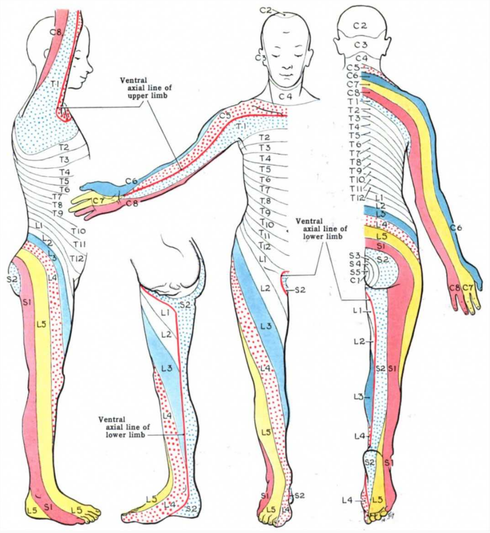


By Grant, John Charles Boileau (An atlas of anatomy. / by regions 1962) [Public domain], via Wikimedia Commons

< Previous | Next >

Something wrong?

## Question Navigator

1 Answered
2 Answered
3 Answered
4 Answered
5 Answered
6 Answered
7 Answered
8 Answered
9 Answered
10 Answered
11 Answered
12 Answered



©2014 - 2017 FRCEM Success | Website designed & hosted by Cyberfrog Design

# Anatomy: Thorax

Question 37 of 134

## The arch of the aorta continues from the ascending aorta posterior to which of the following:

a First right costal cartilage

b Second right costal cartilage

c Third right costal cartilage

d Second left costal cartilage

e Third left costal cartilage

< Previous | Next > | See Answer

Something wrong?

Question Navigator

1 Answered
2 Answered
3 Answered
4 Answered
5 Answered
6 Answered
7 Answered
8 Answered
9 Answered
10 Answered
11 Answered
12 Answered



©2014 - 2017 FRCEM Success | Website designed & hosted by Cyberfrog Design

# Anatomy: Thorax

Question 37 of 134

The arch of the aorta continues from the ascending aorta posterior to which of the following:

a) First right costal cartilage
b) Second right costal cartilage ✔
c) Third right costal cartilage
d) **Second left costal cartilage** ✖
e) Third left costal cartilage

## Answer

The ascending aorta ascends, moving slightly forwards and to the right, before continuing as the arch of the aorta posterior to the second right costal cartilage.

## Notes

The ascending aorta arises from the aortic orifice at the base of the left ventricle, at the level of the lower edge of the third left costal cartilage, posterior to the left half of the sternum. The ascending aorta ascends, moving slightly forwards and to the right, before continuing as the arch of the aorta posterior to the second right costal cartilage.

The pulmonary trunk arises from the conus arteriosus of the right ventricle slightly anterior to the aortic orifice, posterior to the left third costal cartilage. The pulmonary trunk ascends, moving posteriorly and to the left, lying initially anterior and then to the left of the ascending aorta, before bifurcating into the right and left pulmonary arteries posterior to the left second intercostal space.

The pulmonary trunk and the ascending aorta are contained within the pericardial sac, lined by serous pericardium and within a common sheath.

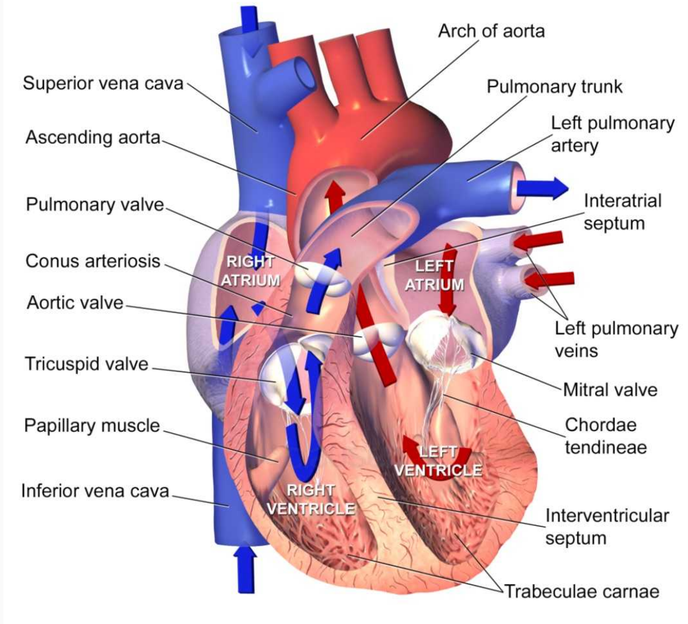


**Sectional Anatomy of the Heart**

By Blausen Medical Communications, Inc. [CC BY 3.0 (http://creativecommons.org/licenses/by/3.0)], via Wikimedia Commons

< Previous | Next >

Something wrong?

## Question Navigator

1 Answered
2 Answered
3 Answered
4 Answered
5 Answered
6 Answered
7 Answered
8 Answered
9 Answered
10 Answered
11 Answered
12 Answered



©2014 - 2017 FRCEM Success | Website designed & hosted by Cyberfrog Design

# Anatomy: Thorax

Question 38 of 134

## Which of the following does not typically occur at the thoracic plane:

a The trachea bifurcates into the right and left main bronchi

b The pulmonary trunk bifurcates into the right and left pulmonary arteries

c The thoracic duct crosses the oesophagus posteriorly from right to left

d The azygos vein drains into the superior vena cava

e The brachiocephalic trunk bifurcates into the right common carotid and right subclavian artery

< Previous | Next > | See Answer

Something wrong?

Question Navigator

1 Answered
2 Answered
3 Answered
4 Answered
5 Answered
6 Answered
7 Answered
8 Answered
9 Answered
10 Answered
11 Answered
12 Answered



©2014 - 2017 FRCEM Success | Website designed & hosted by Cyberfrog Design

# Anatomy: Thorax

Question 38 of 134

## Which of the following does not typically occur at the thoracic plane:

a The trachea bifurcates into the right and left main bronchi

b The pulmonary trunk bifurcates into the right and left pulmonary arteries

c The thoracic duct crosses the oesophagus posteriorly from right to left

d The azygos vein drains into the superior vena cava

e The brachiocephalic trunk bifurcates into the right common carotid and right subclavian artery

< Previous | Next > | See Answer

Something wrong?

## Question Navigator

1 Answered
2 Answered
3 Answered
4 Answered
5 Answered
6 Answered
7 Answered
8 Answered
9 Answered
10 Answered
11 Answered
12 Answered



©2014 - 2017 FRCEM Success | Website designed & hosted by Cyberfrog Design

# Anatomy: Thorax

Question 38 of 134

Which of the following does not typically occur at the thoracic plane:

a) The trachea bifurcates into the right and left main bronchi
b) The pulmonary trunk bifurcates into the right and left pulmonary arteries
c) The thoracic duct crosses the oesophagus posteriorly from right to left
d) The azygos vein drains into the superior vena cava
e)

**The brachiocephalic trunk bifurcates into the right common carotid and right subclavian artery**

## Answer

The brachiocephalic trunk trunk bifurcates into the right common carotid and right subclavian artery at the level of the sternoclavicular joint.

## Notes

The transverse thoracic plane lies at the level of the sternal angle (at the level of the second intercostal cartilages) and the intervertebral disc between T4 and T5.

A number of important structures are transected by the transverse thoracic plane.

At the level of the transverse thoracic plane:

- the ascending aorta ends and the aortic arch begins
- the aortic arch ends and the descending aorta begins
- the superior mediastinum becomes the inferior mediastinum
- the trachea bifurcates into the right and left main bronchi
- the pulmonary trunk bifurcates into the right and left pulmonary arteries
- the azygos vein ends by draining into the superior vena cava
- the thoracic duct crosses the oesophagus posteriorly (from right to left).

< Previous | Next >

Something wrong?

Question Navigator

1 Answered
2 Answered
3 Answered
4 Answered
5 Answered
6 Answered
7 Answered
8 Answered
9 Answered
10 Answered
11 Answered
12 Answered



©2014 - 2017 FRCEM Success | Website designed & hosted by Cyberfrog Design

# Anatomy: Thorax

Question 39 of 134

## The inferior surface of the heart is formed predominantly by which of the following:

a Right atrium

b Left atrium and left ventricle

c Right atrium and right ventricle

d Left and right ventricles

e Great vessels

< Previous | Next > | See Answer

Something wrong?

## Question Navigator

1 Answered
2 Answered
3 Answered
4 Answered
5 Answered
6 Answered
7 Answered
8 Answered
9 Answered
10 Answered
11 Answered
12 Answered



©2014 - 2017 FRCEM Success | Website designed & hosted by Cyberfrog Design

# Anatomy: Thorax

Question 39 of 134

The inferior surface of the heart is formed predominantly by which of the following:

**a)** Right atrium
**b)** Left atrium and left ventricle
**c)** Right atrium and right ventricle
**d)** **Left and right ventricles** ✔
**e)** Great vessels

## Answer

The inferior (diaphragmatic) surface consists of the left ventricle with a small portion of the right ventricle separated by the posterior interventricular groove.

## Notes

| Border/Surface | Main structure (contributing structures) |
|---|---|
| Apex | Left ventricle |
| Base | Left atrium (right atrium, proximal great veins) |
| Anterior surface | Right ventricle (right atrium, left ventricle) |
| Inferior surface | Left and right ventricle |
| Left pulmonary surface | Left ventricle (left atrium) |
| Right pulmonary surface | Right atrium |
| Inferior border | Right ventricle (left ventricle) |
| Left border | Left ventricle (left auricle) |
| Right border | Right atrium |
| Superior border | Both atria, roots of great vessels |

The general shape and orientation of the heart are that of a pyramid that has fallen over and is resting on one of its sides.

- The apex of this pyramid projects forwards, downwards and to the left. The apex is formed by the inferolateral part of the left ventricle and is positioned deep to the left fifth intercostal space in the midclavicular line.
- The base is facing posteriorly. The base is formed mostly by the left atrium with a small portion of the right atrium and the proximal part of the great veins, and is fixed posteriorly to the pericardial wall, opposite the bodies of the T5 – T8 vertebrae (T6 – T9 when standing). The oesophagus lies immediately posterior to the base.

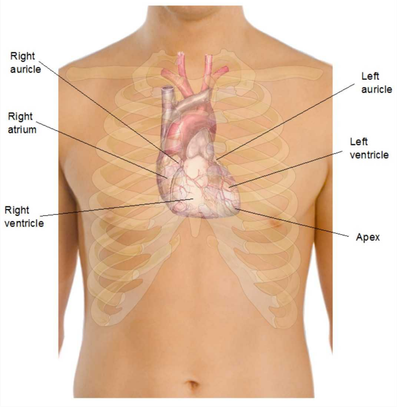


Modified by FRCEM Success. Original by Mikael Häggström (See above. All used images are in public domain.) [Public domain], via Wikimedia Commons

**Surfaces**

There are four surfaces to the upturned pyramid:

- The anterior (sternocostal) surface consists mostly of the right ventricle with some of the right atrium and some of the left ventricle.
- The inferior (diaphragmatic) surface consists of the left ventricle with a small portion of the right ventricle separated by the posterior interventricular groove.
- The left pulmonary surface consists mainly of the left ventricle and a portion of the left atrium.
- The right pulmonary surface consists of the right atrium.

**Borders**

There are four main borders separating the surfaces of the heart:

- The inferior border is formed mostly by the right ventricle and a small portion of the left ventricle near the apex.
- The left border is formed mostly by the left ventricle with a small portion of the left auricle.
- The right border is formed by the right atrium.
- The superior border is formed by both atria and the roots of the great vessels.

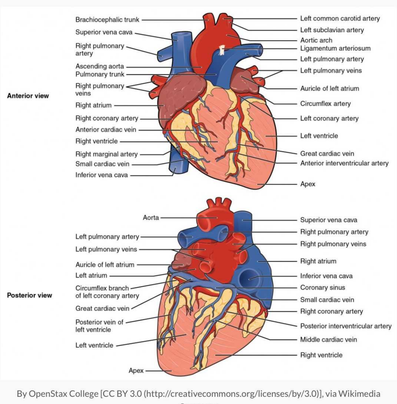


By OpenStax College [CC BY 3.0 (http://creativecommons.org/licenses/by/3.0)], via Wikimedia Commons

< Previous | Next >

Something wrong?

## Question Navigator

1 Answered
2 Answered
3 Answered
4 Answered
5 Answered
6 Answered
7 Answered
8 Answered
9 Answered
10 Answered
11 Answered
12 Answered



©2014 - 2017 FRCEM Success | Website designed & hosted by Cyberfrog Design

# Anatomy: Thorax

Question 40 of 134

## Regarding the pericardium, which of the following statements is CORRECT:

a The serous pericardium is a tough, inelastic sheath which fixes the heart in position.

b The fibrous pericardium is attached to the central tendon of the diaphragm.

c The fibrous and serous pericardium are separated by the pericardial cavity.

d Pain from the pericardium is classically referred to the back.

e The pericardium is found in the superior mediastinum.

< Previous | Next > | See Answer

Something wrong?

Question Navigator

1 Answered
2 Answered
3 Answered
4 Answered
5 Answered
6 Answered
7 Answered
8 Answered
9 Answered
10 Answered
11 Answered
12 Answered



©2014 - 2017 FRCEM Success | Website designed & hosted by Cyberfrog Design

# Anatomy: Thorax

Question 40 of 134

Regarding the pericardium, which of the following statements is CORRECT:

**a)** The serous pericardium is a tough, inelastic sheath which fixes the heart in position.
**b)** **The fibrous pericardium is attached to the central tendon of the diaphragm.** ✔
**c)** The fibrous and serous pericardium are separated by the pericardial cavity.
**d)** Pain from the pericardium is classically referred to the back.
**e)** The pericardium is found in the superior mediastinum.

## Answer

The fibrous pericardium is attached to the central diaphragm, the sternum and the tunica adventitia of the great vessels and acts to fix the heart in place and to prevent distension of the heart.

## Notes

The pericardium is a fibroserous sac surrounding the heart and the roots of the great vessels in the middle mediastinum. It is composed of two main layers; the fibrous pericardium and the serous pericardium.

**Serous pericardium**

The serous pericardium itself is divided into two parts which are continuous at the roots of the great vessels; the parietal layer which lines the inner surface of the fibrous pericardium and the visceral layer which lines the heart itself.

The parietal and visceral layer of serous pericardium are separated by the pericardial cavity which normally contains a small amount of lubricating serous fluid which reduces friction during normal movement of the heart.

**Fibrous pericardium**

The fibrous pericardium is a tough, inelastic sheath which fixes the heart in position (through its attachments to the central tendon of the diaphragm, the sternum and the tunica adventitia of the great vessels) and prevents sudden overfilling and distension of the heart.

Cardiac tamponade is acute compression of the heart caused by rapid accumulation of fluid or blood in the pericardial cavity from trauma (to the heart, great vessels or pericardial vessels) or pericardial effusion. The inflexibility of the fibrous pericardium results in increased intrapericardial pressure, with subsequent compression of venous return and reduced cardiac output.

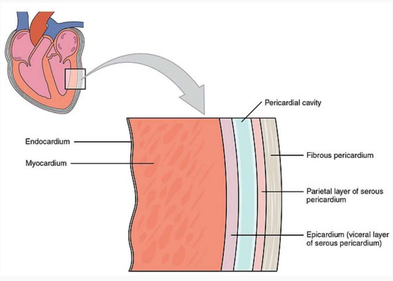


By OpenStax College [CC BY 3.0 (http://creativecommons.org/licenses/by/3.0)], via Wikimedia Commons

**Innervation**

The pericardium receives its nerve supply from the vagus nerve, the sympathetic trunks and the phrenic nerves.

Somatic sensation from the parietal pericardium is carried by somatic afferent fibres in the phrenic nerves (C3 – C5); it is for this reason that pain related to a pericardial problem may be referred to the supraclavicular region of the shoulder or the lateral neck area dermatomes for spinal cord segments C3 – C5.

**Pericardial aspiration (pericardiocentesis)**

Pericardiocentesis is a surgical puncture of the pericardial cavity for the aspiration of fluid, which is necessary to relieve the pressure of accumulated fluid in the heart.

A needle is inserted into the pericardial cavity 1 – 2 cm inferior to the left of the xiphochondral junction (between the xiphisternum and the left costal margin) at a 45 degree angle and advanced aiming toward the tip of the left scapula (site marked by cross in image below).

Complications of pericardiocentesis include:

- Aspiration of ventricular blood instead of pericardial blood
- Laceration of ventricular epicardium or myocardium
- Laceration of coronary artery or vein
- Ventricular fibrillation
- Pneumothorax secondary to lung puncture
- Puncture of great vessels with worsening pericardial tamponade
- Mediastinitis secondary to oesophageal puncture

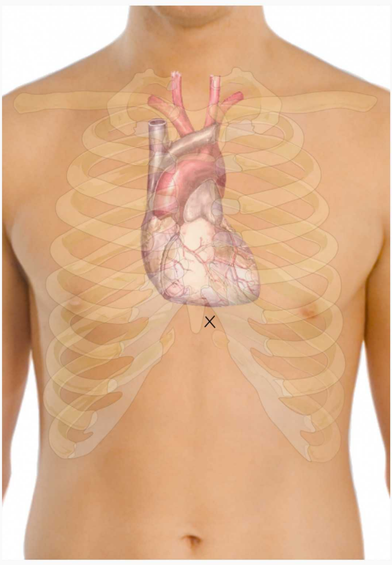

Modified by FRCEM Success. Original by Mikael Häggström (See above. All used images are in public domain.) [Public domain], via Wikimedia Commons

< Previous | Next >

Something wrong?

## Question Navigator

1 Answered
2 Answered
3 Answered
4 Answered
5 Answered
6 Answered
7 Answered
8 Answered
9 Answered
10 Answered
11 Answered
12 Answered



©2014 - 2017 FRCEM Success | Website designed & hosted by Cyberfrog Design

# Anatomy: Thorax

Question 41 of 134

## Which of the following actions does not typically occur as part of normal passive expiration:

a Depression of the sternal ends of the ribs

b Elevation of the diaphragm

c Contraction of the internal intercostal muscles

d Relaxation of the external intercostal muscles

e Depression of the lateral shaft of the ribs

< Previous | Next > | See Answer

Something wrong?

Question Navigator

1 Answered
2 Answered
3 Answered
4 Answered
5 Answered
6 Answered
7 Answered
8 Answered
9 Answered
10 Answered
11 Answered
12 Answered



©2014 - 2017 FRCEM Success | Website designed & hosted by Cyberfrog Design

# Anatomy: Thorax

Question 41 of 134

Which of the following actions does not typically occur as part of normal passive expiration:

**a)** Depression of the sternal ends of the ribs
**b)** Elevation of the diaphragm
**c)** **Contraction of the internal intercostal muscles** ✔
**d)** Relaxation of the external intercostal muscles
**e)** Depression of the lateral shaft of the ribs

## Answer

Passive expiration is produced primarily by relaxation of the inspiratory muscles (diaphragm and external intercostal muscles) and the elastic recoil of the lungs. In expiration, depression of the sternal ends of the ribs ('pump handle' movement), depression of the lateral shafts of the ribs ('bucket handle' movement) and elevation of the diaphragm result in a reduction of the thorax in an anteroposterior, transverse and vertical direction respectively. This results in a decreased intrathoracic volume and increased intrathoracic pressure and thus air is forced out of the lungs.

## Notes

**Thoracic wall movements**

Movement of the ribs at the costovertebral joints in respiration results in the 'pump handle' and 'bucket handle' movements:

- Because the anterior ends of the ribs are inferior to the posterior ends, when the ribs are elevated, the anterior end moves upwards and forwards, moving the sternum upwards and forwards in turn. This 'pump handle' upwards and forwards movement changes the anteroposterior (AP) dimension of the thorax.
- Because the shafts of the ribs are lower than either the anterior or posterior end, elevation of the ribs also moves the shafts laterally. This 'bucket handle' upwards and lateral movement increases the lateral dimensions of the thorax.

Reversal of these movements i.e. depression of the ribs, will reduce the anteroposterior and transverse dimensions of the thorax.

**Inspiration**

In inspiration, elevation of the sternal ends of the ribs ('pump handle' movement), elevation of the lateral shafts of the ribs ('bucket handle' movement) and depression of the diaphragm result in expansion of the thorax in an anteroposterior, transverse and vertical direction respectively. This results in an increased intrathoracic volume and decreased intrathoracic pressure and thus air is drawn into the lungs.

Passive inspiration is produced by contraction of the diaphragm (depressing the diaphragm) and the external intercostal muscles (elevating the ribs).

The accessory respiratory muscles (including the sternocleidomastoid, the scalene muscles and the serratus anterior amongst others) aid in forceful inspiration.

**Expiration**

In expiration, depression of the ribs and elevation of the diaphragm result in a reduction of the thorax in an anteroposterior, transverse and vertical direction. This results in a decreased intrathoracic volume and increased intrathoracic pressure and thus air is forced out of the lungs.

Passive expiration is produced primarily by relaxation of the inspiratory muscles (diaphragm and external intercostal muscles) and the elastic recoil of the lungs.

Forceful expiration is primarily produced by the deeper thoracic muscles (internal and innermost intercostal muscles, subcostals and transversus thoracis) aided by contraction of the abdominal wall muscles which increase intra-abdominal pressure thus further reducing the volume of the thorax.

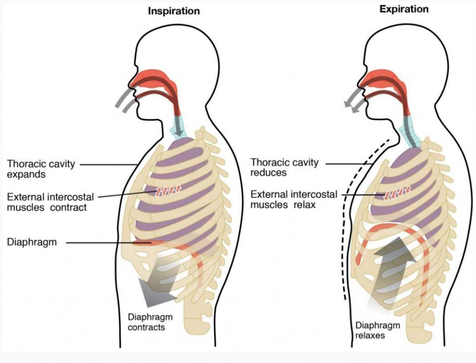


By OpenStax College [CC BY 3.0 (http://creativecommons.org/licenses/by/3.0)], via Wikimedia Commons

**Paradoxical respiration**

Normally as the diaphragm moves downwards in respiration, the abdominal wall moves outwards (together with the chest wall), and the reverse occurs in expiration.

In complete airway obstruction, the diaphragm will move down and the abdominal wall out but as inspiratory effort continues against a closed airway, increasing intrathoracic pressure will draw the chest wall paradoxically inwards (against the opposing action of the intercostal muscles). To the observer, in inspiration there is abdominal expansion with chest collapse and during expiration the reverse is seen. As inspiratory effort increases and expiration becomes active, the see-sawing pattern becomes more pronounced.

Flail chest is a loss of stability of the thoracic cage that occurs when a segment of the anterior or lateral thoracic wall moves freely because of multiple rib fractures, allowing the loose segment to move paradoxically inward on inspiration and outward on expiration. If a large enough segment of the chest is affected, ventilation is impaired.

< Previous | Next >

Something wrong?

## Question Navigator

1 Answered
2 Answered
3 Answered
4 Answered
5 Answered
6 Answered
7 Answered
8 Answered
9 Answered
10 Answered
11 Answered
12 Answered



©2014 - 2017 FRCEM Success | Website designed & hosted by Cyberfrog Design

# Anatomy: Thorax

Question 42 of 134

## Regarding the thymus gland, which of the following statements is INCORRECT:

a The thymus gland is the most posterior component of the superior mediastinum.

b The thymus is a secondary lymphoid organ important for T-cell maturation.

c The thymus gland typically extends into the anterior mediastinum.

d The thymus gland begins to atrophy after puberty.

e The thymus gland lies immediately posterior to the manubrium of the sternum.

< Previous | Next > | See Answer

Something wrong?

Question Navigator

1 Answered
2 Answered
3 Answered
4 Answered
5 Answered
6 Answered
7 Answered
8 Answered
9 Answered
10 Answered
11 Answered
12 Answered



©2014 - 2017 FRCEM Success | Website designed & hosted by Cyberfrog Design

# Anatomy: Thorax

Question 42 of 134

Regarding the thymus gland, which of the following statements is INCORRECT:

a) The thymus gland is the most posterior component of the superior mediastinum. ✔

b) **The thymus is a secondary lymphoid organ important for T-cell maturation.** ✘

c) The thymus gland typically extends into the anterior mediastinum.

d) The thymus gland begins to atrophy after puberty.

e) The thymus gland lies immediately posterior to the manubrium of the sternum.

## Answer

The thymus gland is the most anterior component of the superior mediastinum lying immediately posterior to the manubrium of the sternum.

## Notes

The thymus gland is the most anterior component of the superior mediastinum lying immediately posterior to the manubrium of the sternum.

The superior aspect of the thymus can reach as high as the thyroid gland in the neck and the inferior aspect typically extends into the anterior mediastinum over the pericardium.

The thymus is a large structure in the child, important in early development of the immune system and begins to atrophy after puberty. In adulthood it is usually replaced by adipose tissue and is barely recognisable. Nevertheless, residual T-cell lymphopoiesis continues throughout adult life.

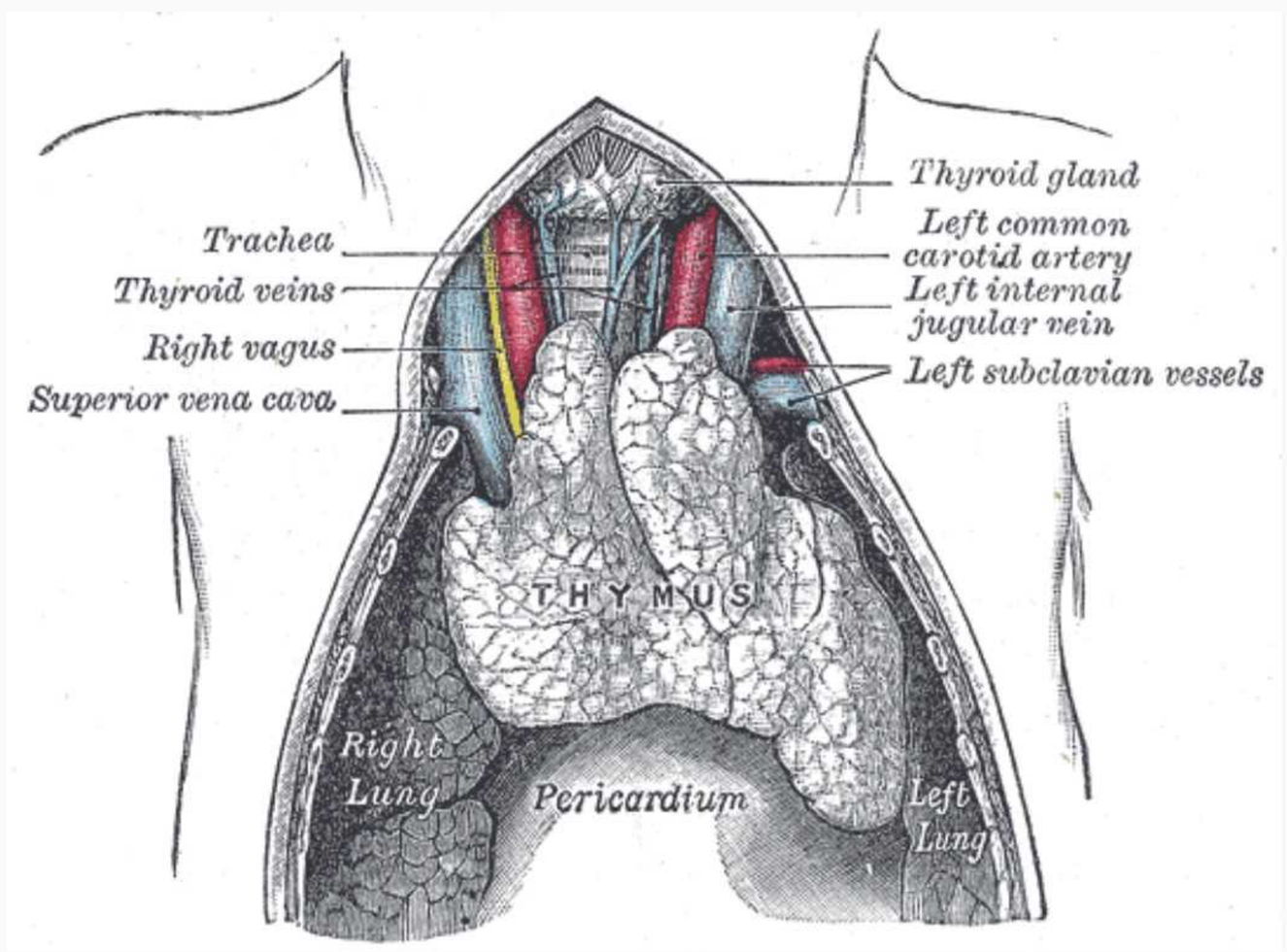


By Henry Vandyke Carter [Public domain], via Wikimedia Commons

## Question Navigator

1 Answered
2 Answered
3 Answered
4 Answered
5 Answered
6 Answered
7 Answered
8 Answered
9 Answered
10 Answered
11 Answered
12 Answered

< Previous | Next >

Something wrong?



©2014 - 2017 FRCEM Success | Website designed & hosted by Cyberfrog Design

# Anatomy: Thorax

Question 43 of 134

## The interventricular septum is primarily supplied by which of the following coronary vessels:

a Right coronary artery

b Right marginal branch

c Posterior interventricular branch

d Anterior interventricular branch

e Left circumflex branch

< Previous | Next > | See Answer

Something wrong?

Question Navigator

1 Answered
2 Answered
3 Answered
4 Answered
5 Answered
6 Answered
7 Answered
8 Answered
9 Answered
10 Answered
11 Answered
12 Answered



©2014 - 2017 FRCEM Success | Website designed & hosted by Cyberfrog Design

# Anatomy: Thorax

Question 43 of 134

The interventricular septum is primarily supplied by which of the following coronary vessels:

a) Right coronary artery
b) Right marginal branch
c) Posterior interventricular branch
d) **Anterior interventricular branch** ✔
e) Left circumflex branch

## Answer

The anterior two-thirds of the interventricular septum (including the AV bundles and branches) is supplied by the anterior interventricular branch (left anterior descending artery). The posterior one-third is supplied by the posterior interventricular branch of the right coronary artery.

## Notes

The right and left coronary arteries arise from the right and left aortic sinuses in the initial portion of the ascending aorta and supply the muscle and other tissues of the heart.

| Artery | Territory of supply |
|---|---|
| Right coronary artery | Right atrium and ventricle, sinoatrial node, atrioventricular node |
| Right marginal branch | Inferior aspect of right ventricle |
| Posterior interventricular branch | Posterior aspect of right and left ventricles, posterior one-third of interventricular septum |
| Left coronary artery | Via main branches below |
| Anterior interventricular branch | Right and left ventricles, anterior two-thirds of interventricular septum |
| Left circumflex branch | Left atrium and left ventricle |

**Territories of supply**

Although there is variation, in most people the territories of supply are as follows:

The right coronary artery supplies:

- the right atrium
- most of the right ventricle
- the sinoatrial and atrioventricular nodes
- the interatrial septum
- a portion of the left atrium
- the posteroinferior one-third of the interventricular septum
- a portion of the posterior part of the left ventricle

The left coronary artery supplies:

- most of the left atrium
- most of the left ventricle
- a portion of the right ventricle
- most of the interventricular septum (including the atrioventricular bundle and branches)

**Branches**

The right coronary artery supplies the right atrium, the sinoatrial node and the atrioventricular node (via the SA and AV nodal branches) and gives rise to two principal branches:

- the right marginal branch (supplying the inferior margin of the right ventricle and the apex)
- the posterior interventricular branch (supplying the posterior aspect of the right and left ventricles and the posterior one-third of the interventricular septum).

The left coronary artery gives rise to two principal branches:

- the anterior interventricular branch (supplying the right and left ventricles, the apex and the anterior two-thirds of the interventricular septum)
- the circumflex branch (supplying the left atrium and left ventricle).

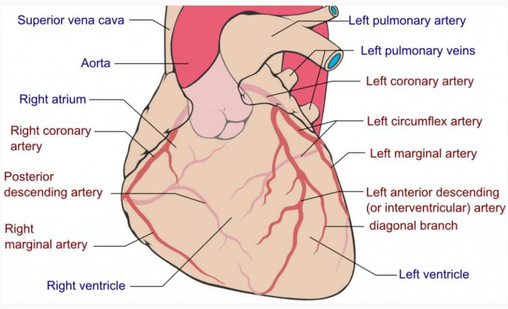


By Coronary.pdf: Patrick J. Lynch, medical illustrator derivative work: Fred the Oyster (talk) adaption and further labeling: Mikael Häggström (Coronary.pdf) [CC BY-SA 3.0 (http://creativecommons.org/licenses/by-sa/3.0)], via Wikimedia Commons

< Previous | Next >

Something wrong?

## Question Navigator

1 Answered
2 Answered
3 Answered
4 Answered
5 Answered
6 Answered
7 Answered
8 Answered
9 Answered
10 Answered
11 Answered
12 Answered



©2014 - 2017 FRCEM Success | Website designed & hosted by Cyberfrog Design

# Anatomy: Thorax

Question 44 of 134

## Which of the following structures pass through the caval opening in the diaphragm:

a Inferior vena cava and vagus nerve

b Inferior vena cava and right phrenic nerve

c Inferior vena cava and thoracic duct

d Inferior vena cava and aorta

e Inferior vena cava and azygos vein

< Previous | Next > | See Answer

Something wrong?

## Question Navigator

1 Answered
2 Answered
3 Answered
4 Answered
5 Answered
6 Answered
7 Answered
8 Answered
9 Answered
10 Answered
11 Answered
12 Answered



©2014 - 2017 FRCEM Success | Website designed & hosted by Cyberfrog Design

# Anatomy: Thorax

Question 44 of 134

Which of the following structures pass through the caval opening in the diaphragm:

**a)** Inferior vena cava and vagus nerve
**b)** **Inferior vena cava and right phrenic nerve** ✔
**c)** Inferior vena cava and thoracic duct
**d)** Inferior vena cava and aorta
**e)** Inferior vena cava and azygos vein

## Answer

The caval opening in the diaphragm is at vertebral level T8 and transits the inferior vena cava and the right phrenic nerve.

## Notes

The diaphragm is a musculotendinous structure that separates the thoracic cavity from the abdominal cavity.

| Structure | Diaphragm |
|---|---|
| Primary function | Respiration – contraction of diaphragm flattens diaphragm increasing vertical dimension of thorax (inspiration), relaxation of diaphragm elevates diaphragm decreasing vertical dimension of thorax (expiration) |
| Secondary functions | Assists in straining movements by increasing intra-abdominal pressure, acts as functional sphincter on oesophagus preventing acid reflux |
| Peripheral attachments | Xiphoid process of sternum, costal cartilages ribs 7 – 10, ends of ribs 11 and 12, arcuate ligaments and lumbar vertebrae |
| Central attachment | Fuses with fibrous pericardium superiorly |
| Surface markings | Attachments: vertebrae T8/T9 anteriorly, vertebra T12 posteriorly, Domes: right dome 5th rib, left dome 5th intercostal space |
| Openings | Oesophageal opening at T10 (oesophagus, vagus nerve), aortic opening at T12 (aorta, thoracic duct and azygos vein), caval opening at T8 (inferior vena cava and right phrenic nerve) |
| Innervation | Phrenic nerve (C3 – C5) |

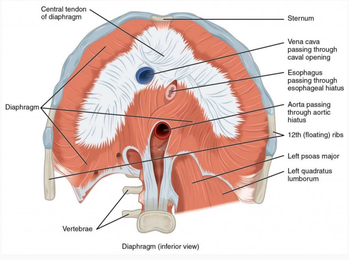


By OpenStax [CC BY 4.0 (http://creativecommons.org/licenses/by/4.0)], via Wikimedia Commons

### Function

The diaphragm performs an important function in respiration; contraction of the domes of the diaphragm in inspiration flattens the diaphragm, increasing the vertical dimension of the thorax and vice versa in expiration, with relaxation and elevation of the diaphragm reducing the vertical dimension of the thorax.

The diaphragm is also involved in non-respiratory functions; helping to expel vomit, faeces, and urine from the body by increasing intraabdominal pressure, and preventing acid reflux by exerting pressure on the oesophagus as it passes through the oesophageal opening.

### Attachments

The diaphragm is attached peripherally to:

- the xiphoid process of the sternum and the costal cartilages of ribs 7 – 10 (the costal margin) anteriorly
- the ends of ribs 11 and 12 laterally
- the arcuate ligaments and vertebrae posteriorly.

From these peripheral attachments, muscle fibres converge to form the central tendon which fuses with the fibrous pericardium superiorly.

### Surface markings

In the medial sagittal plane, the diaphragm slopes inferiorly from its anterior attachment to the xiphoid at approximately vertebral level T8/T9 to its posterior attachment to the median arcuate ligament at approximately vertebral level T12.

At rest the right dome of the diaphragm lies slightly higher than the left; this is thought to be due to the position of the liver. In normal expiration, the normal upper limits of the superior margins are the fifth rib for the right dome, the fifth intercostal space for the left dome and the xiphoid process for the central tendon.

### Diaphragmatic openings

Structures travelling between the thorax and abdomen must pass through the diaphragm via three main openings.

The oesophageal opening at vertebral level T10 transmits:

- the oesophagus
- the anterior and posterior vagal trunks
- oesophageal branches of the left gastric vessels
- a few lymphatics.

The aortic opening at vertebral level T12 transmits:

- the aorta
- the thoracic duct
- the azygos vein and sometimes the hemiazygos vein.

The caval opening at vertebral level T8 transmits:

- the inferior vena cava
- the right phrenic nerve.

### Innervation

The entire motor supply of the diaphragm is from the right and left phrenic nerves (C3 – C5) which penetrate the diaphragm and innervate it from its abdominal surface.

Damage to the phrenic nerve will result in hemiparalysis of the diaphragm. Paralysis of the diaphragm produces a paradoxical movement. The affected side of the diaphragm moves upwards during inspiration (as it is pushed superiorly by the abdominal viscera that are being actively compressed by the other half), and downwards during expiration.

A unilateral diaphragmatic paralysis is usually asymptomatic, and is most often an incidental finding on x-ray. If both sides are paralysed, the patient may experience poor exercise tolerance, orthopnoea and fatigue. Lung function tests will show a restrictive deficit.

### Diaphragmatic herniation

Diaphragmatic hernias are defined as congenital or acquired defects in the diaphragm. There are two main types of congenital diaphragmatic hernias; Bochdalek hernias and Morgagni hernias.

Acquired diaphragmatic hernias include traumatic diaphragmatic rupture, hiatus hernia and iatrogenic diaphragmatic hernias. Depending on the location and size of the defect, retroperitoneal or intra-abdominal organs and tissues can prolapse into the thoracic cavity due to the negative intrathoracic pressure.

Diaphragmatic rupture usually results from blunt abdominal trauma, which is typically associated with motor-vehicle accidents; the most commonly herniated viscera are the stomach and colon on the left side, and the liver on the right side.

In hiatus hernia, the stomach herniates through the oesophageal opening of the diaphragm, typically resulting in symptoms of acid reflux.

< Previous | Next >

Something wrong?

## Question Navigator

1 Answered
2 Answered
3 Answered
4 Answered
5 Answered
6 Answered
7 Answered
8 Answered
9 Answered
10 Answered
11 Answered
12 Answered



©2014 - 2017 FRCEM Success | Website designed & hosted by Cyberfrog Design

# Anatomy: Thorax

Question 45 of 134

## Regarding the trachea, which of the following statements is CORRECT:

a The trachea descends posterior to the oesophagus.

b The trachea is formed of 5 C-shaped rings of cartilage.

c The posterior wall of the trachea is formed by a tough fibrous trachealis sheath.

d The trachea arises at the C2 vertebral level.

e Anteriorly the trachea is related to the aortic arch.

< Previous | Next > | See Answer

Something wrong?

Question Navigator

1 Answered
2 Answered
3 Answered
4 Answered
5 Answered
6 Answered
7 Answered
8 Answered
9 Answered
10 Answered
11 Answered
12 Answered



©2014 - 2017 FRCEM Success | Website designed & hosted by Cyberfrog Design

# Anatomy: Thorax

Question 45 of 134

Regarding the trachea, which of the following statements is CORRECT:

**a)** The trachea descends posterior to the oesophagus.
**b)** The trachea is formed of 5 C-shaped rings of cartilage.
**c)** The posterior wall of the trachea is formed by a tough fibrous trachealis sheath.
**d)** The trachea arises at the C2 vertebral level.
**e)** **Anteriorly the trachea is related to the aortic arch.** ✔

## Answer

The trachea is related anteriorly to the aortic arch in the thorax.

## Notes

The trachea arises at the lower border of the cricoid cartilage in the neck, as a continuation of the larynx. It extends from vertebral level C6 to T4/T5 at which point it bifurcates into the right and left main bronchi (at the level of the sternal angle).

The trachea is formed anteriorly by 15 – 20 C-shaped rings of hyaline cartilage which mechanically hold the airway open whilst allowing it flexibility. The trachealis muscle connects the ends of the incomplete rings and forms the posterior wall of the trachea. The trachealis muscle is able to constrict the trachea, allowing air to be expelled with more force e.g. during coughing.

The trachea and bronchi are lined by ciliated pseudostratified columnar epithelium, interspersed by mucus-producing goblet cells. This mucous membrane functions as the mucociliary escalator, trapping particles in sticky mucus and sweeping it along the airway.

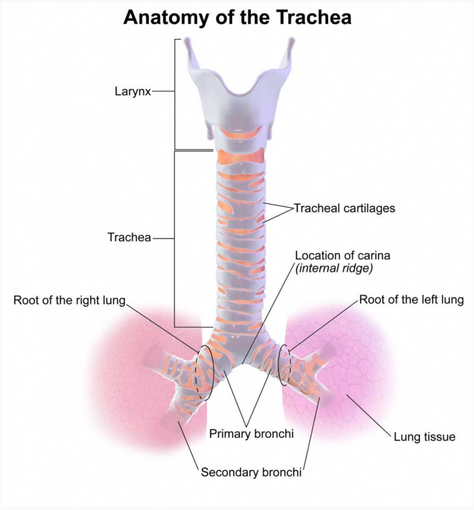


By Blausen.com staff. "Blausen gallery 2014". Wikiversity Journal of Medicine. DOI:10.15347/wjm/2014.010. ISSN 20018762. (Own work) [CC BY 3.0 (http://creativecommons.org/licenses/by/3.0)], via Wikimedia Commons

**Relations**

The trachea descends anterior to the oesophagus and inclines slightly to the right.

In the thorax, anteriorly it is related to:

- the thymic remnants
- the left brachiocephalic vein
- the aortic arch
- the brachiocephalic trunk
- the left common carotid artery
- the deep cardiac plexus.

Laterally it is related to:

- the pleura, the right vagus nerve and the brachiocephalic trunk on the right
- the left recurrent laryngeal nerve, the aortic arch and the left common carotid and subclavian vessels on the left.

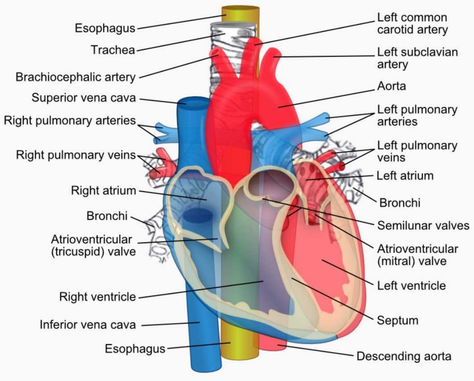


ZooFari [CC BY-SA 3.0 (http://creativecommons.org/licenses/by-sa/3.0)], via Wikimedia Commons

< Previous | Next > | Something wrong?

## Question Navigator

1 Answered
2 Answered
3 Answered
4 Answered
5 Answered
6 Answered
7 Answered
8 Answered
9 Answered
10 Answered
11 Answered
12 Answered



©2014 - 2017 FRCEM Success | Website designed & hosted by Cyberfrog Design

# Anatomy: Thorax

Question 46 of 134

## The apex of the heart lies deep to which of the following landmarks:

a The left fifth intercostal space in the midclavicular line

b The left fifth intercostal space in the midaxillary line

c The left fourth intercostal space in the midclavicular line

d The left fourth intercostal space in the midaxillary line

e The sixth intercostal space in the midaxillary line

< Previous | Next > | See Answer

Something wrong?

Question Navigator

1 Answered
2 Answered
3 Answered
4 Answered
5 Answered
6 Answered
7 Answered
8 Answered
9 Answered
10 Answered
11 Answered
12 Answered



©2014 - 2017 FRCEM Success | Website designed & hosted by Cyberfrog Design

# Anatomy: Thorax

Question 46 of 134

The apex of the heart lies deep to which of the following landmarks:

**a) The left fifth intercostal space in the midclavicular line** ✔
**b)** The left fifth intercostal space in the midaxillary line
**c)** The left fourth intercostal space in the midclavicular line
**d)** The left fourth intercostal space in the midaxillary line
**e)** The sixth intercostal space in the midaxillary line

## Answer

The apex of the heart projects forwards, downwards and to the left. The apex is formed by the inferolateral part of the left ventricle and is positioned deep to the left fifth intercostal space in the midclavicular line.

## Notes

| Border/Surface | Main structure (contributing structures) |
|---|---|
| Apex | Left ventricle |
| Base | Left atrium (right atrium, proximal great veins) |
| Anterior surface | Right ventricle (right atrium, left ventricle) |
| Inferior surface | Left and right ventricle |
| Left pulmonary surface | Left ventricle (left atrium) |
| Right pulmonary surface | Right atrium |
| Inferior border | Right ventricle (left ventricle) |
| Left border | Left ventricle (left auricle) |
| Right border | Right atrium |
| Superior border | Both atria, roots of great vessels |

The general shape and orientation of the heart are that of a pyramid that has fallen over and is resting on one of its sides.

- The apex of this pyramid projects forwards, downwards and to the left. The apex is formed by the inferolateral part of the left ventricle and is positioned deep to the left fifth intercostal space in the midclavicular line.
- The base is facing posteriorly. The base is formed mostly by the left atrium with a small portion of the right atrium and the proximal part of the great veins, and is fixed posteriorly to the pericardial wall, opposite the bodies of the T5 – T8 vertebrae (T6 – T9 when standing). The oesophagus lies immediately posterior to the base.

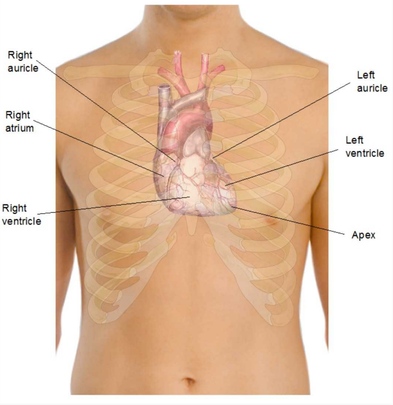


Modified by FRCEM Success. Original by Mikael Häggström (See above. All used images are in public domain.) [Public domain], via Wikimedia Commons

**Surfaces**

There are four surfaces to the upturned pyramid:

- The anterior (sternocostal) surface consists mostly of the right ventricle with some of the right atrium and some of the left ventricle.
- The inferior (diaphragmatic) surface consists of the left ventricle with a small portion of the right ventricle separated by the posterior interventricular groove.
- The left pulmonary surface consists mainly of the left ventricle and a portion of the left atrium.
- The right pulmonary surface consists of the right atrium.

**Borders**

There are four main borders separating the surfaces of the heart:

- The inferior border is formed mostly by the right ventricle and a small portion of the left ventricle near the apex.
- The left border is formed mostly by the left ventricle with a small portion of the left auricle.
- The right border is formed by the right atrium.
- The superior border is formed by both atria and the roots of the great vessels.

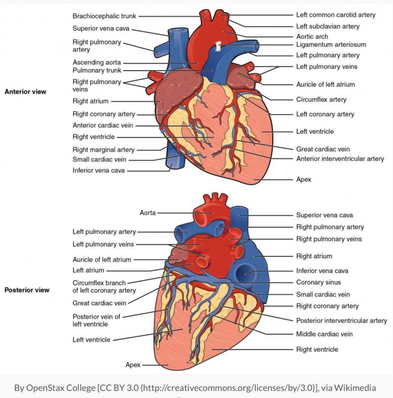


By OpenStax College [CC BY 3.0 (http://creativecommons.org/licenses/by/3.0)], via Wikimedia Commons

< Previous | Next >

Something wrong?

## Question Navigator

1 Answered
2 Answered
3 Answered
4 Answered
5 Answered
6 Answered
7 Answered
8 Answered
9 Answered
10 Answered
11 Answered
12 Answered



©2014 - 2017 FRCEM Success | Website designed & hosted by Cyberfrog Design

# Anatomy: Thorax

Question 47 of 134

## A 50 year old man presents to ED complaining of a hoarse voice. Imaging shows an aneurysm of the aortic arch. Which of the following structures is likely being compressed:

a Left phrenic nerve

b Oesophageal plexus

c Left sympathetic trunk

d Left recurrent laryngeal nerve

e Left vagus nerve

< Previous | Next > | See Answer

Something wrong?

## Question Navigator

1 Answered
2 Answered
3 Answered
4 Answered
5 Answered
6 Answered
7 Answered
8 Answered
9 Answered
10 Answered
11 Answered
12 Answered



©2014 - 2017 FRCEM Success | Website designed & hosted by Cyberfrog Design

# Anatomy: Thorax

Question 47 of 134

A 50 year old man presents to ED complaining of a hoarse voice. Imaging shows an aneurysm of the aortic arch. Which of the following structures is likely being compressed:

**a)** Left phrenic nerve
**b)** Oesophageal plexus
**c)** Left sympathetic trunk
**d)** **Left recurrent laryngeal nerve** ✔
**e)** Left vagus nerve

## Answer

The left recurrent laryngeal nerve passes below and behind the aortic arch before ascending towards the tracheo-oesophageal groove medial to the arch of the aorta. Damage to the recurrent laryngeal nerve will result in a hoarse voice.

## Notes

The lungs lie on either side of the mediastinum, each surrounded by a pleural cavity. They are suspended from the mediastinum by the root of the lung, a short tubular collection of structures.

**Lung root**

The root is lined by a layer of mediastinal pleura that reflects onto the surface of the lungs as visceral pleura. The region outlined by this pleural reflection on the medial surface of the lung is the hilum, where structures enter and leave.

The hila are located at the level of the 3rd – 4th costal cartilage anteriorly, and the T5 – T7 vertebrae posteriorly.

Each lung root contains:

- a pulmonary artery
- two pulmonary veins
- a main bronchus
- bronchial vessels,
- nerves and
- lymphatics.

Generally the pulmonary artery is superior in the lung root, the pulmonary veins are inferior and the bronchi are somewhat posterior in position.

In the mediastinum, the vagus nerves pass immediately posteriorly to the lung roots, while the phrenic nerves pass immediately anterior to them.

On the right side, the lobar bronchus to the superior lobe branches from the main bronchus in the root, whereas on the left, it branches within the lung itself.

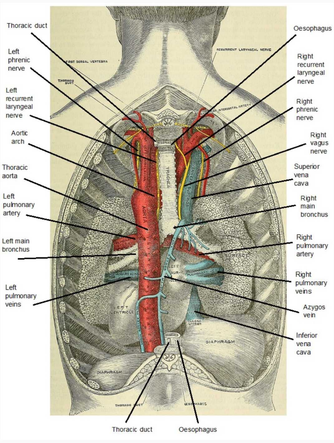


Modified by FRCEM Success. Original by Gray, Henry, 1825-1861; Carter, H. V. (Henry Vandyke), 1831-1897; Pick, T. Pickering (Thomas Pickering), 1841-1919 [No restrictions], via Wikimedia Commons

**Relations**

The medial surface of the right lung lies adjacent to:

- the heart
- the inferior vena cava
- the superior vena cava
- the azygos vein
- the oesophagus

The medial surface of the left lung lies adjacent to:

- the heart
- the aortic arch
- the thoracic aorta
- the oesophagus.

The right and left subclavian arteries and veins arch over and are related to the superior lobe of the right and left lung as they pass over the dome of the cervical pleura and into the axilla.

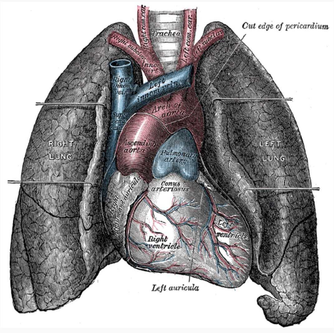


By Henry Vandyke Carter [Public domain], via Wikimedia Commons

**Blood supply**

The right and left pulmonary arteries originate from the pulmonary trunk (at the vertebral level T4/T5) and carry deoxygenated blood to the lungs.

On each side a superior and inferior pulmonary vein carries oxygenated blood from the lungs back to the heart.

The bronchi (down to the terminal bronchioles), lung roots, visceral pleura and supporting lung tissues receive their nutrient blood supply from the bronchial arteries, which arise from the descending aorta.

**Lymphatics**

Lymph from the lungs drains via hilar, tracheobronchial and mediastinal lymph nodes.

**Innervation**

The nerve supply to the lungs is from the anterior and posterior pulmonary plexus (networks of nerves derived from the sympathetic trunk and vagus nerve).

The parasympathetic nerve supply, carried by the vagus nerve, stimulates secretion from the bronchial glands, contraction of bronchial smooth muscle, and vasodilation of the pulmonary vessels. The vagus nerve also carries afferent fibres of pain, cough reflex and stretch of the lung (during inspiration).

The sympathetic nerve supply stimulates relaxation of bronchial smooth muscle, and vasoconstriction of the pulmonary vessels.

< Previous | Next >

Something wrong?

## Question Navigator

1 Answered
2 Answered
3 Answered
4 Answered
5 Answered
6 Answered
7 Answered
8 Answered
9 Answered
10 Answered
11 Answered
12 Answered



©2014 - 2017 FRCEM Success | Website designed & hosted by Cyberfrog Design

# Anatomy: Thorax

Question 48 of 134

## The left border of the heart is formed predominantly by which of the following:

a Right atrium

b Left atrium

c Right ventricle

d Left ventricle

e Great vessels

< Previous | Next > | See Answer

Something wrong?

Question Navigator

1 Answered
2 Answered
3 Answered
4 Answered
5 Answered
6 Answered
7 Answered
8 Answered
9 Answered
10 Answered
11 Answered
12 Answered



©2014 - 2017 FRCEM Success | Website designed & hosted by Cyberfrog Design

# Anatomy: Thorax

Question 48 of 134

The left border of the heart is formed predominantly by which of the following:

**a)** Right atrium
**b)** Left atrium
**c)** Right ventricle
**d)** **Left ventricle** ✔
**e)** Great vessels

## Answer

The left border is formed mostly by the left ventricle with a small portion of the left auricle.

## Notes

| Border/Surface | Main structure (contributing structures) |
|---|---|
| Apex | Left ventricle |
| Base | Left atrium (right atrium, proximal great veins) |
| Anterior surface | Right ventricle (right atrium, left ventricle) |
| Inferior surface | Left and right ventricle |
| Left pulmonary surface | Left ventricle (left atrium) |
| Right pulmonary surface | Right atrium |
| Inferior border | Right ventricle (left ventricle) |
| Left border | Left ventricle (left auricle) |
| Right border | Right atrium |
| Superior border | Both atria, roots of great vessels |

The general shape and orientation of the heart are that of a pyramid that has fallen over and is resting on one of its sides.

- The apex of this pyramid projects forwards, downwards and to the left. The apex is formed by the inferolateral part of the left ventricle and is positioned deep to the left fifth intercostal space in the midclavicular line.
- The base is facing posteriorly. The base is formed mostly by the left atrium with a small portion of the right atrium and the proximal part of the great veins, and is fixed posteriorly to the pericardial wall, opposite the bodies of the T5 – T8 vertebrae (T6 – T9 when standing). The oesophagus lies immediately posterior to the base.

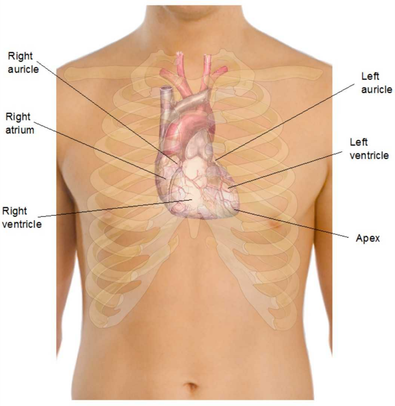


Modified by FRCEM Success. Original by Mikael Häggström (See above. All used images are in public domain.) [Public domain], via Wikimedia Commons

**Surfaces**

There are four surfaces to the upturned pyramid:

- The anterior (sternocostal) surface consists mostly of the right ventricle with some of the right atrium and some of the left ventricle.
- The inferior (diaphragmatic) surface consists of the left ventricle with a small portion of the right ventricle separated by the posterior interventricular groove.
- The left pulmonary surface consists mainly of the left ventricle and a portion of the left atrium.
- The right pulmonary surface consists of the right atrium.

**Borders**

There are four main borders separating the surfaces of the heart:

- The inferior border is formed mostly by the right ventricle and a small portion of the left ventricle near the apex.
- The left border is formed mostly by the left ventricle with a small portion of the left auricle.
- The right border is formed by the right atrium.
- The superior border is formed by both atria and the roots of the great vessels.

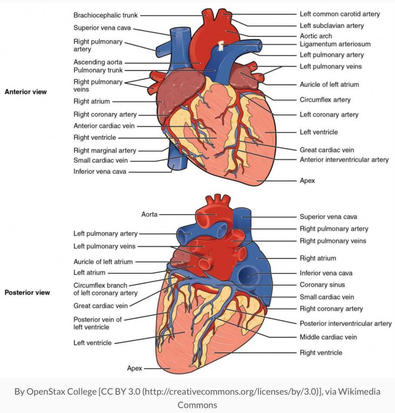


By OpenStax College [CC BY 3.0 (http://creativecommons.org/licenses/by/3.0)], via Wikimedia Commons

< Previous | Next >

Something wrong?

Question Navigator

1 Answered
2 Answered
3 Answered
4 Answered
5 Answered
6 Answered
7 Answered
8 Answered
9 Answered
10 Answered
11 Answered
12 Answered



©2014 - 2017 FRCEM Success | Website designed & hosted by Cyberfrog Design

# Anatomy: Thorax

Question 49 of 134

## Contraction of the diaphragm results in which of the following effects:

a Elevation of the diaphragm

b Increased vertical dimension of the thorax

c Decreased intra-abdominal pressure

d Increased anteroposterior dimension of the thorax

e Increased intrathoracic pressure

< Previous | Next > | See Answer

Something wrong?

Question Navigator

1 Answered
2 Answered
3 Answered
4 Answered
5 Answered
6 Answered
7 Answered
8 Answered
9 Answered
10 Answered
11 Answered
12 Answered



©2014 - 2017 FRCEM Success | Website designed & hosted by Cyberfrog Design

# Anatomy: Thorax

Question 49 of 134

Contraction of the diaphragm results in which of the following effects:

a) Elevation of the diaphragm
b) **Increased vertical dimension of the thorax** ✔
c) Decreased intra-abdominal pressure
d) Increased anteroposterior dimension of the thorax
e) Increased intrathoracic pressure

## Answer

Contraction of the diaphragm (as in inspiration) results in flattening (depression) of the diaphragm with an increase in vertical dimension of the thorax. This results in decreased intrathoracic pressure and increased intra-abdominal pressure.

## Notes

The diaphragm is a musculotendinous structure that separates the thoracic cavity from the abdominal cavity.

| Structure | Diaphragm |
|---|---|
| Primary function | Respiration – contraction of diaphragm flattens diaphragm increasing vertical dimension of thorax (inspiration), relaxation of diaphragm elevates diaphragm decreasing vertical dimension of thorax (expiration) |
| Secondary functions | Assists in straining movements by increasing intra-abdominal pressure, acts as functional sphincter on oesophagus preventing acid reflux |
| Peripheral attachments | Xiphoid process of sternum, costal cartilages ribs 7 – 10, ends of ribs 11 and 12, arcuate ligaments and lumbar vertebrae |
| Central attachment | Fuses with fibrous pericardium superiorly |
| Surface markings | Attachments: vertebrae T8/T9 anteriorly, vertebra T12 posteriorly, Domes: right dome 5th rib, left dome 5th intercostal space |
| Openings | Oesophageal opening at T10 (oesophagus, vagus nerve), aortic opening at T12 (aorta, thoracic duct and azygos vein), caval opening at T8 (inferior vena cava and right phrenic nerve) |
| Innervation | Phrenic nerve (C3 – C5) |

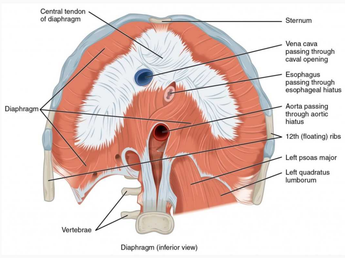


By OpenStax [CC BY 4.0 (http://creativecommons.org/licenses/by/4.0)], via Wikimedia Commons

**Function**

The diaphragm performs an important function in respiration; contraction of the domes of the diaphragm in inspiration flattens the diaphragm, increasing the vertical dimension of the thorax and vice versa in expiration, with relaxation and elevation of the diaphragm reducing the vertical dimension of the thorax.

The diaphragm is also involved in non-respiratory functions; helping to expel vomit, faeces, and urine from the body by increasing intraabdominal pressure, and preventing acid reflux by exerting pressure on the oesophagus as it passes through the oesophageal opening.

**Attachments**

The diaphragm is attached peripherally to:

- the xiphoid process of the sternum and the costal cartilages of ribs 7 – 10 (the costal margin) anteriorly
- the ends of ribs 11 and 12 laterally
- the arcuate ligaments and vertebrae posteriorly.

From these peripheral attachments, muscle fibres converge to form the central tendon which fuses with the fibrous pericardium superiorly.

**Surface markings**

In the medial sagittal plane, the diaphragm slopes inferiorly from its anterior attachment to the xiphoid at approximately vertebral level T8/T9 to its posterior attachment to the median arcuate ligament at approximately vertebral level T12.

At rest the right dome of the diaphragm lies slightly higher than the left; this is thought to be due to the position of the liver. In normal expiration, the normal upper limits of the superior margins are the fifth rib for the right dome, the fifth intercostal space for the left dome and the xiphoid process for the central tendon.

**Diaphragmatic openings**

Structures travelling between the thorax and abdomen must pass through the diaphragm via three main openings.

The oesophageal opening at vertebral level T10 transmits:

- the oesophagus
- the anterior and posterior vagal trunks
- oesophageal branches of the left gastric vessels
- a few lymphatics.

The aortic opening at vertebral level T12 transmits:

- the aorta
- the thoracic duct
- the azygos vein and sometimes the hemiazygos vein.

The caval opening at vertebral level T8 transmits:

- the inferior vena cava
- the right phrenic nerve.

**Innervation**

The entire motor supply of the diaphragm is from the right and left phrenic nerves (C3 – C5) which penetrate the diaphragm and innervate it from its abdominal surface.

Damage to the phrenic nerve will result in hemiparalysis of the diaphragm. Paralysis of the diaphragm produces a paradoxical movement. The affected side of the diaphragm moves upwards during inspiration (as it is pushed superiorly by the abdominal viscera that are being actively compressed by the other half), and downwards during expiration.

A unilateral diaphragmatic paralysis is usually asymptomatic, and is most often an incidental finding on x-ray. If both sides are paralysed, the patient may experience poor exercise tolerance, orthopnoea and fatigue. Lung function tests will show a restrictive deficit.

**Diaphragmatic herniation**

Diaphragmatic hernias are defined as congenital or acquired defects in the diaphragm. There are two main types of congenital diaphragmatic hernias; Bochdalek hernias and Morgagni hernias.

Acquired diaphragmatic hernias include traumatic diaphragmatic rupture, hiatus hernia and iatrogenic diaphragmatic hernias. Depending on the location and size of the defect, retroperitoneal or intra-abdominal organs and tissues can prolapse into the thoracic cavity due to the negative intrathoracic pressure.

Diaphragmatic rupture usually results from blunt abdominal trauma, which is typically associated with motor-vehicle accidents; the most commonly herniated viscera are the stomach and colon on the left side, and the liver on the right side.

In hiatus hernia, the stomach herniates through the oesophageal opening of the diaphragm, typically resulting in symptoms of acid reflux.

< Previous | Next >

Something wrong?

## Question Navigator

1 Answered
2 Answered
3 Answered
4 Answered
5 Answered
6 Answered
7 Answered
8 Answered
9 Answered
10 Answered
11 Answered
12 Answered



©2014 - 2017 FRCEM Success | Website designed & hosted by Cyberfrog Design

# Anatomy: Thorax

Question 50 of 134

## Which of the following best describes the territory of supply of the circumflex artery:

a Right atrium and ventricle

b Right atrium, left atrium and interatrial septum

c Right atrium and sinoatrial node

d Left atrium and ventricle

e Left ventricle and interventricular septum

< Previous | Next > | See Answer

Something wrong?

Question Navigator

1 Answered
2 Answered
3 Answered
4 Answered
5 Answered
6 Answered
7 Answered
8 Answered
9 Answered
10 Answered
11 Answered
12 Answered



©2014 - 2017 FRCEM Success | Website designed & hosted by Cyberfrog Design

# Anatomy: Thorax

Question 50 of 134

Which of the following best describes the territory of supply of the circumflex artery:

a) Right atrium and ventricle
b) Right atrium, left atrium and interatrial septum
c) Right atrium and sinoatrial node
d) **Left atrium and ventricle** ✔
e) Left ventricle and interventricular septum

## Answer

The left circumflex branch supplies the left atrium and the left ventricle.

## Notes

The right and left coronary arteries arise from the right and left aortic sinuses in the initial portion of the ascending aorta and supply the muscle and other tissues of the heart.

| Artery | Territory of supply |
|---|---|
| Right coronary artery | Right atrium and ventricle, sinoatrial node, atrioventricular node |
| Right marginal branch | Inferior aspect of right ventricle |
| Posterior interventricular branch | Posterior aspect of right and left ventricles, posterior one-third of interventricular septum |
| Left coronary artery | Via main branches below |
| Anterior interventricular branch | Right and left ventricles, anterior two-thirds of interventricular septum |
| Left circumflex branch | Left atrium and left ventricle |

**Territories of supply**

Although there is variation, in most people the territories of supply are as follows:

The right coronary artery supplies:

- the right atrium
- most of the right ventricle
- the sinoatrial and atrioventricular nodes
- the interatrial septum
- a portion of the left atrium
- the posteroinferior one-third of the interventricular septum
- a portion of the posterior part of the left ventricle

The left coronary artery supplies:

- most of the left atrium
- most of the left ventricle
- a portion of the right ventricle
- most of the interventricular septum (including the atrioventricular bundle and branches)

**Branches**

The right coronary artery supplies the right atrium, the sinoatrial node and the atrioventricular node (via the SA and AV nodal branches) and gives rise to two principal branches:

- the right marginal branch (supplying the inferior margin of the right ventricle and the apex)
- the posterior interventricular branch (supplying the posterior aspect of the right and left ventricles and the posterior one-third of the interventricular septum).

The left coronary artery gives rise to two principal branches:

- the anterior interventricular branch (supplying the right and left ventricles, the apex and the anterior two-thirds of the interventricular septum)
- the circumflex branch (supplying the left atrium and left ventricle).

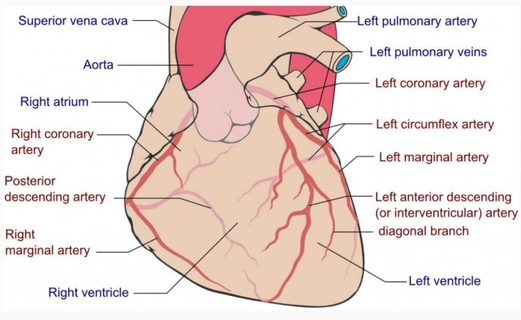


By Coronary.pdf: Patrick J. Lynch, medical illustrator derivative work: Fred the Oyster (talk) adaption and further labeling: Mikael Häggström (Coronary.pdf) [CC BY-SA 3.0 (http://creativecommons.org/licenses/by-sa/3.0)], via Wikimedia Commons

< Previous | Next > | Something wrong?

## Question Navigator

1 Answered
2 Answered
3 Answered
4 Answered
5 Answered
6 Answered
7 Answered
8 Answered
9 Answered
10 Answered
11 Answered
12 Answered



©2014 - 2017 FRCEM Success | Website designed & hosted by Cyberfrog Design

# Anatomy: Thorax

Question 51 of 134

## Regarding the muscles of the thoracic wall, which of the following statements is INCORRECT:

a The muscles of the thoracic wall are primarily organised into three layers.

b The external intercostal muscles are primarily active in inspiration.

c The internal intercostal muscles run posteroinferiorly from the rib above to the rib below.

d The transversus thoracis muscle is continuous inferiorly with the transversus abdominis muscle.

e The neurovascular bundle runs between the layers of the external and internal intercostal muscles.

< Previous | Next > | See Answer

Something wrong?

### Question Navigator

1 Answered
2 Answered
3 Answered
4 Answered
5 Answered
6 Answered
7 Answered
8 Answered
9 Answered
10 Answered
11 Answered
12 Answered



©2014 - 2017 FRCEM Success | Website designed & hosted by Cyberfrog Design

# Anatomy: Thorax

Question 51 of 134

Regarding the muscles of the thoracic wall, which of the following statements is INCORRECT:

**a)** The muscles of the thoracic wall are primarily organised into three layers.
**b)** The external intercostal muscles are primarily active in inspiration.
**c)** The internal intercostal muscles run posteroinferiorly from the rib above to the rib below.
**d)** The transversus thoracis muscle is continuous inferiorly with the transversus abdominis muscle.
**e)**

**The neurovascular bundle runs between the layers of the external and internal intercostal muscles.**

## Answer

The neurovascular bundles associated with the intercostal spaces pass around the thoracic wall in the costal grooves in a plane between the layers of the internal and innermost intercostal muscles.

## Notes

The intercostal muscles are three flat muscles found in each intercostal space that pass between adjacent ribs. As a group the intercostal muscles provide structural support of the intercostal spaces during breathing and can also act to move the ribs.

| Muscle | Function |
|---|---|
| External intercostal | Move ribs superiorly, most active in inspiration |
| Internal intercostal | Move ribs inferiorly, most active in expiration |
| Innermost intercostal | Acts with internal intercostal muscles |
| Transversus thoracis | Depresses costal cartilages |

The external intercostal muscles lie in the outer layer. They run anteroinferiorly from the rib above to the rib below, and are continuous with the external oblique muscle inferiorly. The external intercostal muscles act to move the ribs superiorly and are most active in inspiration.

The internal intercostal muscles lie deep to the external intercostal muscles. They run posteroinferiorly from the rib above to the rib below, and are continuous with the internal oblique muscle inferiorly. The internal intercostal muscles act to move the ribs inferiorly and are most active during expiration.

The innermost intercostal muscles are the deepest of the intercostal muscles and are very similar to the internal intercostal muscles in terms of structure and function.

The transversus thoracis muscle is also part of the innermost layer, and is continuous inferiorly with the transversus abdominis muscle inferiorly.

The neurovascular bundles associated with the intercostal spaces pass around the thoracic wall in the costal grooves in a plane between the layers of the internal and innermost intercostal muscles.

The intercostal and transversus thoracis muscles are innervated by the intercostal nerves (T1 – T11).

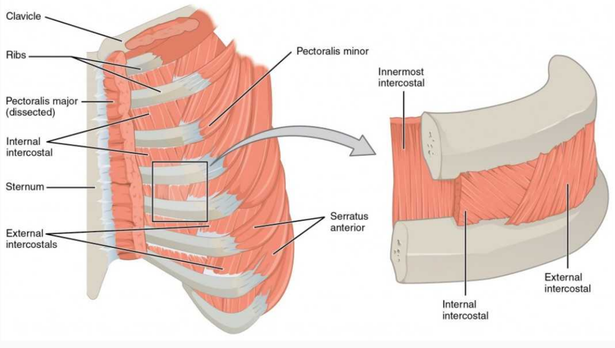


By CFCF (Own work) [CC BY-SA 4.0 (http://creativecommons.org/licenses/by-sa/4.0)], via Wikimedia Commons

< Previous | Next > | Something wrong?

## Question Navigator

1 Answered
2 Answered
3 Answered
4 Answered
5 Answered
6 Answered
7 Answered
8 Answered
9 Answered
10 Answered
11 Answered
12 Answered



©2014 - 2017 FRCEM Success | Website designed & hosted by Cyberfrog Design

# Anatomy: Thorax

Question 52 of 134

## Which of the following structures is the most uppermost in the lung root:

a Pulmonary vein

b Pulmonary artery

c Phrenic nerve

d Main bronchus

e Pulmonary plexus

< Previous | Next > | See Answer

Something wrong?

Question Navigator

1 Answered
2 Answered
3 Answered
4 Answered
5 Answered
6 Answered
7 Answered
8 Answered
9 Answered
10 Answered
11 Answered
12 Answered



©2014 - 2017 FRCEM Success | Website designed & hosted by Cyberfrog Design

# Anatomy: Thorax

Question 52 of 134

Which of the following structures is the most uppermost in the lung root:

**a)** Pulmonary vein
**b)** **Pulmonary artery** ✔
**c)** Phrenic nerve
**d)** Main bronchus
**e)** Pulmonary plexus

## Answer

The pulmonary artery is superior to the pulmonary vein, and the main bronchus sits posteriorly. The phrenic nerve descends anterior to the lung root.

## Notes

The lungs lie on either side of the mediastinum, each surrounded by a pleural cavity. They are suspended from the mediastinum by the root of the lung, a short tubular collection of structures.

**Lung root**

The root is lined by a layer of mediastinal pleura that reflects onto the surface of the lungs as visceral pleura. The region outlined by this pleural reflection on the medial surface of the lung is the hilum, where structures enter and leave.

The hila are located at the level of the 3rd – 4th costal cartilage anteriorly, and the T5 – T7 vertebrae posteriorly.

Each lung root contains:

- a pulmonary artery
- two pulmonary veins
- a main bronchus
- bronchial vessels,
- nerves and
- lymphatics.

Generally the pulmonary artery is superior in the lung root, the pulmonary veins are inferior and the bronchi are somewhat posterior in position.

In the mediastinum, the vagus nerves pass immediately posteriorly to the lung roots, while the phrenic nerves pass immediately anterior to them.

On the right side, the lobar bronchus to the superior lobe branches from the main bronchus in the root, whereas on the left, it branches within the lung itself.

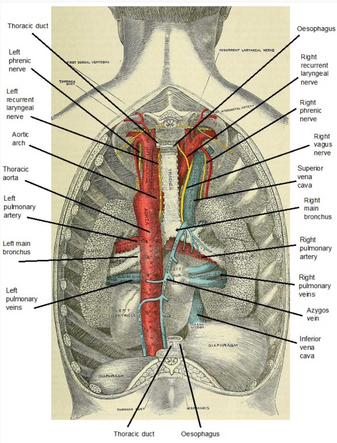


Modified by FRCEM Success. Original by Gray, Henry, 1825-1861; Carter, H. V. (Henry Vandyke), 1831-1897; Pick, T. Pickering (Thomas Pickering), 1841-1919 [No restrictions], via Wikimedia Commons

**Relations**

The medial surface of the right lung lies adjacent to:

- the heart
- the inferior vena cava
- the superior vena cava
- the azygos vein
- the oesophagus

The medial surface of the left lung lies adjacent to:

- the heart
- the aortic arch
- the thoracic aorta
- the oesophagus.

The right and left subclavian arteries and veins arch over and are related to the superior lobe of the right and left lung as they pass over the dome of the cervical pleura and into the axilla.

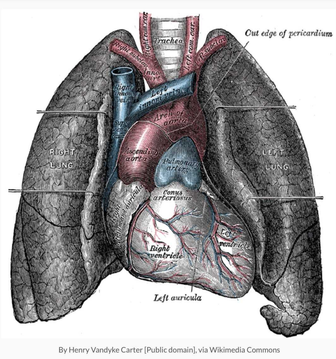


By Henry Vandyke Carter [Public domain], via Wikimedia Commons

**Blood supply**

The right and left pulmonary arteries originate from the pulmonary trunk (at the vertebral level T4/T5) and carry deoxygenated blood to the lungs.

On each side a superior and inferior pulmonary vein carries oxygenated blood from the lungs back to the heart.

The bronchi (down to the terminal bronchioles), lung roots, visceral pleura and supporting lung tissues receive their nutrient blood supply from the bronchial arteries, which arise from the descending aorta.

**Lymphatics**

Lymph from the lungs drains via hilar, tracheobronchial and mediastinal lymph nodes.

**Innervation**

The nerve supply to the lungs is from the anterior and posterior pulmonary plexus (networks of nerves derived from the sympathetic trunk and vagus nerve).

The parasympathetic nerve supply, carried by the vagus nerve, stimulates secretion from the bronchial glands, contraction of bronchial smooth muscle, and vasodilation of the pulmonary vessels. The vagus nerve also carries afferent fibres of pain, cough reflex and stretch of the lung (during inspiration).

The sympathetic nerve supply stimulates relaxation of bronchial smooth muscle, and vasoconstriction of the pulmonary vessels.

< Previous | Next >

Something wrong?

## Question Navigator

1 Answered
2 Answered
3 Answered
4 Answered
5 Answered
6 Answered
7 Answered
8 Answered
9 Answered
10 Answered
11 Answered
12 Answered



©2014 - 2017 FRCEM Success | Website designed & hosted by Cyberfrog Design

FRCEMSuccess

MENU

# Anatomy: Thorax

Question 53 of 134

A 68 year old man presents to ED with sudden onset severe chest pain and is found to suffered a myocardial infarction in the area of the apex of the heart. Occlusion of which of the following blood vessels is most likely responsible:

a Circumflex artery

b Right marginal artery

c Anterior interventricular artery

d Posterior interventricular artery

e Right coronary artery

< Previous | Next > | See Answer

Something wrong?

## Question Navigator

1 Answered
2 Answered
3 Answered
4 Answered
5 Answered
6 Answered
7 Answered
8 Answered
9 Answered
10 Answered
11 Answered
12 Answered



©2014 - 2017 FRCEM Success | Website designed & hosted by Cyberfrog Design

# Anatomy: Thorax

Question 53 of 134

A 68 year old man presents to ED with sudden onset severe chest pain and is found to suffered a myocardial infarction in the area of the apex of the heart. Occlusion of which of the following blood vessels is most likely responsible:

a) Circumflex artery ✗
b) Right marginal artery
c) Anterior interventricular artery ✓
d) Posterior interventricular artery
e) Right coronary artery

## Answer

The apex of the heart is primarily supplied by the anterior interventricular branch of the left coronary artery.

## Notes

The right and left coronary arteries arise from the right and left aortic sinuses in the initial portion of the ascending aorta and supply the muscle and other tissues of the heart.

| Artery | Territory of supply |
|---|---|
| Right coronary artery | Right atrium and ventricle, sinoatrial node, atrioventricular node |
| Right marginal branch | Inferior aspect of right ventricle |
| Posterior interventricular branch | Posterior aspect of right and left ventricles, posterior one-third of interventricular septum |
| Left coronary artery | Via main branches below |
| Anterior interventricular branch | Right and left ventricles, anterior two-thirds of interventricular septum |
| Left circumflex branch | Left atrium and left ventricle |

**Territories of supply**

Although there is variation, in most people the territories of supply are as follows:

The right coronary artery supplies:

- the right atrium
- most of the right ventricle
- the sinoatrial and atrioventricular nodes
- the interatrial septum
- a portion of the left atrium
- the posteroinferior one-third of the interventricular septum
- a portion of the posterior part of the left ventricle

The left coronary artery supplies:

- most of the left atrium
- most of the left ventricle
- a portion of the right ventricle
- most of the interventricular septum (including the atrioventricular bundle and branches)

**Branches**

The right coronary artery supplies the right atrium, the sinoatrial node and the atrioventricular node (via the SA and AV nodal branches) and gives rise to two principal branches:

- the right marginal branch (supplying the inferior margin of the right ventricle and the apex)
- the posterior interventricular branch (supplying the posterior aspect of the right and left ventricles and the posterior one-third of the interventricular septum).

The left coronary artery gives rise to two principal branches:

- the anterior interventricular branch (supplying the right and left ventricles, the apex and the anterior two-thirds of the interventricular septum)
- the circumflex branch (supplying the left atrium and left ventricle).

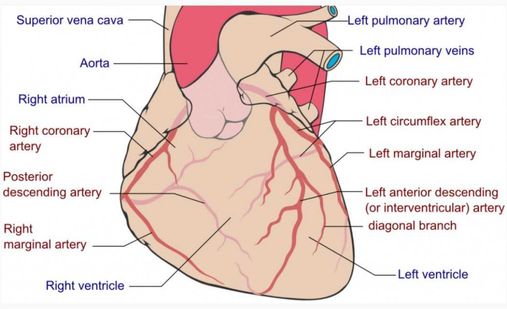


By Coronary.pdf: Patrick J. Lynch, medical illustrator derivative work: Fred the Oyster (talk) adaption and further labeling: Mikael Häggström (Coronary.pdf) [CC BY-SA 3.0 (http://creativecommons.org/licenses/by-sa/3.0)], via Wikimedia Commons

< Previous | Next > | Something wrong?

## Question Navigator

1 Answered
2 Answered
3 Answered
4 Answered
5 Answered
6 Answered
7 Answered
8 Answered
9 Answered
10 Answered
11 Answered
12 Answered



©2014 - 2017 FRCEM Success | Website designed & hosted by Cyberfrog Design

# Anatomy: Thorax

Question 54 of 134

## Which of the following best describes the territory of supply of the anterior interventricular artery:

a Anterior aspect of right atrium and ventricle

b Anterior aspect of left atrium and ventricle

c Left and right ventricles and anterior interventricular septum

d Anterior interventricular septum and left atrium

e Anterior interventricular septum, atrioventricular node and left ventricle

< Previous | Next > | See Answer

Something wrong?

Question Navigator

1 Answered
2 Answered
3 Answered
4 Answered
5 Answered
6 Answered
7 Answered
8 Answered
9 Answered
10 Answered
11 Answered
12 Answered



©2014 - 2017 FRCEM Success | Website designed & hosted by Cyberfrog Design

# Anatomy: Thorax

Question 54 of 134

Which of the following best describes the territory of supply of the anterior interventricular artery:

a) Anterior aspect of right atrium and ventricle
b) Anterior aspect of left atrium and ventricle
c) **Left and right ventricles and anterior interventricular septum** ✔
d) Anterior interventricular septum and left atrium
e) Anterior interventricular septum, atrioventricular node and left ventricle

## Answer

The anterior interventricular artery supplies the anterior aspect of the right ventricle, the anterior and lateral aspect of the left ventricle and the anterior two-thirds of the interventricular septum.

## Notes

The right and left coronary arteries arise from the right and left aortic sinuses in the initial portion of the ascending aorta and supply the muscle and other tissues of the heart.

| Artery | Territory of supply |
|---|---|
| Right coronary artery | Right atrium and ventricle, sinoatrial node, atrioventricular node |
| Right marginal branch | Inferior aspect of right ventricle |
| Posterior interventricular branch | Posterior aspect of right and left ventricles, posterior one-third of interventricular septum |
| Left coronary artery | Via main branches below |
| Anterior interventricular branch | Right and left ventricles, anterior two-thirds of interventricular septum |
| Left circumflex branch | Left atrium and left ventricle |

**Territories of supply**

Although there is variation, in most people the territories of supply are as follows:

The right coronary artery supplies:

- the right atrium
- most of the right ventricle
- the sinoatrial and atrioventricular nodes
- the interatrial septum
- a portion of the left atrium
- the posteroinferior one-third of the interventricular septum
- a portion of the posterior part of the left ventricle

The left coronary artery supplies:

- most of the left atrium
- most of the left ventricle
- a portion of the right ventricle
- most of the interventricular septum (including the atrioventricular bundle and branches)

**Branches**

The right coronary artery supplies the right atrium, the sinoatrial node and the atrioventricular node (via the SA and AV nodal branches) and gives rise to two principal branches:

- the right marginal branch (supplying the inferior margin of the right ventricle and the apex)
- the posterior interventricular branch (supplying the posterior aspect of the right and left ventricles and the posterior one-third of the interventricular septum).

The left coronary artery gives rise to two principal branches:

- the anterior interventricular branch (supplying the right and left ventricles, the apex and the anterior two-thirds of the interventricular septum)
- the circumflex branch (supplying the left atrium and left ventricle).

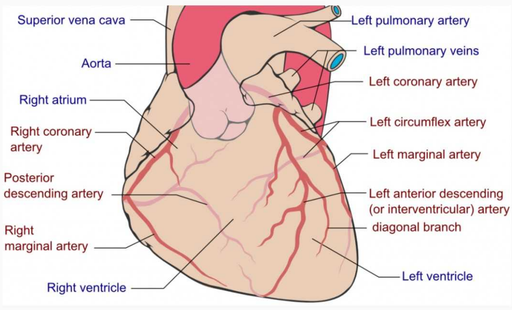


By Coronary.pdf: Patrick J. Lynch, medical illustrator derivative work: Fred the Oyster (talk) adaption and further labeling: Mikael Häggström (Coronary.pdf) [CC BY-SA 3.0 (http://creativecommons.org/licenses/by-sa/3.0)], via Wikimedia Commons

< Previous | Next >

Something wrong?

## Question Navigator

1 Answered
2 Answered
3 Answered
4 Answered
5 Answered
6 Answered
7 Answered
8 Answered
9 Answered
10 Answered
11 Answered
12 Answered



©2014 - 2017 FRCEM Success | Website designed & hosted by Cyberfrog Design

# Anatomy: Thorax

Question 55 of 134

## Which of the following muscles is least likely to be involved in forceful expiration:

a Innermost intercostal muscles

b Internal intercostal muscles

c External intercostal muscles

d Transversus thoracis

e Transversus abdominis

< Previous | Next > | See Answer

Something wrong?

Question Navigator

1 Answered
2 Answered
3 Answered
4 Answered
5 Answered
6 Answered
7 Answered
8 Answered
9 Answered
10 Answered
11 Answered
12 Answered



©2014 - 2017 FRCEM Success | Website designed & hosted by Cyberfrog Design

# Anatomy: Thorax

Question 55 of 134

Which of the following muscles is least likely to be involved in forceful expiration:

a) Innermost intercostal muscles
b) Internal intercostal muscles
c) **External intercostal muscles** ✔
d) Transversus thoracis
e) Transversus abdominis

## Answer

Forceful expiration is primarily produced by the deeper thoracic muscles (internal and innermost intercostal muscles, subcostals and transversus thoracis) aided by contraction of the abdominal wall muscles which increase intra-abdominal pressure thus further reducing the volume of the thorax.

## Notes

**Thoracic wall movements**

Movement of the ribs at the costovertebral joints in respiration results in the 'pump handle' and 'bucket handle' movements:

- Because the anterior ends of the ribs are inferior to the posterior ends, when the ribs are elevated, the anterior end moves upwards and forwards, moving the sternum upwards and forwards in turn. This 'pump handle' upwards and forwards movement changes the anteroposterior (AP) dimension of the thorax.
- Because the shafts of the ribs are lower than either the anterior or posterior end, elevation of the ribs also moves the shafts laterally. This 'bucket handle' upwards and lateral movement increases the lateral dimensions of the thorax.

Reversal of these movements i.e. depression of the ribs, will reduce the anteroposterior and transverse dimensions of the thorax.

**Inspiration**

In inspiration, elevation of the sternal ends of the ribs ('pump handle' movement), elevation of the lateral shafts of the ribs ('bucket handle' movement) and depression of the diaphragm result in expansion of the thorax in an anteroposterior, transverse and vertical direction respectively. This results in an increased intrathoracic volume and decreased intrathoracic pressure and thus air is drawn into the lungs.

Passive inspiration is produced by contraction of the diaphragm (depressing the diaphragm) and the external intercostal muscles (elevating the ribs).

The accessory respiratory muscles (including the sternocleidomastoid, the scalene muscles and the serratus anterior amongst others) aid in forceful inspiration.

**Expiration**

In expiration, depression of the ribs and elevation of the diaphragm result in a reduction of the thorax in an anteroposterior, transverse and vertical direction. This results in a decreased intrathoracic volume and increased intrathoracic pressure and thus air is forced out of the lungs.

Passive expiration is produced primarily by relaxation of the inspiratory muscles (diaphragm and external intercostal muscles) and the elastic recoil of the lungs.

Forceful expiration is primarily produced by the deeper thoracic muscles (internal and innermost intercostal muscles, subcostals and transversus thoracis) aided by contraction of the abdominal wall muscles which increase intra-abdominal pressure thus further reducing the volume of the thorax.

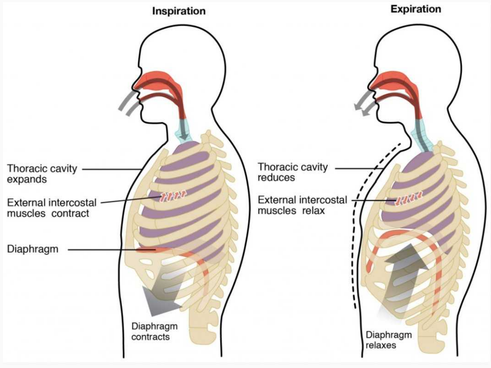


By OpenStax College [CC BY 3.0 (http://creativecommons.org/licenses/by/3.0)], via Wikimedia Commons

**Paradoxical respiration**

Normally as the diaphragm moves downwards in respiration, the abdominal wall moves outwards (together with the chest wall), and the reverse occurs in expiration.

In complete airway obstruction, the diaphragm will move down and the abdominal wall out but as inspiratory effort continues against a closed airway, increasing intrathoracic pressure will draw the chest wall paradoxically inwards (against the opposing action of the intercostal muscles). To the observer, in inspiration there is abdominal expansion with chest collapse and during expiration the reverse is seen. As inspiratory effort increases and expiration becomes active, the see-sawing pattern becomes more pronounced.

Flail chest is a loss of stability of the thoracic cage that occurs when a segment of the anterior or lateral thoracic wall moves freely because of multiple rib fractures, allowing the loose segment to move paradoxically inward on inspiration and outward on expiration. If a large enough segment of the chest is affected, ventilation is impaired.

< Previous | Next >

Something wrong?

## Question Navigator

1 Answered
2 Answered
3 Answered
4 Answered
5 Answered
6 Answered
7 Answered
8 Answered
9 Answered
10 Answered
11 Answered
12 Answered



©2014 - 2017 FRCEM Success | Website designed & hosted by Cyberfrog Design

# Anatomy: Thorax

Question 56 of 134

## In most people, the atrioventricular node is supplied by which of the following coronary vessels:

a Right coronary artery

b Left circumflex branch

c Posterior interventricular branch

d Anterior interventricular branch

e Left coronary artery

< Previous | Next > | See Answer

Something wrong?

Question Navigator

1 Answered
2 Answered
3 Answered
4 Answered
5 Answered
6 Answered
7 Answered
8 Answered
9 Answered
10 Answered
11 Answered
12 Answered



©2014 - 2017 FRCEM Success | Website designed & hosted by Cyberfrog Design

# Anatomy: Thorax

Question 56 of 134

In most people, the atrioventricular node is supplied by which of the following coronary vessels:

**a)** **Right coronary artery** ✔
**b)** Left circumflex branch
**c)** Posterior interventricular branch
**d)** Anterior interventricular branch
**e)** Left coronary artery

## Answer

The atrioventricular node is usually supplied by the AV nodal branch of the right coronary artery.

## Notes

The right and left coronary arteries arise from the right and left aortic sinuses in the initial portion of the ascending aorta and supply the muscle and other tissues of the heart.

| Artery | Territory of supply |
|---|---|
| Right coronary artery | Right atrium and ventricle, sinoatrial node, atrioventricular node |
| Right marginal branch | Inferior aspect of right ventricle |
| Posterior interventricular branch | Posterior aspect of right and left ventricles, posterior one-third of interventricular septum |
| Left coronary artery | Via main branches below |
| Anterior interventricular branch | Right and left ventricles, anterior two-thirds of interventricular septum |
| Left circumflex branch | Left atrium and left ventricle |

**Territories of supply**

Although there is variation, in most people the territories of supply are as follows:

The right coronary artery supplies:

- the right atrium
- most of the right ventricle
- the sinoatrial and atrioventricular nodes
- the interatrial septum
- a portion of the left atrium
- the posteroinferior one-third of the interventricular septum
- a portion of the posterior part of the left ventricle

The left coronary artery supplies:

- most of the left atrium
- most of the left ventricle
- a portion of the right ventricle
- most of the interventricular septum (including the atrioventricular bundle and branches)

**Branches**

The right coronary artery supplies the right atrium, the sinoatrial node and the atrioventricular node (via the SA and AV nodal branches) and gives rise to two principal branches:

- the right marginal branch (supplying the inferior margin of the right ventricle and the apex)
- the posterior interventricular branch (supplying the posterior aspect of the right and left ventricles and the posterior one-third of the interventricular septum).

The left coronary artery gives rise to two principal branches:

- the anterior interventricular branch (supplying the right and left ventricles, the apex and the anterior two-thirds of the interventricular septum)
- the circumflex branch (supplying the left atrium and left ventricle).

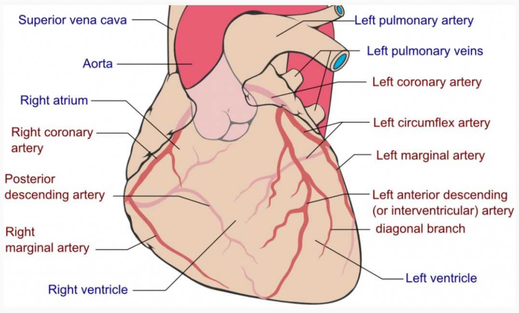


By Coronary.pdf: Patrick J. Lynch, medical illustrator derivative work: Fred the Oyster (talk) adaption and further labeling: Mikael Häggström (Coronary.pdf) [CC BY-SA 3.0 (http://creativecommons.org/licenses/by-sa/3.0)], via Wikimedia Commons

< Previous | Next > | Something wrong?

## Question Navigator

1 Answered
2 Answered
3 Answered
4 Answered
5 Answered
6 Answered
7 Answered
8 Answered
9 Answered
10 Answered
11 Answered
12 Answered



©2014 - 2017 FRCEM Success | Website designed & hosted by Cyberfrog Design

# Anatomy: Thorax

Question 57 of 134

## Posteriorly the inferior margin of the pleural cavity is at which of the following vertebral levels:

a T9

b T10

c T11

d T12

e L1

< Previous | Next > | See Answer

Something wrong?

Question Navigator

1 Answered
2 Answered
3 Answered
4 Answered
5 Answered
6 Answered
7 Answered
8 Answered
9 Answered
10 Answered
11 Answered
12 Answered



©2014 - 2017 FRCEM Success | Website designed & hosted by Cyberfrog Design

# Anatomy: Thorax

Question 57 of 134

Posteriorly the inferior margin of the pleural cavity is at which of the following vertebral levels:

**a)** T9
**b)** T10
**c)** T11
**d)** **T12** ✔
**e)** L1

## Answer

The inferior margin of the pleural cavity is a line that runs between rib 8 in the midclavicular line, rib 10 in the midaxillary line and vertebra T12 posteriorly. The inferior margin of the lung in quiet respiration is a line that runs between rib 6 in the midclavicular line, rib 8 in the midaxillary line and vertebra T10 posteriorly.

## Notes

Each lung is surrounded by a pleura. The pleura consists of two parts, the parietal pleura (which lines the thoracic cavity) and the visceral pleura (which lines the lungs). The two parts of the pleura are continuous with each other at the hilum of each lung. The potential space between these two parts of the pleura is called the pleural cavity.

**Pleural cavity**

The pleural cavity normally contains a small amount of lubricating fluid to allow the visceral pleura attached to the lungs to smoothly slide over the parietal pleura attached to the thoracic wall during respiration. The serous fluid also produces a surface tension, pulling the parietal and visceral pleura together. This ensures that when the thorax expands, the lung also expands, filling with air.

**Innervation**

The parietal pleura is innervated by somatic afferent fibres. The costal pleura (pleura related to the ribs and intercostal spaces) is innervated by branches of the intercostal nerves, and pain is felt in relation to the thoracic wall. The diaphragmatic pleura (covering the diaphragm) and the mediastinal pleura (covering the mediastinum) are innervated mainly by the phrenic nerves (C3 – C5), and pain is referred the the C3 – C5 dermatomes (lateral neck and supraclavicular region of shoulder).

Although the visceral pleura is innervated by visceral afferent fibres, pain is not generally elicited from this tissue.

**Surface markings**

Superiorly the pleural cavity projects as much as 3 – 4 cm above the first costal cartilage but does not extend above the neck of rib 1.

Anteriorly the pleurae approach each other posterior to the upper part of the sternum. At the lower part of the sternum the left pleura does not come as close to the midline as the right pleura because the middle mediastinum bulges to the left.

Inferiorly the pleura reflects onto the diaphragm above the costal margin. The inferior margin of the pleural cavity is a line that runs between rib 8 in the midclavicular line, rib 10 in the midaxillary line and vertebra T12 posteriorly.

The inferior margin of the lung in quiet respiration is a line that runs between rib 6 in the midclavicular line, rib 8 in the midaxillary line and vertebra T10 posteriorly.

The lungs therefore do not completely fill the pleural cavities, producing two pleural recesses, the costomediastinal and costodiaphragmatic recesses, in which fluids can collect.

The costomediastinal recess occurs on each side where the the costal pleura is opposed to mediastinal pleura, particularly on the left side in the region overlying the heart.

The costodiaphragmatic recess occurs between the costal and diaphragmatic pleura. It is the region between the inferior margin of the lung and the inferior margin of the pleural cavity and is clinically important for pleural aspiration.

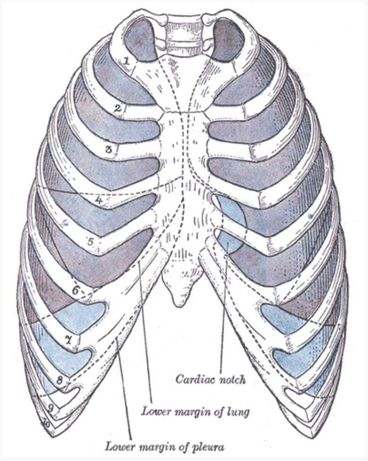


By Henry Vandyke Carter [Public domain], via Wikimedia Commons

< Previous | Next >

Something wrong?

## Question Navigator

1 Answered
2 Answered
3 Answered
4 Answered
5 Answered
6 Answered
7 Answered
8 Answered
9 Answered
10 Answered
11 Answered
12 Answered



©2014 - 2017 FRCEM Success | Website designed & hosted by Cyberfrog Design

# Anatomy: Thorax

Question 58 of 134

## The oesophagus begins at which vertebral level:

a C4

b C5

c C6

d C7

e T1

< Previous | Next > | See Answer

Something wrong?

## Question Navigator

1 Answered
2 Answered
3 Answered
4 Answered
5 Answered
6 Answered
7 Answered
8 Answered
9 Answered
10 Answered
11 Answered
12 Answered



©2014 - 2017 FRCEM Success | Website designed & hosted by Cyberfrog Design

# Anatomy: Thorax

Question 58 of 134

The oesophagus begins at which vertebral level:

**a)** C4
**b)** C5
**c)** C6 ✔
**d)** C7
**e)** T1

## Answer

The oesophagus begins at the inferior border of the cricoid cartilage opposite vertebra C6, pierces the diaphragm at the esophageal hiatus at T10 and ends at the cardiac opening of the stomach opposite vertebra T11.

## Notes

### Anatomical extent

The oesophagus is a muscular tube passing between the pharynx in the neck and the stomach in the abdomen. The oesophagus begins at the inferior border of the cricoid cartilage opposite vertebra C6, pierces the diaphragm at the esophageal hiatus at T10 and ends at the cardiac opening of the stomach opposite vertebra T11.

### Structure

The oesophagus consists of an internal circular and external longitudinal layer of muscle. The external longitudinal layer is comprised of different muscle types in each third of the oesophagus; superior third – voluntary striated muscle, middle third – voluntary striated and smooth muscle and inferior third – smooth muscle.

### Relations

The oesophagus descends on the anterior aspect of the bodies of the vertebrae, immediately posterior to the trachea and the recurrent laryngeal nerves, generally in the midline position. The oesophagus is crossed anteriorly by the aortic arch. As it approaches the diaphragm, the oesophagus moves anteriorly and to the left, crossing from the right side of the thoracic aorta to eventually assume a position anterior to it, before passing through the diaphragm.

Posterior to the oesophagus, the thoracic duct is on the right side inferiorly but crosses to the left more superiorly (at T5). Other structures posteriorly include portions of the hemiazygos veins and the right posterior intercostal vessels.

Anterior to the oesophagus below the tracheal bifurcation are the right pulmonary artery and the left main bronchus. The oesophagus then passes immediately posterior to the left atrium, separated from it only by pericardium. Inferior to the left atrium, the oesophagus is related to the diaphragm.

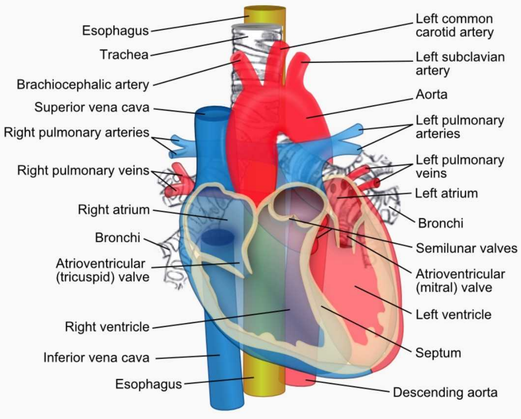


ZooFari [CC BY-SA 3.0 (http://creativecommons.org/licenses/by-sa/3.0)], via Wikimedia Commons

### Points of constriction

As the oesophagus is a flexible muscular tube, it is compressed by surrounding structures at four locations:

- 1) the junction of the oesophagus with the pharynx in the neck (upper oesophageal sphincter formed by the cricopharyngeus muscle)
- 2) in the superior mediastinum where the oesophagus is crossed by the arch of the aorta
- 3) in the posterior mediastinum where the oesophagus is compressed by the left main bronchus
- 4) in the posterior mediastinum at the oesophageal hiatus in the diaphragm.

Clinically these compressions are important when passing instruments or assessing swallowed objects.

### Innervation

Oesophageal innervation is complex, oesophageal branches arise from the vagus nerves and sympathetic trunks. The visceral afferents that pass through the sympathetic trunks and the splanchnic nerves are the primary participants in detection of oesophageal pain and transmission of this information to various levels of the central nervous system.

< Previous | Next >

Something wrong?

## Question Navigator

1 Answered
2 Answered
3 Answered
4 Answered
5 Answered
6 Answered
7 Answered
8 Answered
9 Answered
10 Answered
11 Answered
12 Answered



©2014 - 2017 FRCEM Success | Website designed & hosted by Cyberfrog Design

# Anatomy: Thorax

Question 59 of 134

## In quiet respiration, the position of the right oblique fissure can be marked by a line on the thoracic wall that:

a Begins at the spinous process of T4, crosses the fifth intercostal space laterally and follows the contour of rib 6 anteriorly.

b Begins at the spinous process of T3, crosses the fourth intercostal space laterally and follows the contour of rib 6 anteriorly.

c Begins at the spinous process of T5, crosses the fifth intercostal space laterally and follows the contour of rib 5 anteriorly.

d Begins at the spinous process of T3, crosses the fifth intercostal space laterally and follows the contour of rib 5 anteriorly.

e Begins at the spinous process of T6, crosses the fifth intercostal space laterally and follows the contour of rib 7 anteriorly.

< Previous | Next > | See Answer

Something wrong?

Question Navigator

1 Answered
2 Answered
3 Answered
4 Answered
5 Answered
6 Answered
7 Answered
8 Answered
9 Answered
10 Answered
11 Answered
12 Answered



©2014 - 2017 FRCEM Success | Website designed & hosted by Cyberfrog Design

# Anatomy: Thorax

Question 59 of 134

In quiet respiration, the position of the right oblique fissure can be marked by a line on the thoracic wall that:

**a)**
Begins at the spinous process of T4, crosses the fifth intercostal space laterally and follows the contour of rib 6 anteriorly.

**b)**
Begins at the spinous process of T3, crosses the fourth intercostal space laterally and follows the contour of rib 6 anteriorly.

**c)**
Begins at the spinous process of T5, crosses the fifth intercostal space laterally and follows the contour of rib 5 anteriorly.

**d)**
Begins at the spinous process of T3, crosses the fifth intercostal space laterally and follows the contour of rib 5 anteriorly.

**e)**
**Begins at the spinous process of T6, crosses the fifth intercostal space laterally and follows the contour of rib 7 anteriorly.**

## Answer

In quiet respiration, the approximate position of the right oblique fissure can be marked by a line on the thoracic wall that begins at the spinous process of vertebra T4, crosses the fifth intercostal space laterally and then follows the contour of rib 6 anteriorly.

## Notes

The lungs lie on either side of the mediastinum, each surrounded by a pleural cavity. The right lung is normally a little larger than the left lung because the middle mediastinum, containing the heart, bulges more to the left than to the right.

**Lobes and fissures**

The right lung has three lobes and two fissures; the oblique fissure separates the inferior lobe from the superior and middle lobe whilst the horizontal fissure separates the superior lobe from the middle lobe.

The left lung has two lobes separated by the oblique fissure.

The oblique fissure may be an evolutionary development to permit greater transmission of diaphragmatic excursions to the superior lobe. In this way the upper lobe can expand to a relatively greater extent for a given increase in the superoinferior diameter of the pleural cavity.

**Surface marking**

The inferior margin of the lung in quiet respiration is a line that runs between rib 6 in the midclavicular line, rib 8 in the midaxillary line and vertebra T10 posteriorly.

In quiet respiration, the approximate position of the right oblique fissure can be marked by a line on the thoracic wall that begins at the spinous process of vertebra T4, crosses the fifth intercostal space laterally and then follows the contour of rib 6 anteriorly. The horizontal fissure follows the fourth intercostal space from the sternum until it meets the oblique fissure as it crosses rib 5.

The oblique fissure in the left lung is slightly more oblique than the corresponding fissure in the right lung. In quiet respiration, the approximate position of the oblique fissure can be marked by a line on the thoracic wall that begins between the spinous processes of vertebrae T3 and T4, crosses the fifth intercostal space laterally and then follows the contour of rib 6 anteriorly.

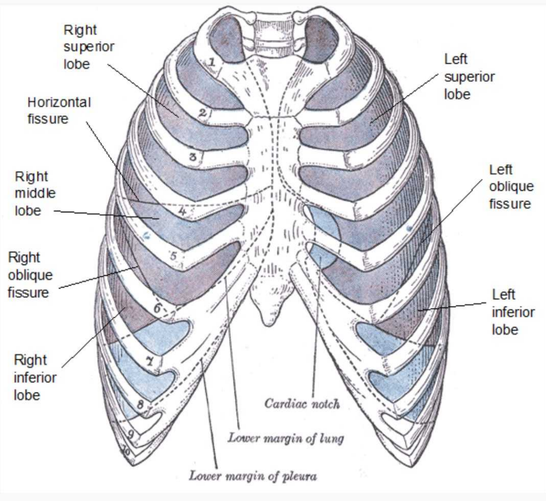


Modified by FRCEM Success. Original by Henry Vandyke Carter [Public domain], via Wikimedia Commons

< Previous | Next > | Something wrong?

## Question Navigator

1 Answered
2 Answered
3 Answered
4 Answered
5 Answered
6 Answered
7 Answered
8 Answered
9 Answered
10 Answered
11 Answered
12 Answered



©2014 - 2017 FRCEM Success | Website designed & hosted by Cyberfrog Design

# Anatomy: Thorax

Question 60 of 134

## The pulmonary trunk arises from the conus arteriosus of the right ventricle at which of the following locations:

a Posterior to the left third costal cartilage

b Posterior to the right third costal cartilage

c Posterior to the left second costal cartilage

d Posterior to the right second costal cartilage

e Posterior to the left second intercostal space

< Previous | Next > | See Answer

Something wrong?

Question Navigator

1 Answered
2 Answered
3 Answered
4 Answered
5 Answered
6 Answered
7 Answered
8 Answered
9 Answered
10 Answered
11 Answered
12 Answered



©2014 - 2017 FRCEM Success | Website designed & hosted by Cyberfrog Design

# Anatomy: Thorax

Question 60 of 134

The pulmonary trunk arises from the conus arteriosus of the right ventricle at which of the following locations:

a) **Posterior to the left third costal cartilage** ✔
b) Posterior to the right third costal cartilage
c) Posterior to the left second costal cartilage
d) Posterior to the right second costal cartilage
e) Posterior to the left second intercostal space

## Answer

The pulmonary trunk arises from the conus arteriosus of the right ventricle slightly anterior to the aortic orifice, posterior to the left third costal cartilage.

## Notes

The ascending aorta arises from the aortic orifice at the base of the left ventricle, at the level of the lower edge of the third left costal cartilage, posterior to the left half of the sternum. The ascending aorta ascends, moving slightly forwards and to the right, before continuing as the arch of the aorta posterior to the second right costal cartilage.

The pulmonary trunk arises from the conus arteriosus of the right ventricle slightly anterior to the aortic orifice, posterior to the left third costal cartilage. The pulmonary trunk ascends, moving posteriorly and to the left, lying initially anterior and then to the left of the ascending aorta, before bifurcating into the right and left pulmonary arteries posterior to the left second intercostal space.

The pulmonary trunk and the ascending aorta are contained within the pericardial sac, lined by serous pericardium and within a common sheath.

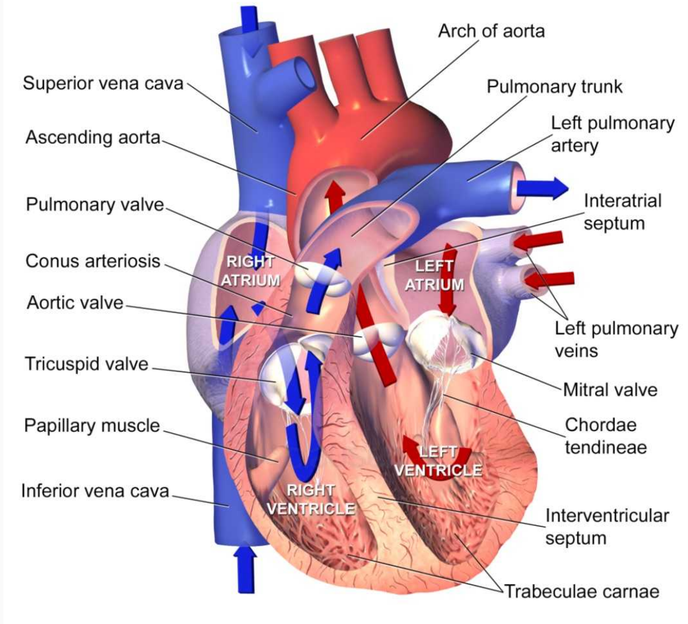


**Sectional Anatomy of the Heart**

By Blausen Medical Communications, Inc. [CC BY 3.0 (http://creativecommons.org/licenses/by/3.0)], via Wikimedia Commons

< Previous | Next > | Something wrong?

## Question Navigator

1 Answered
2 Answered
3 Answered
4 Answered
5 Answered
6 Answered
7 Answered
8 Answered
9 Answered
10 Answered
11 Answered
12 Answered



©2014 - 2017 FRCEM Success | Website designed & hosted by Cyberfrog Design

# Anatomy: Thorax

Question 61 of 134

## Which one of the following ribs is not classed as 'atypical':

a 1

b 2

c 3

d 11

e 12

< Previous | Next > | See Answer

Something wrong?

## Question Navigator

1 Answered
2 Answered
3 Answered
4 Answered
5 Answered
6 Answered
7 Answered
8 Answered
9 Answered
10 Answered
11 Answered
12 Answered



©2014 - 2017 FRCEM Success | Website designed & hosted by Cyberfrog Design

# Anatomy: Thorax

Question 61 of 134

Which one of the following ribs is not classed as 'atypical':

**a)** 1
**b)** 2
**c)** 3 ✔
**d)** 11
**e)** 12

## Answer

The atypical ribs consist of ribs 1, 2, 10, 11 and 12. Rib 3 is a typical rib.

## Notes

There are twelve pairs of ribs, each terminating anteriorly in a costal cartilage.

**True and False ribs**

The ribs are divided into 'true' and 'false' ribs based on their anterior attachments:

- The true ribs (1 – 7) attach directly to the sternum anteriorly.
- The false ribs (8 – 12) can be further divided into those that attach to the costal cartilage of the rib above them (8 – 10) and the floating ribs (11 + 12) that do not have any anterior attachments.

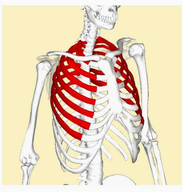

By Anatomography (en:Anatomography (setting page of this image)) [CC BY-SA 2.1 jp (http://creativecommons.org/licenses/by-sa/2.1/jp/deed.en)], via Wikimedia Commons

By Anatomography (en:Anatomography (setting page of this image)) [CC BY-SA 2.1 jp (http://creativecommons.org/licenses/by-sa/2.1/jp/deed.en)], via Wikimedia Commons

**Thoracic vertebrae**

Posteriorly, all of the ribs articulate with the thoracic vertebrae of the spine.

Each typical rib forms two joints posteriorly:

- the costotransverse joint (between the tubercle of the rib and the transverse process of the corresponding vertebra)
- the costovertebral joint (between the two facets on the head of the rib and the superior costal facet on the body of the corresponding vertebra, and the inferior costal facet on the body of the vertebra above).

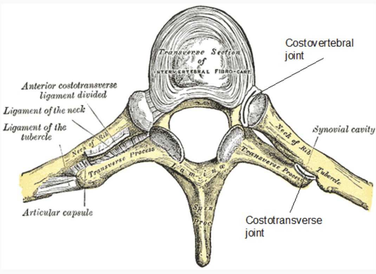


Modified by FRCEM Success. Original by Henry Vandyke Carter [Public domain], via Wikimedia Commons

**Typical ribs**

The typical rib consists of a head, a neck and a body:

- The head of the rib has two articular facets which articulate with the superior costal facet on the body of the corresponding vertebra, and the inferior costal facet on the body of the vertebra above.
- The neck of the rib connects the head to the body. Where the neck meets the body, there is a tubercle which articulates with the transverse process of the corresponding vertebra.
- The body of the rib is flat and curved.

The inferior margin of the internal surface of the body is marked by the costal groove which protects the neurovascular structures which run within it.

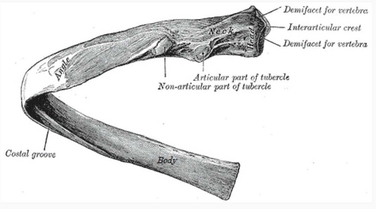


Modified by FRCEM Success. Original by Henry Vandyke Carter [Public domain], via Wikimedia Commons

**Atypical ribs**

The atypical ribs consist of ribs 1, 2, 10, 11 and 12.

| Atypical rib | Features |
|---|---|
| Rib 1 | Shorter and wider, single facet for articulation with T1, scalene tubercle |
| Rib 2 | Flat, roughened area for attachment of serratus anterior muscle |
| Rib 10 | Single facet for articulation with T10 |
| Rib 11 | No neck, single facet for articulation with T11 |
| Rib 12 | No neck, single facet for articulation with T12 |

- Rib 1 is shorter and wider than the other ribs. The head of rib 1 has only one facet for articulation with the body of its own vertebra (T1); it does NOT articulate with vertebra C7. The superior surface of rib 1 is characterised by the scalene tubercle about midway along the body, which separates two smooth grooves in the rib made by the subclavian vein anteriorly and the subclavian artery posteriorly.
- Like rib 1, rib 2 is flat but twice as long. It has a roughened area on its upper surface where the serratus anterior muscle attaches.
- The head of rib 10 only has a single facet for articulation with the body of its own vertebra (T10).
- Ribs 11 and 12 have no neck, and have only one facet for articulation with the bodies of their own vertebrae (T11 and T12).

< Previous | Next >

Something wrong?

## Question Navigator

1 Answered
2 Answered
3 Answered
4 Answered
5 Answered
6 Answered
7 Answered
8 Answered
9 Answered
10 Answered
11 Answered
12 Answered



©2014 - 2017 FRCEM Success | Website designed & hosted by Cyberfrog Design

# Anatomy: Thorax

Question 62 of 134

A 21 year old is brought to ED following a head-on collision with a tree in which he received severe blunt trauma to his sternum from the steering wheel. Which part of the heart would most likely be injured by the impact:

a Left atrium

b Left ventricle

c Right atrium

d Apex

e Right ventricle

< Previous | Next > | See Answer

Something wrong?

## Question Navigator

1 Answered
2 Answered
3 Answered
4 Answered
5 Answered
6 Answered
7 Answered
8 Answered
9 Answered
10 Answered
11 Answered
12 Answered



©2014 - 2017 FRCEM Success | Website designed & hosted by Cyberfrog Design

# Anatomy: Thorax

Question 62 of 134

A 21 year old is brought to ED following a head-on collision with a tree in which he received severe blunt trauma to his sternum from the steering wheel. Which part of the heart would most likely be injured by the impact:

**a)** Left atrium
**b)** Left ventricle
**c)** Right atrium
**d)** Apex
**e)** **Right ventricle** ✔

## Answer

The anterior surface of the heart consists mostly of the right ventricle, with some of the right atrium and some of the left ventricle. The right ventricle is positioned posterior to the sternum. The right atrium is located on the right lateral side of the heart. The apex of the heart is positioned anteriorly but located to the left of the sternum. The left ventricle is positioned on the left lateral side and slightly posterior position in the thorax. The left atrium is mostly positioned posteriorly in the thorax.

## Notes

| Border/Surface | Main structure (contributing structures) |
|---|---|
| Apex | Left ventricle |
| Base | Left atrium (right atrium, proximal great veins) |
| Anterior surface | Right ventricle (right atrium, left ventricle) |
| Inferior surface | Left and right ventricle |
| Left pulmonary surface | Left ventricle (left atrium) |
| Right pulmonary surface | Right atrium |
| Inferior border | Right ventricle (left ventricle) |
| Left border | Left ventricle (left auricle) |
| Right border | Right atrium |
| Superior border | Both atria, roots of great vessels |

The general shape and orientation of the heart are that of a pyramid that has fallen over and is resting on one of its sides.

- The apex of this pyramid projects forwards, downwards and to the left. The apex is formed by the inferolateral part of the left ventricle and is positioned deep to the left fifth intercostal space in the midclavicular line.
- The base is facing posteriorly. The base is formed mostly by the left atrium with a small portion of the right atrium and the proximal part of the great veins, and is fixed posteriorly to the pericardial wall, opposite the bodies of the T5 – T8 vertebrae (T6 – T9 when standing). The oesophagus lies immediately posterior to the base.

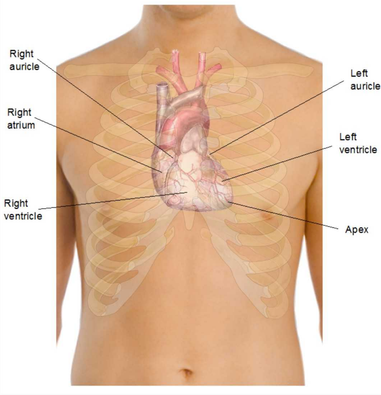


Modified by FRCEM Success. Original by Mikael Häggström (See above. All used images are in public domain.) [Public domain], via Wikimedia Commons

Surfaces

There are four surfaces to the upturned pyramid:

- The anterior (sternocostal) surface consists mostly of the right ventricle with some of the right atrium and some of the left ventricle.
- The inferior (diaphragmatic) surface consists of the left ventricle with a small portion of the right ventricle separated by the posterior interventricular groove.
- The left pulmonary surface consists mainly of the left ventricle and a portion of the left atrium.
- The right pulmonary surface consists of the right atrium.

Borders

There are four main borders separating the surfaces of the heart:

- The inferior border is formed mostly by the right ventricle and a small portion of the left ventricle near the apex.
- The left border is formed mostly by the left ventricle with a small portion of the left auricle.
- The right border is formed by the right atrium.
- The superior border is formed by both atria and the roots of the great vessels.

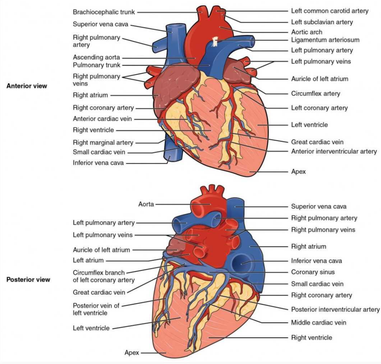


By OpenStax College [CC BY 3.0 (http://creativecommons.org/licenses/by/3.0)], via Wikimedia Commons

< Previous | Next >

Something wrong?

## Question Navigator

1 Answered
2 Answered
3 Answered
4 Answered
5 Answered
6 Answered
7 Answered
8 Answered
9 Answered
10 Answered
11 Answered
12 Answered



©2014 - 2017 FRCEM Success | Website designed & hosted by Cyberfrog Design

# Anatomy: Thorax

Question 63 of 134

## Which of the following occurs primarily to produce passive expiration:

a Contraction of internal and innermost intercostal muscles

b Relaxation of diaphragm and external intercostal muscles

c Contraction of diaphragm and external intercostal muscles

d Contraction of internal intercostal and abdominal muscles

e Relaxation of internal and innermost intercostal muscles

< Previous | Next > | See Answer

Something wrong?

## Question Navigator

1 Answered
2 Answered
3 Answered
4 Answered
5 Answered
6 Answered
7 Answered
8 Answered
9 Answered
10 Answered
11 Answered
12 Answered



©2014 - 2017 FRCEM Success | Website designed & hosted by Cyberfrog Design

# Anatomy: Thorax

Question 63 of 134

Which of the following occurs primarily to produce passive expiration:

a) Contraction of internal and innermost intercostal muscles
b) **Relaxation of diaphragm and external intercostal muscles** ✔
c) Contraction of diaphragm and external intercostal muscles
d) Contraction of internal intercostal and abdominal muscles
e) Relaxation of internal and innermost intercostal muscles

## Answer

Passive expiration is produced primarily by relaxation of the inspiratory muscles (diaphragm and external intercostal muscles) and the elastic recoil of the lungs.

## Notes

**Thoracic wall movements**

Movement of the ribs at the costovertebral joints in respiration results in the 'pump handle' and 'bucket handle' movements:

- Because the anterior ends of the ribs are inferior to the posterior ends, when the ribs are elevated, the anterior end moves upwards and forwards, moving the sternum upwards and forwards in turn. This 'pump handle' upwards and forwards movement changes the anteroposterior (AP) dimension of the thorax.
- Because the shafts of the ribs are lower than either the anterior or posterior end, elevation of the ribs also moves the shafts laterally. This 'bucket handle' upwards and lateral movement increases the lateral dimensions of the thorax.

Reversal of these movements i.e. depression of the ribs, will reduce the anteroposterior and transverse dimensions of the thorax.

**Inspiration**

In inspiration, elevation of the sternal ends of the ribs ('pump handle' movement), elevation of the lateral shafts of the ribs ('bucket handle' movement) and depression of the diaphragm result in expansion of the thorax in an anteroposterior, transverse and vertical direction respectively. This results in an increased intrathoracic volume and decreased intrathoracic pressure and thus air is drawn into the lungs.

Passive inspiration is produced by contraction of the diaphragm (depressing the diaphragm) and the external intercostal muscles (elevating the ribs).

The accessory respiratory muscles (including the sternocleidomastoid, the scalene muscles and the serratus anterior amongst others) aid in forceful inspiration.

**Expiration**

In expiration, depression of the ribs and elevation of the diaphragm result in a reduction of the thorax in an anteroposterior, transverse and vertical direction. This results in a decreased intrathoracic volume and increased intrathoracic pressure and thus air is forced out of the lungs.

Passive expiration is produced primarily by relaxation of the inspiratory muscles (diaphragm and external intercostal muscles) and the elastic recoil of the lungs.

Forceful expiration is primarily produced by the deeper thoracic muscles (internal and innermost intercostal muscles, subcostals and transversus thoracis) aided by contraction of the abdominal wall muscles which increase intra-abdominal pressure thus further reducing the volume of the thorax.

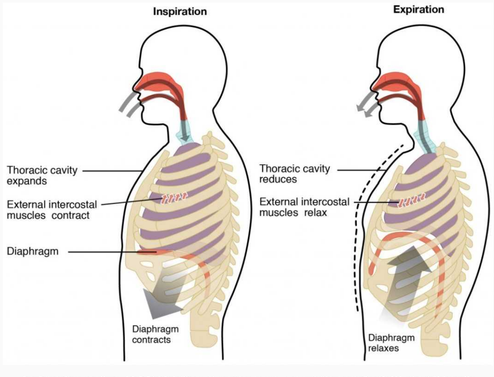


By OpenStax College [CC BY 3.0 (http://creativecommons.org/licenses/by/3.0)], via Wikimedia Commons

**Paradoxical respiration**

Normally as the diaphragm moves downwards in respiration, the abdominal wall moves outwards (together with the chest wall), and the reverse occurs in expiration.

In complete airway obstruction, the diaphragm will move down and the abdominal wall out but as inspiratory effort continues against a closed airway, increasing intrathoracic pressure will draw the chest wall paradoxically inwards (against the opposing action of the intercostal muscles). To the observer, in inspiration there is abdominal expansion with chest collapse and during expiration the reverse is seen. As inspiratory effort increases and expiration becomes active, the see-sawing pattern becomes more pronounced.

Flail chest is a loss of stability of the thoracic cage that occurs when a segment of the anterior or lateral thoracic wall moves freely because of multiple rib fractures, allowing the loose segment to move paradoxically inward on inspiration and outward on expiration. If a large enough segment of the chest is affected, ventilation is impaired.

< Previous | Next >

Something wrong?

## Question Navigator

1 Answered
2 Answered
3 Answered
4 Answered
5 Answered
6 Answered
7 Answered
8 Answered
9 Answered
10 Answered
11 Answered
12 Answered



©2014 - 2017 FRCEM Success | Website designed & hosted by Cyberfrog Design

# Anatomy: Thorax

Question 64 of 134

A 61 year old patient presents to ED with sudden onset central crushing chest pain. ECG demonstrates ischaemic changes and bradycardia with a heart rate of 45 bpm. Which of the following vessels is most likely occluded:

a Left coronary artery

b Right coronary artery

c Left circumflex artery

d Posterior interventricular artery

e Anterior interventricular artery

< Previous | Next > | See Answer

Something wrong?

## Question Navigator

1 Answered
2 Answered
3 Answered
4 Answered
5 Answered
6 Answered
7 Answered
8 Answered
9 Answered
10 Answered
11 Answered
12 Answered



©2014 - 2017 FRCEM Success | Website designed & hosted by Cyberfrog Design

# Anatomy: Thorax

Question 64 of 134

A 61 year old patient presents to ED with sudden onset central crushing chest pain. ECG demonstrates ischaemic changes and bradycardia with a heart rate of 45 bpm. Which of the following vessels is most likely occluded:

a) Left coronary artery
b) **Right coronary artery** ✔
c) Left circumflex artery
d) Posterior interventricular artery
e) Anterior interventricular artery

## Answer

The right coronary artery in the majority of cases supplies the SA and the AV node. Occlusion of the right coronary artery can result in ischaemia of one or both of the nodes, with subsequent bradycardia and/or heart block.

## Notes

The right and left coronary arteries arise from the right and left aortic sinuses in the initial portion of the ascending aorta and supply the muscle and other tissues of the heart.

| Artery | Territory of supply |
|---|---|
| Right coronary artery | Right atrium and ventricle, sinoatrial node, atrioventricular node |
| Right marginal branch | Inferior aspect of right ventricle |
| Posterior interventricular branch | Posterior aspect of right and left ventricles, posterior one-third of interventricular septum |
| Left coronary artery | Via main branches below |
| Anterior interventricular branch | Right and left ventricles, anterior two-thirds of interventricular septum |
| Left circumflex branch | Left atrium and left ventricle |

**Territories of supply**

Although there is variation, in most people the territories of supply are as follows:

The right coronary artery supplies:

- the right atrium
- most of the right ventricle
- the sinoatrial and atrioventricular nodes
- the interatrial septum
- a portion of the left atrium
- the posteroinferior one-third of the interventricular septum
- a portion of the posterior part of the left ventricle

The left coronary artery supplies:

- most of the left atrium
- most of the left ventricle
- a portion of the right ventricle
- most of the interventricular septum (including the atrioventricular bundle and branches)

**Branches**

The right coronary artery supplies the right atrium, the sinoatrial node and the atrioventricular node (via the SA and AV nodal branches) and gives rise to two principal branches:

- the right marginal branch (supplying the inferior margin of the right ventricle and the apex)
- the posterior interventricular branch (supplying the posterior aspect of the right and left ventricles and the posterior one-third of the interventricular septum).

The left coronary artery gives rise to two principal branches:

- the anterior interventricular branch (supplying the right and left ventricles, the apex and the anterior two-thirds of the interventricular septum)
- the circumflex branch (supplying the left atrium and left ventricle).

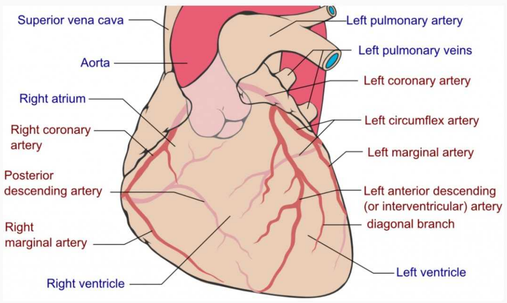


By Coronary.pdf: Patrick J. Lynch, medical illustrator derivative work: Fred the Oyster (talk) adaption and further labeling: Mikael Häggström (Coronary.pdf) [CC BY-SA 3.0 (http://creativecommons.org/licenses/by-sa/3.0)], via Wikimedia Commons

< Previous | Next >

Something wrong?

## Question Navigator

1 Answered
2 Answered
3 Answered
4 Answered
5 Answered
6 Answered
7 Answered
8 Answered
9 Answered
10 Answered
11 Answered
12 Answered



©2014 - 2017 FRCEM Success | Website designed & hosted by Cyberfrog Design

# Anatomy: Thorax

Question 65 of 134

## Regarding the bronchial tree, which of the following statements is CORRECT:

a The trachea bifurcates into the left and right main bronchi at the level of vertebra T3.

b The right bronchus is wider, shorter and runs more vertically than the left bronchus.

c The lobar bronchi supply one bronchopulmonary segment each.

d The terminal bronchioles participate in gas exchange.

e A ridge of cartilage called the carina runs between the openings of the lobar bronchi.

< Previous | Next > | See Answer

Something wrong?

Question Navigator

1 Answered
2 Answered
3 Answered
4 Answered
5 Answered
6 Answered
7 Answered
8 Answered
9 Answered
10 Answered
11 Answered
12 Answered



©2014 - 2017 FRCEM Success | Website designed & hosted by Cyberfrog Design

# Anatomy: Thorax

Question 65 of 134

Regarding the bronchial tree, which of the following statements is CORRECT:

**a)** The trachea bifurcates into the left and right main bronchi at the level of vertebra T3.

**b)** ✔

**The right bronchus is wider, shorter and runs more vertically than the left bronchus.**

**c)** The lobar bronchi supply one bronchopulmonary segment each.

**d)** The terminal bronchioles participate in gas exchange.

**e)** A ridge of cartilage called the carina runs between the openings of the lobar bronchi.

## Answer

The trachea bifurcates into the right and left main bronchi at the level of vertebra T4/T5. The right bronchus is wider, shorter and runs more vertically than the left bronchus. The lobar bronchi each supply a lobe. The respiratory bronchioles participate in gas exchange,

## Notes

The trachea bifurcates into a left and right main bronchus at the level of vertebra T4/T5. At the bifurcation of the main bronchi, a ridge of cartilage called the carina runs anteroposteriorly between the openings of the two bronchi.

Each main bronchus enters the root of a lung and passes through the hilum into the lung itself. The right main bronchus is wider and takes a more vertical course through the root and hilum than the left main bronchus, therefore inhaled foreign bodies are more likely to lodge on the right than the left.

The main bronchus divides into lobar bronchi (secondary bronchi) which each supply a lobe. The lobar bronchi further divided into segmental bronchi (tertiary bronchi) which supply bronchopulmonary segments (the functional unit of the lung).

Within each bronchopulmonary segment, the segmental bronchi give rise to multiple generations of divisions and ultimately to bronchioles (in order, conducting bronchioles, terminal bronchioles, respiratory bronchioles). The respiratory bronchioles continue as alveolar ducts and sacs, the walls of which form alveoli.

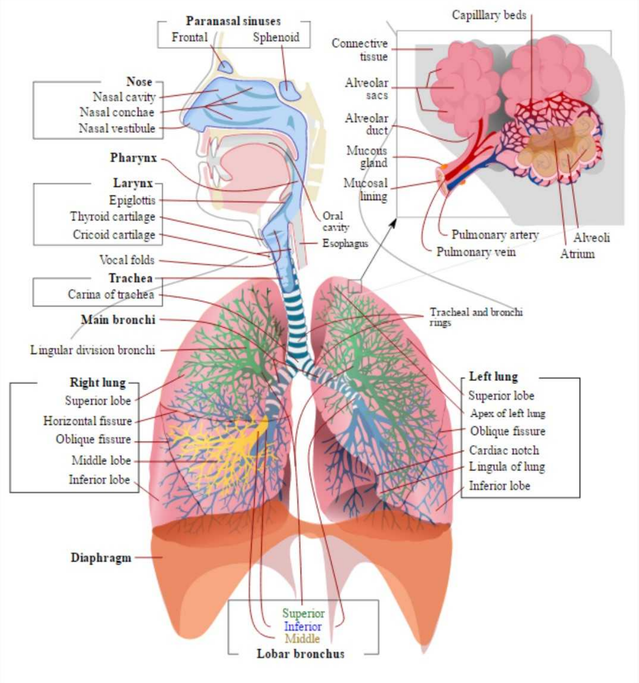


By LadyofHats [Public domain], via Wikimedia Commons

< Previous | Next >

Something wrong?

## Question Navigator

1 Answered
2 Answered
3 Answered
4 Answered
5 Answered
6 Answered
7 Answered
8 Answered
9 Answered
10 Answered
11 Answered
12 Answered



©2014 - 2017 FRCEM Success | Website designed & hosted by Cyberfrog Design

# Anatomy: Thorax

Question 66 of 134

## Which of the following actions does not typically occur as part of normal inspiration:

a Contraction of the diaphragm

b Flattening of the diaphragm

c Contraction of the internal intercostal muscles

d Upwards and forward movements of the sternum

e Lateral movements of the ribs

< Previous | Next > | See Answer

Something wrong?

## Question Navigator

1 Answered
2 Answered
3 Answered
4 Answered
5 Answered
6 Answered
7 Answered
8 Answered
9 Answered
10 Answered
11 Answered
12 Answered



©2014 - 2017 FRCEM Success | Website designed & hosted by Cyberfrog Design

# Anatomy: Thorax

Question 66 of 134

Which of the following actions does not typically occur as part of normal inspiration:

**a)** Contraction of the diaphragm
**b)** Flattening of the diaphragm
**c)** **Contraction of the internal intercostal muscles** ✔
**d)** Upwards and forward movements of the sternum
**e)** Lateral movements of the ribs

## Answer

Passive inspiration is produced by contraction of the diaphragm (depressing the diaphragm) and the external intercostal muscles (elevating the ribs). In inspiration, elevation of the sternal ends of the ribs ('pump handle' movement), elevation of the lateral shafts of the ribs ('bucket handle' movement) and depression of the diaphragm result in expansion of the thorax in an anteroposterior, transverse and vertical direction respectively. This results in an increased intrathoracic volume and decreased intrathoracic pressure and thus air is drawn into the lungs.

## Notes

**Thoracic wall movements**

Movement of the ribs at the costovertebral joints in respiration results in the 'pump handle' and 'bucket handle' movements:

- Because the anterior ends of the ribs are inferior to the posterior ends, when the ribs are elevated, the anterior end moves upwards and forwards, moving the sternum upwards and forwards in turn. This 'pump handle' upwards and forwards movement changes the anteroposterior (AP) dimension of the thorax.
- Because the shafts of the ribs are lower than either the anterior or posterior end, elevation of the ribs also moves the shafts laterally. This 'bucket handle' upwards and lateral movement increases the lateral dimensions of the thorax.

Reversal of these movements i.e. depression of the ribs, will reduce the anteroposterior and transverse dimensions of the thorax.

**Inspiration**

In inspiration, elevation of the sternal ends of the ribs ('pump handle' movement), elevation of the lateral shafts of the ribs ('bucket handle' movement) and depression of the diaphragm result in expansion of the thorax in an anteroposterior, transverse and vertical direction respectively. This results in an increased intrathoracic volume and decreased intrathoracic pressure and thus air is drawn into the lungs.

Passive inspiration is produced by contraction of the diaphragm (depressing the diaphragm) and the external intercostal muscles (elevating the ribs).

The accessory respiratory muscles (including the sternocleidomastoid, the scalene muscles and the serratus anterior amongst others) aid in forceful inspiration.

**Expiration**

In expiration, depression of the ribs and elevation of the diaphragm result in a reduction of the thorax in an anteroposterior, transverse and vertical direction. This results in a decreased intrathoracic volume and increased intrathoracic pressure and thus air is forced out of the lungs.

Passive expiration is produced primarily by relaxation of the inspiratory muscles (diaphragm and external intercostal muscles) and the elastic recoil of the lungs.

Forceful expiration is primarily produced by the deeper thoracic muscles (internal and innermost intercostal muscles, subcostals and transversus thoracis) aided by contraction of the abdominal wall muscles which increase intra-abdominal pressure thus further reducing the volume of the thorax.

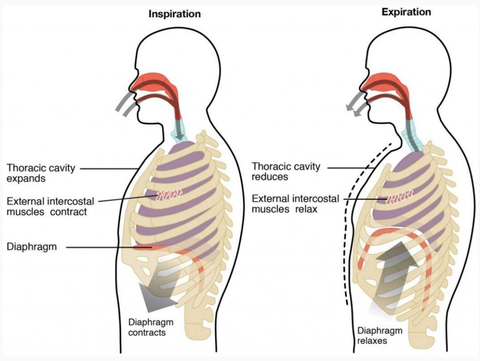


By OpenStax College [CC BY 3.0 (http://creativecommons.org/licenses/by/3.0)], via Wikimedia Commons

**Paradoxical respiration**

Normally as the diaphragm moves downwards in respiration, the abdominal wall moves outwards (together with the chest wall), and the reverse occurs in expiration.

In complete airway obstruction, the diaphragm will move down and the abdominal wall out but as inspiratory effort continues against a closed airway, increasing intrathoracic pressure will draw the chest wall paradoxically inwards (against the opposing action of the intercostal muscles). To the observer, in inspiration there is abdominal expansion with chest collapse and during expiration the reverse is seen. As inspiratory effort increases and expiration becomes active, the see-sawing pattern becomes more pronounced.

Flail chest is a loss of stability of the thoracic cage that occurs when a segment of the anterior or lateral thoracic wall moves freely because of multiple rib fractures, allowing the loose segment to move paradoxically inward on inspiration and outward on expiration. If a large enough segment of the chest is affected, ventilation is impaired.

< Previous | Next >

Something wrong?

Question Navigator

1 Answered
2 Answered
3 Answered
4 Answered
5 Answered
6 Answered
7 Answered
8 Answered
9 Answered
10 Answered
11 Answered
12 Answered



©2014 - 2017 FRCEM Success | Website designed & hosted by Cyberfrog Design

# Anatomy: Thorax

Question 67 of 134

## The right border of the heart is formed predominantly by which of the following:

a Right atrium

b Left atrium

c Right ventricle

d Left ventricle

e Great vessels

< Previous | Next > | See Answer

Something wrong?

Question Navigator

1 Answered
2 Answered
3 Answered
4 Answered
5 Answered
6 Answered
7 Answered
8 Answered
9 Answered
10 Answered
11 Answered
12 Answered



©2014 - 2017 FRCEM Success | Website designed & hosted by Cyberfrog Design

# Anatomy: Thorax

Question 67 of 134

The right border of the heart is formed predominantly by which of the following:

a) **Right atrium** ✔
b) Left atrium
c) Right ventricle
d) Left ventricle
e) Great vessels

## Answer

The right border is formed by the right atrium.

## Notes

| Border/Surface | Main structure (contributing structures) |
|---|---|
| Apex | Left ventricle |
| Base | Left atrium (right atrium, proximal great veins) |
| Anterior surface | Right ventricle (right atrium, left ventricle) |
| Inferior surface | Left and right ventricle |
| Left pulmonary surface | Left ventricle (left atrium) |
| Right pulmonary surface | Right atrium |
| Inferior border | Right ventricle (left ventricle) |
| Left border | Left ventricle (left auricle) |
| Right border | Right atrium |
| Superior border | Both atria, roots of great vessels |

The general shape and orientation of the heart are that of a pyramid that has fallen over and is resting on one of its sides.

- The apex of this pyramid projects forwards, downwards and to the left. The apex is formed by the inferolateral part of the left ventricle and is positioned deep to the left fifth intercostal space in the midclavicular line.
- The base is facing posteriorly. The base is formed mostly by the left atrium with a small portion of the right atrium and the proximal part of the great veins, and is fixed posteriorly to the pericardial wall, opposite the bodies of the T5 – T8 vertebrae (T6 – T9 when standing). The oesophagus lies immediately posterior to the base.

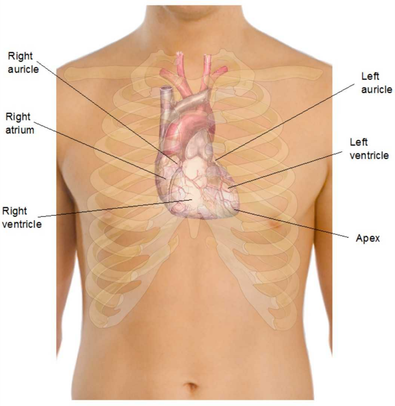


Modified by FRCEM Success. Original by Mikael Häggström (See above. All used images are in public domain.) [Public domain], via Wikimedia Commons

**Surfaces**

There are four surfaces to the upturned pyramid:

- The anterior (sternocostal) surface consists mostly of the right ventricle with some of the right atrium and some of the left ventricle.
- The inferior (diaphragmatic) surface consists of the left ventricle with a small portion of the right ventricle separated by the posterior interventricular groove.
- The left pulmonary surface consists mainly of the left ventricle and a portion of the left atrium.
- The right pulmonary surface consists of the right atrium.

**Borders**

There are four main borders separating the surfaces of the heart:

- The inferior border is formed mostly by the right ventricle and a small portion of the left ventricle near the apex.
- The left border is formed mostly by the left ventricle with a small portion of the left auricle.
- The right border is formed by the right atrium.
- The superior border is formed by both atria and the roots of the great vessels.

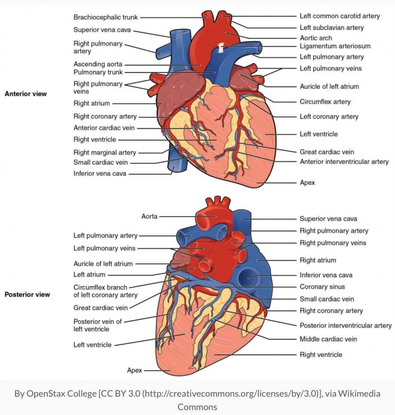


By OpenStax College [CC BY 3.0 (http://creativecommons.org/licenses/by/3.0)], via Wikimedia Commons

< Previous | Next >

Something wrong?

### Question Navigator

1 Answered
2 Answered
3 Answered
4 Answered
5 Answered
6 Answered
7 Answered
8 Answered
9 Answered
10 Answered
11 Answered
12 Answered



©2014 - 2017 FRCEM Success | Website designed & hosted by Cyberfrog Design

# Anatomy: Thorax

Question 68 of 134

A 35 year old woman is brought to ED having been involved in a road traffic accident. She has sustained a chest injury on impact with the steering wheel and fractured the sternum at the manubriosternal joint. Which of the following ribs would most likely also be involved in this injury:

a First rib

b Second rib

c Third rib

d Fourth rib

e Fifth rib

< Previous | Next > | See Answer

Something wrong?

## Question Navigator

1 Answered
2 Answered
3 Answered
4 Answered
5 Answered
6 Answered
7 Answered
8 Answered
9 Answered
10 Answered
11 Answered
12 Answered



©2014 - 2017 FRCEM Success | Website designed & hosted by Cyberfrog Design

# Anatomy: Thorax

Question 68 of 134

A 35 year old woman is brought to ED having been involved in a road traffic accident. She has sustained a chest injury on impact with the steering wheel and fractured the sternum at the manubriosternal joint. Which of the following ribs would most likely also be involved in this injury:

a) First rib
b) **Second rib** ✔
c) Third rib
d) Fourth rib
e) Fifth rib

## Answer

The first rib articulates with the manubrium of the sternum forming the anterior border of the thoracic inlet. The second rib articulates with the sternum at the manubriosternal joint (the sternal angle).

## Notes

There are twelve pairs of ribs, each terminating anteriorly in a costal cartilage.

**True and False ribs**

The ribs are divided into 'true' and 'false' ribs based on their anterior attachments:

- The true ribs (1 – 7) attach directly to the sternum anteriorly.
- The false ribs (8 – 12) can be further divided into those that attach to the costal cartilage of the rib above them (8 – 10) and the floating ribs (11 + 12) that do not have any anterior attachments.

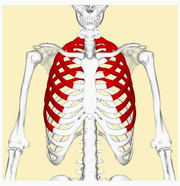

By Anatomography (en:Anatomography (setting page of this image)) [CC BY-SA 2.1 jp (http://creativecommons.org/licenses/by-sa/2.1/jp/deed.en)], via Wikimedia Commons

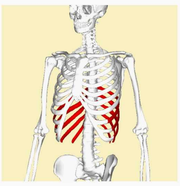

By Anatomography (en:Anatomography (setting page of this image)) [CC BY-SA 2.1 jp (http://creativecommons.org/licenses/by-sa/2.1/jp/deed.en)], via Wikimedia Commons

**Thoracic vertebrae**

Posteriorly, all of the ribs articulate with the thoracic vertebrae of the spine.

Each typical rib forms two joints posteriorly:

- the costotransverse joint (between the tubercle of the rib and the transverse process of the corresponding vertebra)
- the costovertebral joint (between the two facets on the head of the rib and the superior costal facet on the body of the corresponding vertebra, and the inferior costal facet on the body of the vertebra above).

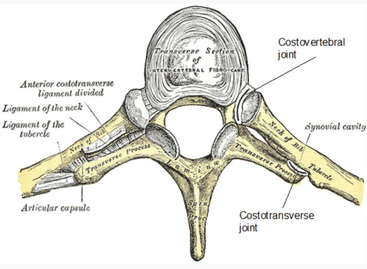


Modified by FRCEM Success. Original by Henry Vandyke Carter [Public domain], via Wikimedia Commons

**Typical ribs**

The typical rib consists of a head, a neck and a body:

- The head of the rib has two articular facets which articulate with the superior costal facet on the body of the corresponding vertebra, and the inferior costal facet on the body of the vertebra above.
- The neck of the rib connects the head to the body. Where the neck meets the body, there is a tubercle which articulates with the transverse process of the corresponding vertebra.
- The body of the rib is flat and curved.

The inferior margin of the internal surface of the body is marked by the costal groove which protects the neurovascular structures which run within it.

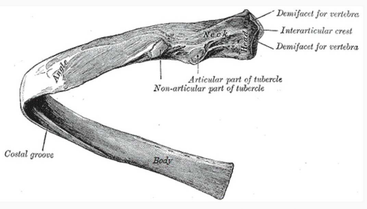


Modified by FRCEM Success. Original by Henry Vandyke Carter [Public domain], via Wikimedia Commons

**Atypical ribs**

The atypical ribs consist of ribs 1, 2, 10, 11 and 12.

| Atypical rib | Features |
|---|---|
| Rib 1 | Shorter and wider, single facet for articulation with T1, scalene tubercle |
| Rib 2 | Flat, roughened area for attachment of serratus anterior muscle |
| Rib 10 | Single facet for articulation with T10 |
| Rib 11 | No neck, single facet for articulation with T11 |
| Rib 12 | No neck, single facet for articulation with T12 |

- Rib 1 is shorter and wider than the other ribs. The head of rib 1 has only one facet for articulation with the body of its own vertebra (T1); it does NOT articulate with vertebra C7. The superior surface of rib 1 is characterised by the scalene tubercle about midway along the body, which separates two smooth grooves in the rib made by the subclavian vein anteriorly and the subclavian artery posteriorly.
- Like rib 1, rib 2 is flat but twice as long. It has a roughened area on its upper surface where the serratus anterior muscle attaches.
- The head of rib 10 only has a single facet for articulation with the body of its own vertebra (T10).
- Ribs 11 and 12 have no neck, and have only one facet for articulation with the bodies of their own vertebrae (T11 and T12).

< Previous | Next >

Something wrong?

## Question Navigator

1 Answered
2 Answered
3 Answered
4 Answered
5 Answered
6 Answered
7 Answered
8 Answered
9 Answered
10 Answered
11 Answered
12 Answered



©2014 - 2017 FRCEM Success | Website designed & hosted by Cyberfrog Design

# Anatomy: Thorax

Question 69 of 134

## The upper limit of the heart on the right side of the sternum is the:

a First costal cartilage

b Second costal cartilage

c Third costal cartilage

d Fourth costal cartilage

e Fifth costal cartilage

< Previous | Next > | See Answer

Something wrong?

## Question Navigator

1 Answered
2 Answered
3 Answered
4 Answered
5 Answered
6 Answered
7 Answered
8 Answered
9 Answered
10 Answered
11 Answered
12 Answered



©2014 - 2017 FRCEM Success | Website designed & hosted by Cyberfrog Design

# Anatomy: Thorax

Question 69 of 134

The upper limit of the heart on the right side of the sternum is the:

a) First costal cartilage
b) **Second costal cartilage** ✗
c) Third costal cartilage ✓
d) Fourth costal cartilage
e) Fifth costal cartilage

## Answer

The upper limit of the heart reaches as high as the third costal cartilage on the right side of the sternum and the second intercostal space on the left side of the sternum.

## Notes

Surface markings

| Heart | Surface marking |
|---|---|
| Right upper limit | Third costal cartilage |
| Left upper limit | Second intercostal space |
| Right lower limit | Sixth costal cartilage |
| Left lower limit | Fifth intercostal space |

The upper limit of the heart reaches as high as the third costal cartilage on the right side of the sternum and the second intercostal space on the left side of the sternum.

The lower limit of the heart extends from the sternal end of the right sixth costal cartilage to the apex in the fifth intercostal space near the midclavicular line.

The right margin of the heart therefore extends from the right third costal cartilage to near the right sixth costal cartilage and the left margin of the heart extends from the left second intercostal space to the apex located near the midclavicular line in the fifth intercostal space.

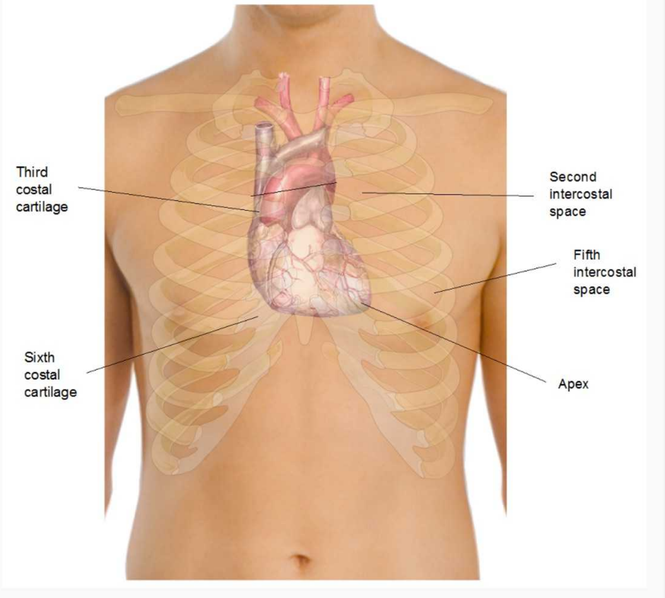


Modified by FRCEM Success. Original by Mikael Häggström[Public domain], via Wikimedia Commons

< Previous | Next >

Something wrong?

## Question Navigator

1 Answered
2 Answered
3 Answered
4 Answered
5 Answered
6 Answered
7 Answered
8 Answered
9 Answered
10 Answered
11 Answered
12 Answered



©2014 - 2017 FRCEM Success | Website designed & hosted by Cyberfrog Design

# Anatomy: Thorax

Question 70 of 134

## Which of the following structures pass through the oesophageal opening in the diaphragm:

a Oesophagus and vagus nerve

b Oesophagus and phrenic nerve

c Oesophagus and thoracic duct

d Oesophagus and azygos vein

e Oesophagus alone

< Previous | Next > | See Answer

Something wrong?

Question Navigator

1 Answered
2 Answered
3 Answered
4 Answered
5 Answered
6 Answered
7 Answered
8 Answered
9 Answered
10 Answered
11 Answered
12 Answered



©2014 - 2017 FRCEM Success | Website designed & hosted by Cyberfrog Design

# Anatomy: Thorax

Question 70 of 134

Which of the following structures pass through the oesophageal opening in the diaphragm:

**a) Oesophagus and vagus nerve** ✔
**b)** Oesophagus and phrenic nerve
**c)** Oesophagus and thoracic duct
**d)** Oesophagus and azygos vein
**e)** Oesophagus alone

## Answer

The oesophageal opening in the diaphragm is a vertebral level T10 and transmits the oesophagus, the anterior and posterior vagal trunks, oesophageal branches of the left gastric vessels and a few lymphatics.

## Notes

The diaphragm is a musculotendinous structure that separates the thoracic cavity from the abdominal cavity.

| Structure | Diaphragm |
|---|---|
| Primary function | Respiration – contraction of diaphragm flattens diaphragm increasing vertical dimension of thorax (inspiration), relaxation of diaphragm elevates diaphragm decreasing vertical dimension of thorax (expiration) |
| Secondary functions | Assists in straining movements by increasing intra-abdominal pressure, acts as functional sphincter on oesophagus preventing acid reflux |
| Peripheral attachments | Xiphoid process of sternum, costal cartilages ribs 7 – 10, ends of ribs 11 and 12, arcuate ligaments and lumbar vertebrae |
| Central attachment | Fuses with fibrous pericardium superiorly |
| Surface markings | Attachments: vertebrae T8/T9 anteriorly, vertebra T12 posteriorly, Domes: right dome 5th rib, left dome 5th intercostal space |
| Openings | Oesophageal opening at T10 (oesophagus, vagus nerve), aortic opening at T12 (aorta, thoracic duct and azygos vein), caval opening at T8 (inferior vena cava and right phrenic nerve) |
| Innervation | Phrenic nerve (C3 – C5) |

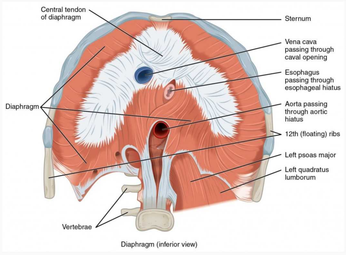


By OpenStax [CC BY 4.0 (http://creativecommons.org/licenses/by/4.0)], via Wikimedia Commons

### Function

The diaphragm performs an important function in respiration; contraction of the domes of the diaphragm in inspiration flattens the diaphragm, increasing the vertical dimension of the thorax and vice versa in expiration, with relaxation and elevation of the diaphragm reducing the vertical dimension of the thorax.

The diaphragm is also involved in non-respiratory functions; helping to expel vomit, faeces, and urine from the body by increasing intraabdominal pressure, and preventing acid reflux by exerting pressure on the oesophagus as it passes through the oesophageal opening.

### Attachments

The diaphragm is attached peripherally to:

- the xiphoid process of the sternum and the costal cartilages of ribs 7 – 10 (the costal margin) anteriorly
- the ends of ribs 11 and 12 laterally
- the arcuate ligaments and vertebrae posteriorly.

From these peripheral attachments, muscle fibres converge to form the central tendon which fuses with the fibrous pericardium superiorly.

### Surface markings

In the medial sagittal plane, the diaphragm slopes inferiorly from its anterior attachment to the xiphoid at approximately vertebral level T8/T9 to its posterior attachment to the median arcuate ligament at approximately vertebral level T12.

At rest the right dome of the diaphragm lies slightly higher than the left; this is thought to be due to the position of the liver. In normal expiration, the normal upper limits of the superior margins are the fifth rib for the right dome, the fifth intercostal space for the left dome and the xiphoid process for the central tendon.

### Diaphragmatic openings

Structures travelling between the thorax and abdomen must pass through the diaphragm via three main openings.

The oesophageal opening at vertebral level T10 transmits:

- the oesophagus
- the anterior and posterior vagal trunks
- oesophageal branches of the left gastric vessels
- a few lymphatics.

The aortic opening at vertebral level T12 transmits:

- the aorta
- the thoracic duct
- the azygos vein and sometimes the hemiazygos vein.

The caval opening at vertebral level T8 transmits:

- the inferior vena cava
- the right phrenic nerve.

### Innervation

The entire motor supply of the diaphragm is from the right and left phrenic nerves (C3 – C5) which penetrate the diaphragm and innervate it from its abdominal surface.

Damage to the phrenic nerve will result in hemiparalysis of the diaphragm. Paralysis of the diaphragm produces a paradoxical movement. The affected side of the diaphragm moves upwards during inspiration (as it is pushed superiorly by the abdominal viscera that are being actively compressed by the other half), and downwards during expiration.

A unilateral diaphragmatic paralysis is usually asymptomatic, and is most often an incidental finding on x-ray. If both sides are paralysed, the patient may experience poor exercise tolerance, orthopnoea and fatigue. Lung function tests will show a restrictive deficit.

### Diaphragmatic herniation

Diaphragmatic hernias are defined as congenital or acquired defects in the diaphragm. There are two main types of congenital diaphragmatic hernias; Bochdalek hernias and Morgagni hernias.

Acquired diaphragmatic hernias include traumatic diaphragmatic rupture, hiatus hernia and iatrogenic diaphragmatic hernias. Depending on the location and size of the defect, retroperitoneal or intra-abdominal organs and tissues can prolapse into the thoracic cavity due to the negative intrathoracic pressure.

Diaphragmatic rupture usually results from blunt abdominal trauma, which is typically associated with motor-vehicle accidents; the most commonly herniated viscera are the stomach and colon on the left side, and the liver on the right side.

In hiatus hernia, the stomach herniates through the oesophageal opening of the diaphragm, typically resulting in symptoms of acid reflux.

< Previous | Next >

Something wrong?

## Question Navigator

1 Answered
2 Answered
3 Answered
4 Answered
5 Answered
6 Answered
7 Answered
8 Answered
9 Answered
10 Answered
11 Answered
12 Answered



©2014 - 2017 FRCEM Success | Website designed & hosted by Cyberfrog Design

# Anatomy: Thorax

Question 71 of 134

## The mitral valve is best auscultated at which of the following sites:

a Just left of the lower part of the sternum near the fifth intercostal space

b In the left fifth intercostal space at the midclavicular line

c Over the medial end of the left fourth intercostal space

d Over the medial end of the right fourth intercostal space

e Just right of the lower part of the sternum near the fifth intercostal space

< Previous | Next > | See Answer

Something wrong?

## Question Navigator

1 Answered
2 Answered
3 Answered
4 Answered
5 Answered
6 Answered
7 Answered
8 Answered
9 Answered
10 Answered
11 Answered
12 Answered



©2014 - 2017 FRCEM Success | Website designed & hosted by Cyberfrog Design

# Anatomy: Thorax

Question 71 of 134

The mitral valve is best auscultated at which of the following sites:

a) Just left of the lower part of the sternum near the fifth intercostal space
b) **In the left fifth intercostal space at the midclavicular line** ✔
c) Over the medial end of the left fourth intercostal space
d) Over the medial end of the right fourth intercostal space
e) Just right of the lower part of the sternum near the fifth intercostal space

## Answer

The mitral valve is heard over the apex of the heart in the left fifth intercostal space at the midclavicular line.

## Notes

| Heart valve | Surface marking | Auscultation position |
|---|---|---|
| Tricuspid valve | Posterior to right half of sternum at level of 4th ICS | Left of sternum near 5th ICS |
| Mitral valve | Posterior to left half of sternum at level of 4th costal cartilage | Left 5th ICS in midclavicular line |
| Pulmonary valve | Posterior to third left chondrosternal joint | Medial end of left 2nd ICS |
| Aortic valve | Posterior to left half of sternum at level of 3rd ICS | Medial end of right 2nd ICS |

**Surface marking of heart valves**

- The tricuspid valve is located posterior to the right half of the sternum at the level of the fourth intercostal space.
- The mitral valve is located posterior to the left half of the sternum at the level of the fourth costal cartilage.
- The pulmonary valve is located posterior to the third left chondrosternal joint.
- The aortic valve is located posterior to the left half of the sternum at the level of the third intercostal space.

**Auscultation positions of heart valves**

Heart valves should be auscultated by positioning the stethoscope downstream from the flow of blood through the valves.

- The tricuspid valve is heard just to the left of the lower part of the sternum near the fifth intercostal space.
- The mitral valve is heard over the apex of the heart in the left fifth intercostal space at the midclavicular line.
- The pulmonary valve is heard over the medial end of the left second intercostal space.
- The aortic valve is heard over the medial end of the right second intercostal space.

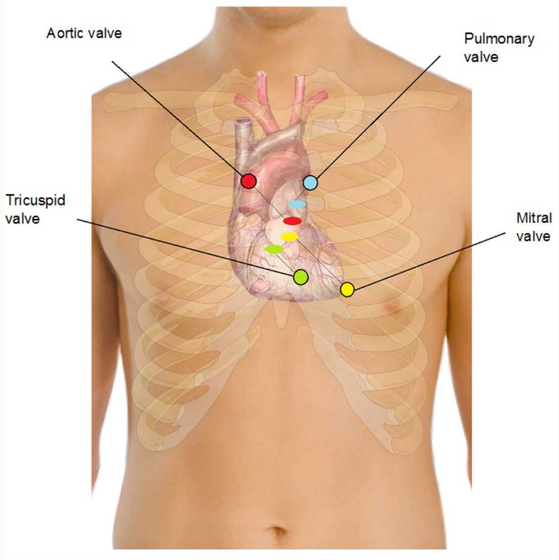


Modified by FRCEM Success. Original by Mikael Häggström [Public domain], via Wikimedia Commons

< Previous | Next >

Something wrong?

## Question Navigator

1 Answered
2 Answered
3 Answered
4 Answered
5 Answered
6 Answered
7 Answered
8 Answered
9 Answered
10 Answered
11 Answered
12 Answered



©2014 - 2017 FRCEM Success | Website designed & hosted by Cyberfrog Design

# Anatomy: Thorax

Question 72 of 134

## The inferior margin of the pleural cavity is a line that runs anterolaterally between which of the following surface markings:

a Rib 7 in the midclavicular line and rib 8 in the midaxillary line

b Rib 8 in the midclavicular line and rib 8 in the midaxillary line

c Rib 8 in the midclavicular line and rib 9 in the midaxillary line

d Rib 8 in the midclavicular line and rib 10 in the midaxillary line

e Rib 10 in the midclavicular line and rib 11 in the midaxillary line

< Previous | Next > | See Answer

Something wrong?

Question Navigator

1 Answered
2 Answered
3 Answered
4 Answered
5 Answered
6 Answered
7 Answered
8 Answered
9 Answered
10 Answered
11 Answered
12 Answered



©2014 - 2017 FRCEM Success | Website designed & hosted by Cyberfrog Design

# Anatomy: Thorax

Question 72 of 134

The inferior margin of the pleural cavity is a line that runs anterolaterally between which of the following surface markings:

a) Rib 7 in the midclavicular line and rib 8 in the midaxillary line
b) Rib 8 in the midclavicular line and rib 8 in the midaxillary line
c) Rib 8 in the midclavicular line and rib 9 in the midaxillary line
d) **Rib 8 in the midclavicular line and rib 10 in the midaxillary line** ✔
e) Rib 10 in the midclavicular line and rib 11 in the midaxillary line

## Answer

The inferior margin of the pleural cavity is a line that runs between rib 8 in the midclavicular line, rib 10 in the midaxillary line and vertebra T12 posteriorly. The inferior margin of the lung in quiet respiration is a line that runs between rib 6 in the midclavicular line, rib 8 in the midaxillary line and vertebra T10 posteriorly.

## Notes

Each lung is surrounded by a pleura. The pleura consists of two parts, the parietal pleura (which lines the thoracic cavity) and the visceral pleura (which lines the lungs). The two parts of the pleura are continuous with each other at the hilum of each lung. The potential space between these two parts of the pleura is called the pleural cavity.

**Pleural cavity**

The pleural cavity normally contains a small amount of lubricating fluid to allow the visceral pleura attached to the lungs to smoothly slide over the parietal pleura attached to the thoracic wall during respiration. The serous fluid also produces a surface tension, pulling the parietal and visceral pleura together. This ensures that when the thorax expands, the lung also expands, filling with air.

**Innervation**

The parietal pleura is innervated by somatic afferent fibres. The costal pleura (pleura related to the ribs and intercostal spaces) is innervated by branches of the intercostal nerves, and pain is felt in relation to the thoracic wall. The diaphragmatic pleura (covering the diaphragm) and the mediastinal pleura (covering the mediastinum) are innervated mainly by the phrenic nerves (C3 – C5), and pain is referred the the C3 – C5 dermatomes (lateral neck and supraclavicular region of shoulder).

Although the visceral pleura is innervated by visceral afferent fibres, pain is not generally elicited from this tissue.

**Surface markings**

Superiorly the pleural cavity projects as much as 3 – 4 cm above the first costal cartilage but does not extend above the neck of rib 1.

Anteriorly the pleurae approach each other posterior to the upper part of the sternum. At the lower part of the sternum the left pleura does not come as close to the midline as the right pleura because the middle mediastinum bulges to the left.

Inferiorly the pleura reflects onto the diaphragm above the costal margin. The inferior margin of the pleural cavity is a line that runs between rib 8 in the midclavicular line, rib 10 in the midaxillary line and vertebra T12 posteriorly.

The inferior margin of the lung in quiet respiration is a line that runs between rib 6 in the midclavicular line, rib 8 in the midaxillary line and vertebra T10 posteriorly.

The lungs therefore do not completely fill the pleural cavities, producing two pleural recesses, the costomediastinal and costodiaphragmatic recesses, in which fluids can collect.

The costomediastinal recess occurs on each side where the the costal pleura is opposed to mediastinal pleura, particularly on the left side in the region overlying the heart.

The costodiaphragmatic recess occurs between the costal and diaphragmatic pleura. It is the region between the inferior margin of the lung and the inferior margin of the pleural cavity and is clinically important for pleural aspiration.

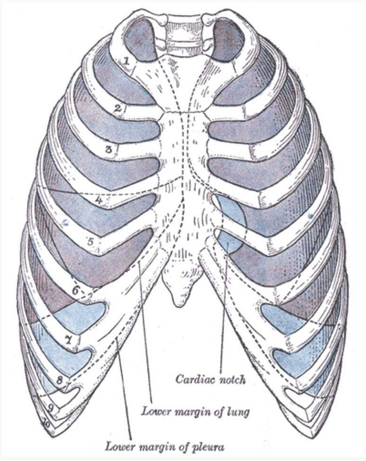


By Henry Vandyke Carter [Public domain], via Wikimedia Commons

< Previous | Next >

Something wrong?

## Question Navigator

1 Answered
2 Answered
3 Answered
4 Answered
5 Answered
6 Answered
7 Answered
8 Answered
9 Answered
10 Answered
11 Answered
12 Answered



©2014 - 2017 FRCEM Success | Website designed & hosted by Cyberfrog Design

# Anatomy: Thorax

Question 73 of 134

## Regarding the muscles of the thoracic wall, which of the following statements is CORRECT:

a The external intercostal muscles fibres run in an posteroinferior direction.

b The external intercostal muscles are important for forced expiration.

c The internal intercostal muscles act to move the ribs inferiorly.

d The neurovascular bundle runs deep to the innermost intercostal muscles.

e The innermost intercostal muscles lie deep to the transversus thoracis.

< Previous | Next > | See Answer

Something wrong?

## Question Navigator

1 Answered
2 Answered
3 Answered
4 Answered
5 Answered
6 Answered
7 Answered
8 Answered
9 Answered
10 Answered
11 Answered
12 Answered



©2014 - 2017 FRCEM Success | Website designed & hosted by Cyberfrog Design

# Anatomy: Thorax

Question 73 of 134

Regarding the muscles of the thoracic wall, which of the following statements is CORRECT:

a) The external intercostal muscles fibres run in an posteroinferior direction.
b) The external intercostal muscles are important for forced expiration.
c) **The internal intercostal muscles act to move the ribs inferiorly.** ✔
d) The neurovascular bundle runs deep to the innermost intercostal muscles.
e) The innermost intercostal muscles lie deep to the transversus thoracis.

## Answer

The internal intercostal muscles lie deep to the external intercostal muscles. They run posteroinferiorly from the rib above to the rib below, and are continuous with the internal oblique muscle inferiorly. The internal intercostal muscles act to move the ribs inferiorly and are most active during expiration.

## Notes

The intercostal muscles are three flat muscles found in each intercostal space that pass between adjacent ribs. As a group the intercostal muscles provide structural support of the intercostal spaces during breathing and can also act to move the ribs.

| Muscle | Function |
|---|---|
| External intercostal | Move ribs superiorly, most active in inspiration |
| Internal intercostal | Move ribs inferiorly, most active in expiration |
| Innermost intercostal | Acts with internal intercostal muscles |
| Transversus thoracis | Depresses costal cartilages |

The external intercostal muscles lie in the outer layer. They run anteroinferiorly from the rib above to the rib below, and are continuous with the external oblique muscle inferiorly. The external intercostal muscles act to move the ribs superiorly and are most active in inspiration.

The internal intercostal muscles lie deep to the external intercostal muscles. They run posteroinferiorly from the rib above to the rib below, and are continuous with the internal oblique muscle inferiorly. The internal intercostal muscles act to move the ribs inferiorly and are most active during expiration.

The innermost intercostal muscles are the deepest of the intercostal muscles and are very similar to the internal intercostal muscles in terms of structure and function.

The transversus thoracis muscle is also part of the innermost layer, and is continuous inferiorly with the transversus abdominis muscle inferiorly.

The neurovascular bundles associated with the intercostal spaces pass around the thoracic wall in the costal grooves in a plane between the layers of the internal and innermost intercostal muscles.

The intercostal and transversus thoracis muscles are innervated by the intercostal nerves (T1 – T11).

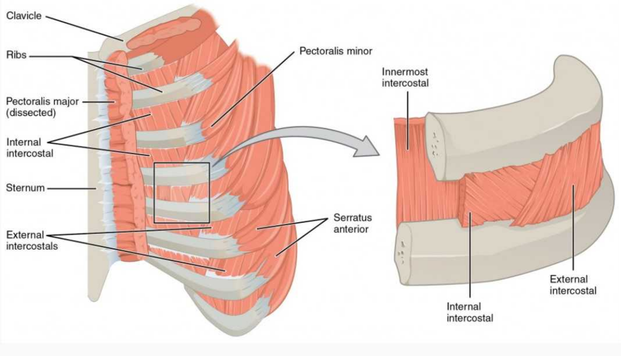


By CFCF (Own work) [CC BY-SA 4.0 (http://creativecommons.org/licenses/by-sa/4.0)], via Wikimedia Commons

< Previous | Next >

Something wrong?

## Question Navigator

1 Answered
2 Answered
3 Answered
4 Answered
5 Answered
6 Answered
7 Answered
8 Answered
9 Answered
10 Answered
11 Answered
12 Answered



©2014 - 2017 FRCEM Success | Website designed & hosted by Cyberfrog Design

# Anatomy: Thorax

Question 74 of 134

## The medial surface of the left lung lies adjacent to all of the following structures except for the:

a Heart

b Aortic arch

c Thoracic aorta

d Oesophagus

e Superior vena cava

< Previous | Next > | See Answer

Something wrong?

Question Navigator

1 Answered
2 Answered
3 Answered
4 Answered
5 Answered
6 Answered
7 Answered
8 Answered
9 Answered
10 Answered
11 Answered
12 Answered



©2014 - 2017 FRCEM Success | Website designed & hosted by Cyberfrog Design

# Anatomy: Thorax

Question 74 of 134

The medial surface of the left lung lies adjacent to all of the following structures except for the:

**a)** Heart
**b)** Aortic arch
**c)** Thoracic aorta
**d)** **Oesophagus** ✗
**e)** Superior vena cava ✓

## Answer

The medial surface of the left lung lies adjacent to:

- the heart
- the aortic arch
- the thoracic aorta
- the oesophagus.

## Notes

The lungs lie on either side of the mediastinum, each surrounded by a pleural cavity. They are suspended from the mediastinum by the root of the lung, a short tubular collection of structures.

**Lung root**

The root is lined by a layer of mediastinal pleura that reflects onto the surface of the lungs as visceral pleura. The region outlined by this pleural reflection on the medial surface of the lung is the hilum, where structures enter and leave.

The hila are located at the level of the 3rd – 4th costal cartilage anteriorly, and the T5 – T7 vertebrae posteriorly.

Each lung root contains:

- a pulmonary artery
- two pulmonary veins
- a main bronchus
- bronchial vessels,
- nerves and
- lymphatics.

Generally the pulmonary artery is superior in the lung root, the pulmonary veins are inferior and the bronchi are somewhat posterior in position.

In the mediastinum, the vagus nerves pass immediately posteriorly to the lung roots, while the phrenic nerves pass immediately anterior to them.

On the right side, the lobar bronchus to the superior lobe branches from the main bronchus in the root, whereas on the left, it branches within the lung itself.

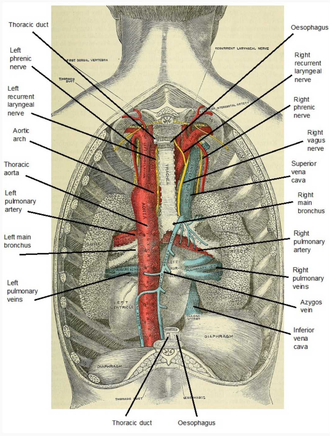


Modified by FRCEM Success. Original by Gray, Henry, 1825-1861; Carter, H. V. (Henry Vandyke), 1831-1897; Pick, T. Pickering (Thomas Pickering), 1841-1919 [No restrictions], via Wikimedia Commons

**Relations**

The medial surface of the right lung lies adjacent to:

- the heart
- the inferior vena cava
- the superior vena cava
- the azygos vein
- the oesophagus

The medial surface of the left lung lies adjacent to:

- the heart
- the aortic arch
- the thoracic aorta
- the oesophagus.

The right and left subclavian arteries and veins arch over and are related to the superior lobe of the right and left lung as they pass over the dome of the cervical pleura and into the axilla.

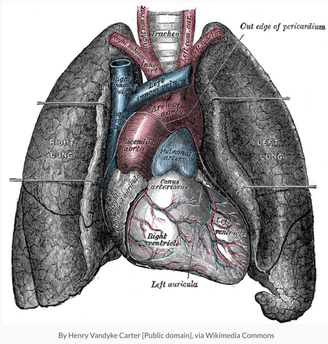


By Henry Vandyke Carter [Public domain], via Wikimedia Commons

**Blood supply**

The right and left pulmonary arteries originate from the pulmonary trunk (at the vertebral level T4/T5) and carry deoxygenated blood to the lungs.

On each side a superior and inferior pulmonary vein carries oxygenated blood from the lungs back to the heart.

The bronchi (down to the terminal bronchioles), lung roots, visceral pleura and supporting lung tissues receive their nutrient blood supply from the bronchial arteries, which arise from the descending aorta.

**Lymphatics**

Lymph from the lungs drains via hilar, tracheobronchial and mediastinal lymph nodes.

**Innervation**

The nerve supply to the lungs is from the anterior and posterior pulmonary plexus (networks of nerves derived from the sympathetic trunk and vagus nerve).

The parasympathetic nerve supply, carried by the vagus nerve, stimulates secretion from the bronchial glands, contraction of bronchial smooth muscle, and vasodilation of the pulmonary vessels. The vagus nerve also carries afferent fibres of pain, cough reflex and stretch of the lung (during inspiration).

The sympathetic nerve supply stimulates relaxation of bronchial smooth muscle, and vasoconstriction of the pulmonary vessels.

< Previous | Next >

Something wrong?

## Question Navigator

1 Answered
2 Answered
3 Answered
4 Answered
5 Answered
6 Answered
7 Answered
8 Answered
9 Answered
10 Answered
11 Answered
12 Answered



©2014 - 2017 FRCEM Success | Website designed & hosted by Cyberfrog Design

# Anatomy: Thorax

Question 75 of 134

## Which of the following best describes the surface marking of the aortic valve:

a Posterior to the right half of the sternum at the level of the fourth intercostal space

b Posterior to the left half of the sternum at the level of the fourth costal cartilage

c Posterior to the third left chondrosternal joint

d Posterior to the left half of the sternum at the level of the third intercostal space

e Posterior to the right half of the sternum at the level of the third costal cartilage

< Previous | Next > | See Answer

Something wrong?

## Question Navigator

1 Answered
2 Answered
3 Answered
4 Answered
5 Answered
6 Answered
7 Answered
8 Answered
9 Answered
10 Answered
11 Answered
12 Answered



©2014 - 2017 FRCEM Success | Website designed & hosted by Cyberfrog Design

# Anatomy: Thorax

Question 75 of 134

Which of the following best describes the surface marking of the aortic valve:

a) Posterior to the right half of the sternum at the level of the fourth intercostal space
b) Posterior to the left half of the sternum at the level of the fourth costal cartilage
c) Posterior to the third left chondrosternal joint
d) **Posterior to the left half of the sternum at the level of the third intercostal space** ✔
e) Posterior to the right half of the sternum at the level of the third costal cartilage

## Answer

The aortic valve is located posterior to the left half of the sternum at the level of the third intercostal space.

## Notes

| Heart valve | Surface marking | Auscultation position |
|---|---|---|
| Tricuspid valve | Posterior to right half of sternum at level of 4th ICS | Left of sternum near 5th ICS |
| Mitral valve | Posterior to left half of sternum at level of 4th costal cartilage | Left 5th ICS in midclavicular line |
| Pulmonary valve | Posterior to third left chondrosternal joint | Medial end of left 2nd ICS |
| Aortic valve | Posterior to left half of sternum at level of 3rd ICS | Medial end of right 2nd ICS |

**Surface marking of heart valves**

- The tricuspid valve is located posterior to the right half of the sternum at the level of the fourth intercostal space.
- The mitral valve is located posterior to the left half of the sternum at the level of the fourth costal cartilage.
- The pulmonary valve is located posterior to the third left chondrosternal joint.
- The aortic valve is located posterior to the left half of the sternum at the level of the third intercostal space.

**Auscultation positions of heart valves**

Heart valves should be auscultated by positioning the stethoscope downstream from the flow of blood through the valves.

- The tricuspid valve is heard just to the left of the lower part of the sternum near the fifth intercostal space.
- The mitral valve is heard over the apex of the heart in the left fifth intercostal space at the midclavicular line.
- The pulmonary valve is heard over the medial end of the left second intercostal space.
- The aortic valve is heard over the medial end of the right second intercostal space.

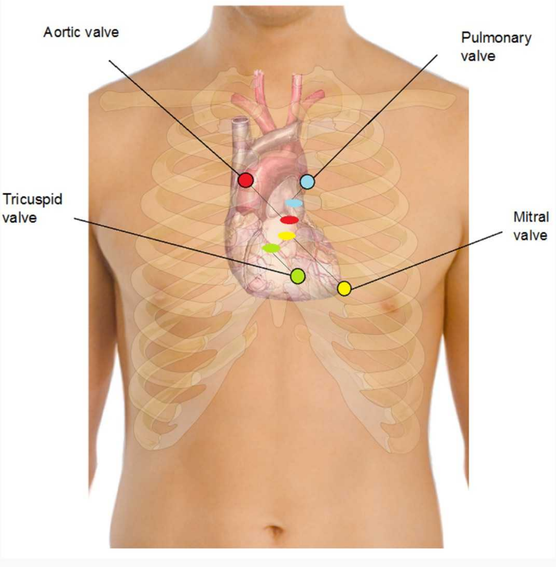


Modified by FRCEM Success. Original by Mikael Häggström [Public domain], via Wikimedia Commons

< Previous | Next > | Something wrong?

## Question Navigator

1 Answered
2 Answered
3 Answered
4 Answered
5 Answered
6 Answered
7 Answered
8 Answered
9 Answered
10 Answered
11 Answered
12 Answered



©2014 - 2017 FRCEM Success | Website designed & hosted by Cyberfrog Design

# Anatomy: Thorax

Question 76 of 134

## The right pulmonary surface of the heart is formed predominantly by which of the following:

a Right atrium

b Left atrium

c Right ventricle

d Left ventricle

e Great vessels

< Previous | Next > | See Answer

Something wrong?

## Question Navigator

1 Answered
2 Answered
3 Answered
4 Answered
5 Answered
6 Answered
7 Answered
8 Answered
9 Answered
10 Answered
11 Answered
12 Answered



©2014 - 2017 FRCEM Success | Website designed & hosted by Cyberfrog Design

# Anatomy: Thorax

Question 76 of 134

The right pulmonary surface of the heart is formed predominantly by which of the following:

a) **Right atrium** ✔
b) Left atrium
c) Right ventricle
d) Left ventricle
e) Great vessels

## Answer

The right pulmonary surface consists of the right atrium.

## Notes

| Border/Surface | Main structure (contributing structures) |
|---|---|
| Apex | Left ventricle |
| Base | Left atrium (right atrium, proximal great veins) |
| Anterior surface | Right ventricle (right atrium, left ventricle) |
| Inferior surface | Left and right ventricle |
| Left pulmonary surface | Left ventricle (left atrium) |
| Right pulmonary surface | Right atrium |
| Inferior border | Right ventricle (left ventricle) |
| Left border | Left ventricle (left auricle) |
| Right border | Right atrium |
| Superior border | Both atria, roots of great vessels |

The general shape and orientation of the heart are that of a pyramid that has fallen over and is resting on one of its sides.

- The apex of this pyramid projects forwards, downwards and to the left. The apex is formed by the inferolateral part of the left ventricle and is positioned deep to the left fifth intercostal space in the midclavicular line.
- The base is facing posteriorly. The base is formed mostly by the left atrium with a small portion of the right atrium and the proximal part of the great veins, and is fixed posteriorly to the pericardial wall, opposite the bodies of the T5 – T8 vertebrae (T6 – T9 when standing). The oesophagus lies immediately posterior to the base.

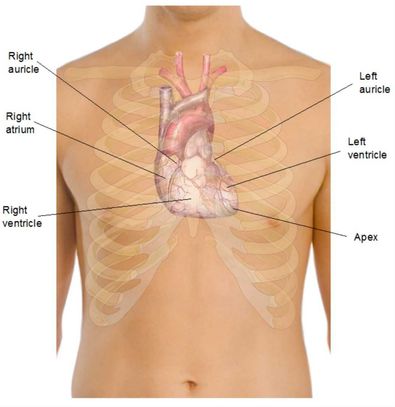


Modified by FRCEM Success. Original by Mikael Häggström (See above. All used images are in public domain.) [Public domain], via Wikimedia Commons

**Surfaces**

There are four surfaces to the upturned pyramid:

- The anterior (sternocostal) surface consists mostly of the right ventricle with some of the right atrium and some of the left ventricle.
- The inferior (diaphragmatic) surface consists of the left ventricle with a small portion of the right ventricle separated by the posterior interventricular groove.
- The left pulmonary surface consists mainly of the left ventricle and a portion of the left atrium.
- The right pulmonary surface consists of the right atrium.

**Borders**

There are four main borders separating the surfaces of the heart:

- The inferior border is formed mostly by the right ventricle and a small portion of the left ventricle near the apex.
- The left border is formed mostly by the left ventricle with a small portion of the left auricle.
- The right border is formed by the right atrium.
- The superior border is formed by both atria and the roots of the great vessels.

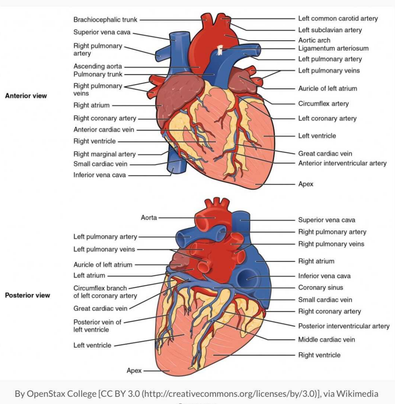


By OpenStax College [CC BY 3.0 (http://creativecommons.org/licenses/by/3.0)], via Wikimedia Commons

< Previous | Next >

Something wrong?

## Question Navigator

1 Answered
2 Answered
3 Answered
4 Answered
5 Answered
6 Answered
7 Answered
8 Answered
9 Answered
10 Answered
11 Answered
12 Answered



©2014 - 2017 FRCEM Success | Website designed & hosted by Cyberfrog Design

# Anatomy: Thorax

Question 77 of 134

## The medial surface of the right lung lies adjacent to all of the following structures except for the:

a Aortic arch

b Inferior vena cava

c Superior vena cava

d Azygos vein

e Oesophagus

< Previous | Next > | See Answer

Something wrong?

## Question Navigator

1 Answered
2 Answered
3 Answered
4 Answered
5 Answered
6 Answered
7 Answered
8 Answered
9 Answered
10 Answered
11 Answered
12 Answered



©2014 - 2017 FRCEM Success | Website designed & hosted by Cyberfrog Design

# Anatomy: Thorax

Question 77 of 134

The medial surface of the right lung lies adjacent to all of the following structures except for the:

**a) Aortic arch** ✔
**b)** Inferior vena cava
**c)** Superior vena cava
**d)** Azygos vein
**e)** Oesophagus

## Answer

The medial surface of the right lung lies adjacent to:

- the heart
- the inferior vena cava
- the superior vena cava
- the azygos vein
- the oesophagus.

## Notes

The lungs lie on either side of the mediastinum, each surrounded by a pleural cavity. They are suspended from the mediastinum by the root of the lung, a short tubular collection of structures.

**Lung root**

The root is lined by a layer of mediastinal pleura that reflects onto the surface of the lungs as visceral pleura. The region outlined by this pleural reflection on the medial surface of the lung is the hilum, where structures enter and leave.

The hila are located at the level of the 3rd – 4th costal cartilage anteriorly, and the T5 – T7 vertebrae posteriorly.

Each lung root contains:

- a pulmonary artery
- two pulmonary veins
- a main bronchus
- bronchial vessels,
- nerves and
- lymphatics.

Generally the pulmonary artery is superior in the lung root, the pulmonary veins are inferior and the bronchi are somewhat posterior in position.

In the mediastinum, the vagus nerves pass immediately posteriorly to the lung roots, while the phrenic nerves pass immediately anterior to them.

On the right side, the lobar bronchus to the superior lobe branches from the main bronchus in the root, whereas on the left, it branches within the lung itself.

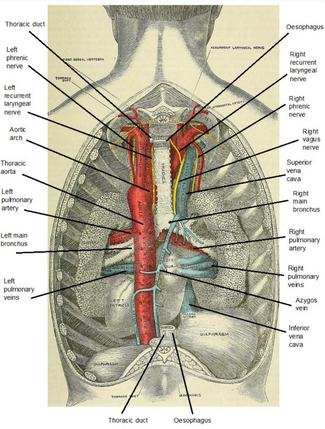


Modified by FRCEM Success. Original by Gray, Henry, 1825-1861; Carter, H. V. (Henry Vandyke), 1831-1897; Pick, T. Pickering (Thomas Pickering), 1841-1919 [No restrictions], via Wikimedia Commons

**Relations**

The medial surface of the right lung lies adjacent to:

- the heart
- the inferior vena cava
- the superior vena cava
- the azygos vein
- the oesophagus

The medial surface of the left lung lies adjacent to:

- the heart
- the aortic arch
- the thoracic aorta
- the oesophagus.

The right and left subclavian arteries and veins arch over and are related to the superior lobe of the right and left lung as they pass over the dome of the cervical pleura and into the axilla.

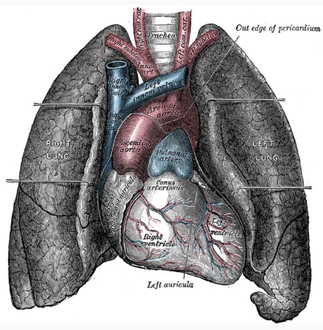


By Henry Vandyke Carter [Public domain], via Wikimedia Commons

**Blood supply**

The right and left pulmonary arteries originate from the pulmonary trunk (at the vertebral level T4/T5) and carry deoxygenated blood to the lungs.

On each side a superior and inferior pulmonary vein carries oxygenated blood from the lungs back to the heart.

The bronchi (down to the terminal bronchioles), lung roots, visceral pleura and supporting lung tissues receive their nutrient blood supply from the bronchial arteries, which arise from the descending aorta.

**Lymphatics**

Lymph from the lungs drains via hilar, tracheobronchial and mediastinal lymph nodes.

**Innervation**

The nerve supply to the lungs is from the anterior and posterior pulmonary plexus (networks of nerves derived from the sympathetic trunk and vagus nerve).

The parasympathetic nerve supply, carried by the vagus nerve, stimulates secretion from the bronchial glands, contraction of bronchial smooth muscle, and vasodilation of the pulmonary vessels. The vagus nerve also carries afferent fibres of pain, cough reflex and stretch of the lung (during inspiration).

The sympathetic nerve supply stimulates relaxation of bronchial smooth muscle, and vasoconstriction of the pulmonary vessels.

< Previous | Next >

Something wrong?

## Question Navigator

1 Answered
2 Answered
3 Answered
4 Answered
5 Answered
6 Answered
7 Answered
8 Answered
9 Answered
10 Answered
11 Answered
12 Answered



©2014 - 2017 FRCEM Success | Website designed & hosted by Cyberfrog Design

# Anatomy: Thorax

Question 78 of 134

## Regarding the oesophagus, which of the following statements is CORRECT:

a The oesophagus passes immediately posterior to the right atrium separated from it only by pericardium.

b The aortic arch lies posterior to the oesophagus.

c The thoracic aorta lies to the right of the oesophagus.

d The right main bronchus lies immediately anterior to the oesophagus.

e The upper oesophageal sphincter is formed by the cricopharyngeus muscle.

< Previous | Next > | See Answer

Something wrong?

Question Navigator

1 Answered
2 Answered
3 Answered
4 Answered
5 Answered
6 Answered
7 Answered
8 Answered
9 Answered
10 Answered
11 Answered
12 Answered



©2014 - 2017 FRCEM Success | Website designed & hosted by Cyberfrog Design

# Anatomy: Thorax

Question 78 of 134

Regarding the oesophagus, which of the following statements is CORRECT:

**a)**
The oesophagus passes immediately posterior to the right atrium separated from it only by pericardium.
**b)** The aortic arch lies posterior to the oesophagus.
**c)** The thoracic aorta lies to the right of the oesophagus.
**d)** The right main bronchus lies immediately anterior to the oesophagus.
**e)** **The upper oesophageal sphincter is formed by the cricopharyngeus muscle.** ✔

## Answer

The upper oesophageal sphincter formed by the cricopharyngeus muscle in the pharynx is the first main constriction of the oesophagus. Superiorly the thoracic aorta lies to the left of the oesophagus. As it approaches the diaphragm, the oesophagus moves anteriorly and to the left, crossing from the right side of the thoracic aorta to eventually assume a position anterior to it, before passing through the diaphragm. The oesophagus is crossed anteriorly by the aortic arch. Anterior to the oesophagus below the tracheal bifurcation are the right pulmonary artery and the left main bronchus. The oesophagus passes immediately posterior to the left atrium.

## Notes

### Anatomical extent

The oesophagus is a muscular tube passing between the pharynx in the neck and the stomach in the abdomen. The oesophagus begins at the inferior border of the cricoid cartilage opposite vertebra C6, pierces the diaphragm at the esophageal hiatus at T10 and ends at the cardiac opening of the stomach opposite vertebra T11.

### Structure

The oesophagus consists of an internal circular and external longitudinal layer of muscle. The external longitudinal layer is comprised of different muscle types in each third of the oesophagus; superior third – voluntary striated muscle, middle third – voluntary striated and smooth muscle and inferior third – smooth muscle.

### Relations

The oesophagus descends on the anterior aspect of the bodies of the vertebrae, immediately posterior to the trachea and the recurrent laryngeal nerves, generally in the midline position. The oesophagus is crossed anteriorly by the aortic arch. As it approaches the diaphragm, the oesophagus moves anteriorly and to the left, crossing from the right side of the thoracic aorta to eventually assume a position anterior to it, before passing through the diaphragm.

Posterior to the oesophagus, the thoracic duct is on the right side inferiorly but crosses to the left more superiorly (at T5). Other structures posteriorly include portions of the hemiazygos veins and the right posterior intercostal vessels.

Anterior to the oesophagus below the tracheal bifurcation are the right pulmonary artery and the left main bronchus. The oesophagus then passes immediately posterior to the left atrium, separated from it only by pericardium. Inferior to the left atrium, the oesophagus is related to the diaphragm.

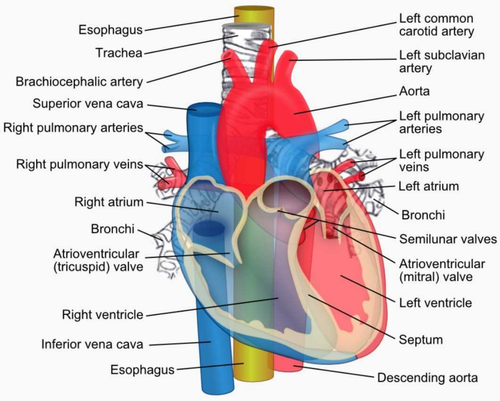


ZooFari [CC BY-SA 3.0 (http://creativecommons.org/licenses/by-sa/3.0)], via Wikimedia Commons

### Points of constriction

As the oesophagus is a flexible muscular tube, it is compressed by surrounding structures at four locations:

- 1) the junction of the oesophagus with the pharynx in the neck (upper oesophageal sphincter formed by the cricopharyngeus muscle)
- 2) in the superior mediastinum where the oesophagus is crossed by the arch of the aorta
- 3) in the posterior mediastinum where the oesophagus is compressed by the left main bronchus
- 4) in the posterior mediastinum at the oesophageal hiatus in the diaphragm.

Clinically these compressions are important when passing instruments or assessing swallowed objects.

### Innervation

Oesophageal innervation is complex, oesophageal branches arise from the vagus nerves and sympathetic trunks. The visceral afferents that pass through the sympathetic trunks and the splanchnic nerves are the primary participants in detection of oesophageal pain and transmission of this information to various levels of the central nervous system.

< Previous | Next >

Something wrong?

## Question Navigator

1 Answered
2 Answered
3 Answered
4 Answered
5 Answered
6 Answered
7 Answered
8 Answered
9 Answered
10 Answered
11 Answered
12 Answered



©2014 - 2017 FRCEM Success | Website designed & hosted by Cyberfrog Design

# Anatomy: Thorax

Question 79 of 134

## Somatic sensation from the parietal pericardium is carried in which of the following nerves:

a Sympathetic trunk

b Vagus nerve

c Phrenic nerve

d Thoracic splanchnic nerves

e Cervical splanchnic nerves

< Previous | Next > | See Answer

Something wrong?

Question Navigator

1 Answered
2 Answered
3 Answered
4 Answered
5 Answered
6 Answered
7 Answered
8 Answered
9 Answered
10 Answered
11 Answered
12 Answered



©2014 - 2017 FRCEM Success | Website designed & hosted by Cyberfrog Design

# Anatomy: Thorax

Question 79 of 134

Somatic sensation from the parietal pericardium is carried in which of the following nerves:

**a)** Sympathetic trunk
**b)** Vagus nerve ✗
**c)** Phrenic nerve ✓
**d)** Thoracic splanchnic nerves
**e)** Cervical splanchnic nerves

## Answer

Somatic sensation from the parietal pericardium is carried by somatic afferent fibres in the phrenic nerves (C3 – C5); it is for this reason that pain related to a pericardial problem may be referred to the supraclavicular region of the shoulder or the lateral neck area dermatomes for spinal cord segments C3 – C5.

## Notes

The pericardium is a fibroserous sac surrounding the heart and the roots of the great vessels in the middle mediastinum. It is composed of two main layers; the fibrous pericardium and the serous pericardium.

**Serous pericardium**

The serous pericardium itself is divided into two parts which are continuous at the roots of the great vessels; the parietal layer which lines the inner surface of the fibrous pericardium and the visceral layer which lines the heart itself.

The parietal and visceral layer of serous pericardium are separated by the pericardial cavity which normally contains a small amount of lubricating serous fluid which reduces friction during normal movement of the heart.

**Fibrous pericardium**

The fibrous pericardium is a tough, inelastic sheath which fixes the heart in position (through its attachments to the central tendon of the diaphragm, the sternum and the tunica adventitia of the great vessels) and prevents sudden overfilling and distension of the heart.

Cardiac tamponade is acute compression of the heart caused by rapid accumulation of fluid or blood in the pericardial cavity from trauma (to the heart, great vessels or pericardial vessels) or pericardial effusion. The inflexibility of the fibrous pericardium results in increased intrapericardial pressure, with subsequent compression of venous return and reduced cardiac output.

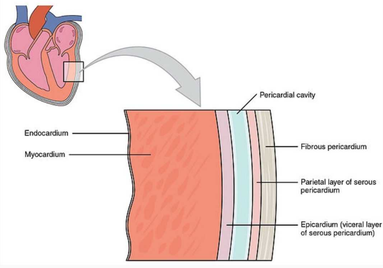


By OpenStax College [CC BY 3.0 (http://creativecommons.org/licenses/by/3.0)], via Wikimedia Commons

**Innervation**

The pericardium receives its nerve supply from the vagus nerve, the sympathetic trunks and the phrenic nerves.

Somatic sensation from the parietal pericardium is carried by somatic afferent fibres in the phrenic nerves (C3 – C5); it is for this reason that pain related to a pericardial problem may be referred to the supraclavicular region of the shoulder or the lateral neck area dermatomes for spinal cord segments C3 – C5.

**Pericardial aspiration (pericardiocentesis)**

Pericardiocentesis is a surgical puncture of the pericardial cavity for the aspiration of fluid, which is necessary to relieve the pressure of accumulated fluid in the heart.

A needle is inserted into the pericardial cavity 1 – 2 cm inferior to the left of the xiphochondral junction (between the xiphisternum and the left costal margin) at a 45 degree angle and advanced aiming toward the tip of the left scapula (site marked by cross in image below).

Complications of pericardiocentesis include:

- Aspiration of ventricular blood instead of pericardial blood
- Laceration of ventricular epicardium or myocardium
- Laceration of coronary artery or vein
- Ventricular fibrillation
- Pneumothorax secondary to lung puncture
- Puncture of great vessels with worsening pericardial tamponade
- Mediastinitis secondary to oesophageal puncture

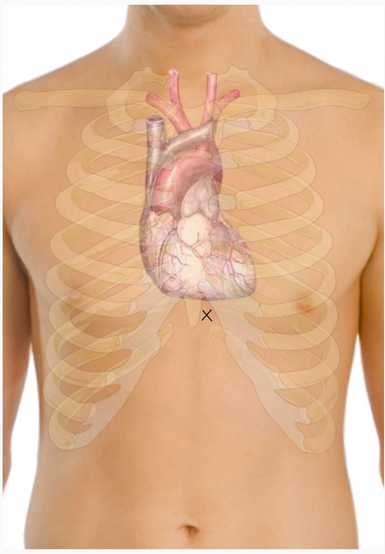

Modified by FRCEM Success. Original by Mikael Häggström (See above. All used images are in public domain.) [Public domain], via Wikimedia Commons

## Question Navigator

1 Answered
2 Answered
3 Answered
4 Answered
5 Answered
6 Answered
7 Answered
8 Answered
9 Answered
10 Answered
11 Answered
12 Answered

< Previous | Next >

Something wrong?



©2014 - 2017 FRCEM Success | Website designed & hosted by Cyberfrog Design

# Anatomy: Thorax

Question 80 of 134

## The trachea bifurcates into the right and left main bronchi at which vertebral level:

a T2/T3

b T3/T4

c T4/T5

d T5/T6

e T6/T7

< Previous | Next > | See Answer

Something wrong?

Question Navigator

1 Answered
2 Answered
3 Answered
4 Answered
5 Answered
6 Answered
7 Answered
8 Answered
9 Answered
10 Answered
11 Answered
12 Answered



©2014 - 2017 FRCEM Success | Website designed & hosted by Cyberfrog Design

# Anatomy: Thorax

Question 80 of 134

The trachea bifurcates into the right and left main bronchi at which vertebral level:

**a)** T2/T3
**b)** T3/T4
**c)** **T4/T5** ✔
**d)** T5/T6
**e)** T6/T7

## Answer

The trachea bifurcates into the right and left main bronchi in the thoracic plane, at the level of the sternal angle and vertebra T4/T5.

## Notes

The trachea arises at the lower border of the cricoid cartilage in the neck, as a continuation of the larynx. It extends from vertebral level C6 to T4/T5 at which point it bifurcates into the right and left main bronchi (at the level of the sternal angle).

The trachea is formed anteriorly by 15 – 20 C-shaped rings of hyaline cartilage which mechanically hold the airway open whilst allowing it flexibility. The trachealis muscle connects the ends of the incomplete rings and forms the posterior wall of the trachea. The trachealis muscle is able to constrict the trachea, allowing air to be expelled with more force e.g. during coughing.

The trachea and bronchi are lined by ciliated pseudostratified columnar epithelium, interspersed by mucus-producing goblet cells. This mucous membrane functions as the mucociliary escalator, trapping particles in sticky mucus and sweeping it along the airway.

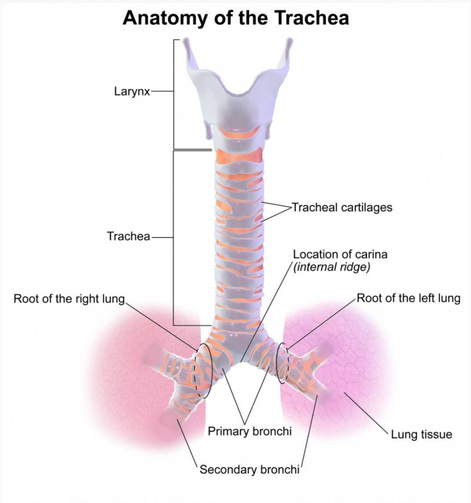


By Blausen.com staff. "Blausen gallery 2014". Wikiversity Journal of Medicine. DOI:10.15347/wjm/2014.010. ISSN 20018762. (Own work) [CC BY 3.0 (http://creativecommons.org/licenses/by/3.0)], via Wikimedia Commons

**Relations**

The trachea descends anterior to the oesophagus and inclines slightly to the right.

In the thorax, anteriorly it is related to:

- the thymic remnants
- the left brachiocephalic vein
- the aortic arch
- the brachiocephalic trunk
- the left common carotid artery
- the deep cardiac plexus.

Laterally it is related to:

- the pleura, the right vagus nerve and the brachiocephalic trunk on the right
- the left recurrent laryngeal nerve, the aortic arch and the left common carotid and subclavian vessels on the left.

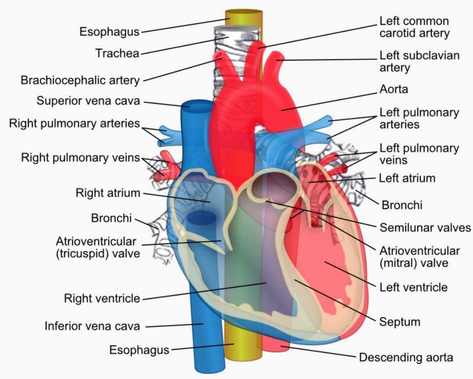


ZooFari [CC BY-SA 3.0 (http://creativecommons.org/licenses/by-sa/3.0)], via Wikimedia Commons

< Previous | Next >

Something wrong?

## Question Navigator

1 Answered
2 Answered
3 Answered
4 Answered
5 Answered
6 Answered
7 Answered
8 Answered
9 Answered
10 Answered
11 Answered
12 Answered



©2014 - 2017 FRCEM Success | Website designed & hosted by Cyberfrog Design

# Anatomy: Thorax

Question 81 of 134

## The apex of the heart is formed predominantly by which of the following:

a Right atrium

b Left atrium

c Right ventricle

d Left ventricle

e Great veins

< Previous | Next > | See Answer

Something wrong?

Question Navigator

1 Answered
2 Answered
3 Answered
4 Answered
5 Answered
6 Answered
7 Answered
8 Answered
9 Answered
10 Answered
11 Answered
12 Answered



©2014 - 2017 FRCEM Success | Website designed & hosted by Cyberfrog Design

# Anatomy: Thorax

Question 81 of 134

The apex of the heart is formed predominantly by which of the following:

**a)** Right atrium
**b)** Left atrium
**c)** Right ventricle
**d)** **Left ventricle** ✔
**e)** Great veins

## Answer

The apex of the heart projects forwards, downwards and to the left. The apex is formed by the inferolateral part of the left ventricle and is positioned deep to the left fifth intercostal space in the midclavicular line.

## Notes

| Border/Surface | Main structure (contributing structures) |
|---|---|
| Apex | Left ventricle |
| Base | Left atrium (right atrium, proximal great veins) |
| Anterior surface | Right ventricle (right atrium, left ventricle) |
| Inferior surface | Left and right ventricle |
| Left pulmonary surface | Left ventricle (left atrium) |
| Right pulmonary surface | Right atrium |
| Inferior border | Right ventricle (left ventricle) |
| Left border | Left ventricle (left auricle) |
| Right border | Right atrium |
| Superior border | Both atria, roots of great vessels |

The general shape and orientation of the heart are that of a pyramid that has fallen over and is resting on one of its sides.

- The apex of this pyramid projects forwards, downwards and to the left. The apex is formed by the inferolateral part of the left ventricle and is positioned deep to the left fifth intercostal space in the midclavicular line.
- The base is facing posteriorly. The base is formed mostly by the left atrium with a small portion of the right atrium and the proximal part of the great veins, and is fixed posteriorly to the pericardial wall, opposite the bodies of the T5 – T8 vertebrae (T6 – T9 when standing). The oesophagus lies immediately posterior to the base.

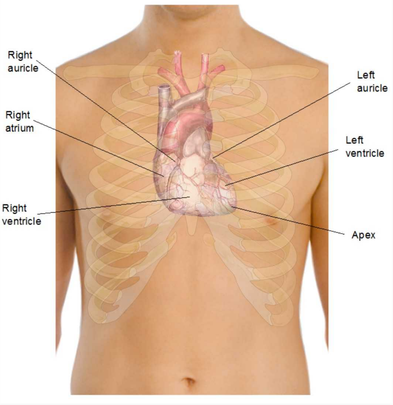


Modified by FRCEM Success. Original by Mikael Häggström (See above. All used images are in public domain.) [Public domain], via Wikimedia Commons

**Surfaces**

There are four surfaces to the upturned pyramid:

- The anterior (sternocostal) surface consists mostly of the right ventricle with some of the right atrium and some of the left ventricle.
- The inferior (diaphragmatic) surface consists of the left ventricle with a small portion of the right ventricle separated by the posterior interventricular groove.
- The left pulmonary surface consists mainly of the left ventricle and a portion of the left atrium.
- The right pulmonary surface consists of the right atrium.

**Borders**

There are four main borders separating the surfaces of the heart:

- The inferior border is formed mostly by the right ventricle and a small portion of the left ventricle near the apex.
- The left border is formed mostly by the left ventricle with a small portion of the left auricle.
- The right border is formed by the right atrium.
- The superior border is formed by both atria and the roots of the great vessels.

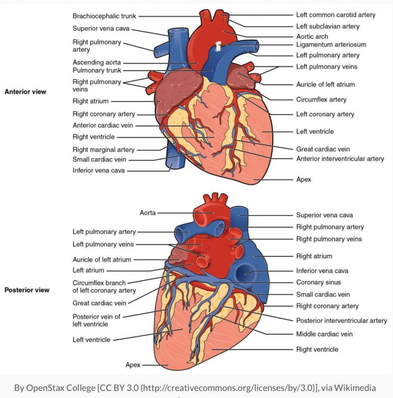


By OpenStax College [CC BY 3.0 (http://creativecommons.org/licenses/by/3.0)], via Wikimedia Commons

< Previous | Next >

Something wrong?

## Question Navigator

1 Answered
2 Answered
3 Answered
4 Answered
5 Answered
6 Answered
7 Answered
8 Answered
9 Answered
10 Answered
11 Answered
12 Answered



©2014 - 2017 FRCEM Success | Website designed & hosted by Cyberfrog Design

# Anatomy: Thorax

Question 82 of 134

## The hila of the lungs are located at which of the following vertebral levels:

a T3 – T4

b T4 – T5

c T5 – T6

d T5 – T7

e T6 – T7

< Previous | Next > | See Answer

Something wrong?

Question Navigator

1 Answered
2 Answered
3 Answered
4 Answered
5 Answered
6 Answered
7 Answered
8 Answered
9 Answered
10 Answered
11 Answered
12 Answered



©2014 - 2017 FRCEM Success | Website designed & hosted by Cyberfrog Design

# Anatomy: Thorax

Question 82 of 134

The hila of the lungs are located at which of the following vertebral levels:

**a)** T3 – T4
**b)** T4 – T5
**c)** T5 – T6
**d)** **T5 – T7** ✔
**e)** T6 – T7

## Answer

The hila are located at the level of the 3rd – 4th costal cartilage anteriorly, and the T5 – T7 vertebrae posteriorly.

## Notes

The lungs lie on either side of the mediastinum, each surrounded by a pleural cavity. They are suspended from the mediastinum by the root of the lung, a short tubular collection of structures.

**Lung root**

The root is lined by a layer of mediastinal pleura that reflects onto the surface of the lungs as visceral pleura. The region outlined by this pleural reflection on the medial surface of the lung is the hilum, where structures enter and leave.

The hila are located at the level of the 3rd – 4th costal cartilage anteriorly, and the T5 – T7 vertebrae posteriorly.

Each lung root contains:

- a pulmonary artery
- two pulmonary veins
- a main bronchus
- bronchial vessels,
- nerves and
- lymphatics.

Generally the pulmonary artery is superior in the lung root, the pulmonary veins are inferior and the bronchi are somewhat posterior in position.

In the mediastinum, the vagus nerves pass immediately posteriorly to the lung roots, while the phrenic nerves pass immediately anterior to them.

On the right side, the lobar bronchus to the superior lobe branches from the main bronchus in the root, whereas on the left, it branches within the lung itself.

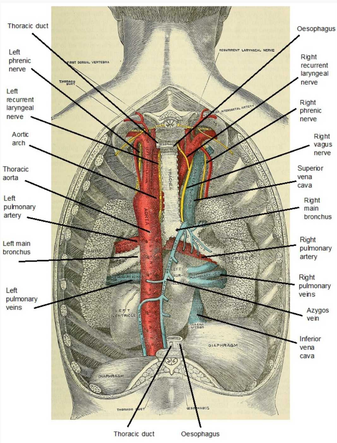


Modified by FRCEM Success. Original by Gray, Henry, 1825-1861; Carter, H. V. (Henry Vandyke), 1831-1897; Pick, T. Pickering (Thomas Pickering), 1841-1919 [No restrictions], via Wikimedia Commons

**Relations**

The medial surface of the right lung lies adjacent to:

- the heart
- the inferior vena cava
- the superior vena cava
- the azygos vein
- the oesophagus

The medial surface of the left lung lies adjacent to:

- the heart
- the aortic arch
- the thoracic aorta
- the oesophagus.

The right and left subclavian arteries and veins arch over and are related to the superior lobe of the right and left lung as they pass over the dome of the cervical pleura and into the axilla.

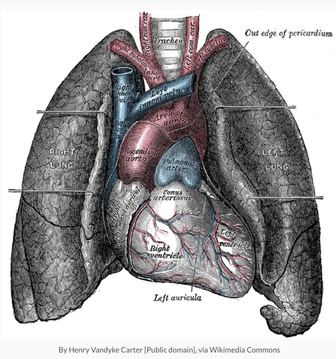


By Henry Vandyke Carter [Public domain], via Wikimedia Commons

**Blood supply**

The right and left pulmonary arteries originate from the pulmonary trunk (at the vertebral level T4/T5) and carry deoxygenated blood to the lungs.

On each side a superior and inferior pulmonary vein carries oxygenated blood from the lungs back to the heart.

The bronchi (down to the terminal bronchioles), lung roots, visceral pleura and supporting lung tissues receive their nutrient blood supply from the bronchial arteries, which arise from the descending aorta.

**Lymphatics**

Lymph from the lungs drains via hilar, tracheobronchial and mediastinal lymph nodes.

**Innervation**

The nerve supply to the lungs is from the anterior and posterior pulmonary plexus (networks of nerves derived from the sympathetic trunk and vagus nerve).

The parasympathetic nerve supply, carried by the vagus nerve, stimulates secretion from the bronchial glands, contraction of bronchial smooth muscle, and vasodilation of the pulmonary vessels. The vagus nerve also carries afferent fibres of pain, cough reflex and stretch of the lung (during inspiration).

The sympathetic nerve supply stimulates relaxation of bronchial smooth muscle, and vasoconstriction of the pulmonary vessels.

< Previous | Next >

Something wrong?

## Question Navigator

1 Answered
2 Answered
3 Answered
4 Answered
5 Answered
6 Answered
7 Answered
8 Answered
9 Answered
10 Answered
11 Answered
12 Answered



©2014 - 2017 FRCEM Success | Website designed & hosted by Cyberfrog Design

# Anatomy: Thorax

Question 83 of 134

## False ribs are defined by which of the following features:

a The head of the rib has only one articular facet

b The rib has no neck

c Anteriorly, the rib attaches to the costal cartilage of the rib above it

d The rib is shorter and wider than the other ribs

e Anteriorly, the rib does not attach to the sternum

< Previous | Next > | See Answer

Something wrong?

Question Navigator

1 Answered
2 Answered
3 Answered
4 Answered
5 Answered
6 Answered
7 Answered
8 Answered
9 Answered
10 Answered
11 Answered
12 Answered



©2014 - 2017 FRCEM Success | Website designed & hosted by Cyberfrog Design

# Anatomy: Thorax

Question 83 of 134

False ribs are defined by which of the following features:

a) The head of the rib has only one articular facet
b) The rib has no neck
c) Anteriorly, the rib attaches to the costal cartilage of the rib above it
d) The rib is shorter and wider than the other ribs
e) **Anteriorly, the rib does not attach to the sternum** ✔

## Answer

The false ribs (8 – 12) are distinguished by their lack of anterior attachment to the sternum. The false ribs (8 – 12) can be further divided into those that attach to the costal cartilage of the rib above them (8 – 10) and the floating ribs (11 + 12) that do not have any anterior attachments.

## Notes

There are twelve pairs of ribs, each terminating anteriorly in a costal cartilage.

**True and False ribs**

The ribs are divided into 'true' and 'false' ribs based on their anterior attachments:

- The true ribs (1 – 7) attach directly to the sternum anteriorly.
- The false ribs (8 – 12) can be further divided into those that attach to the costal cartilage of the rib above them (8 – 10) and the floating ribs (11 + 12) that do not have any anterior attachments.

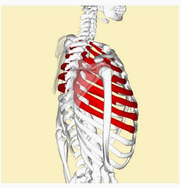

By Anatomography (en:Anatomography (setting page of this image)) [CC BY-SA 2.1 jp (http://creativecommons.org/licenses/by-sa/2.1/jp/deed.en)], via Wikimedia Commons

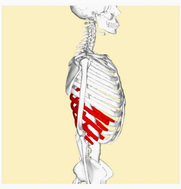

By Anatomography (en:Anatomography (setting page of this image)) [CC BY-SA 2.1 jp (http://creativecommons.org/licenses/by-sa/2.1/jp/deed.en)], via Wikimedia Commons

**Thoracic vertebrae**

Posteriorly, all of the ribs articulate with the thoracic vertebrae of the spine.

Each typical rib forms two joints posteriorly:

- the costotransverse joint (between the tubercle of the rib and the transverse process of the corresponding vertebra)
- the costovertebral joint (between the two facets on the head of the rib and the superior costal facet on the body of the corresponding vertebra, and the inferior costal facet on the body of the vertebra above).

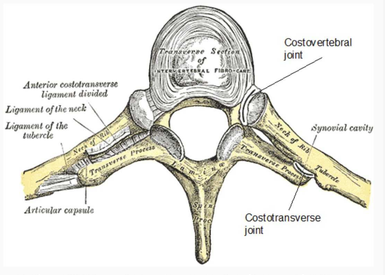


Modified by FRCEM Success. Original by Henry Vandyke Carter [Public domain], via Wikimedia Commons

**Typical ribs**

The typical rib consists of a head, a neck and a body:

- The head of the rib has two articular facets which articulate with the superior costal facet on the body of the corresponding vertebra, and the inferior costal facet on the body of the vertebra above.
- The neck of the rib connects the head to the body. Where the neck meets the body, there is a tubercle which articulates with the transverse process of the corresponding vertebra.
- The body of the rib is flat and curved.

The inferior margin of the internal surface of the body is marked by the costal groove which protects the neurovascular structures which run within it.

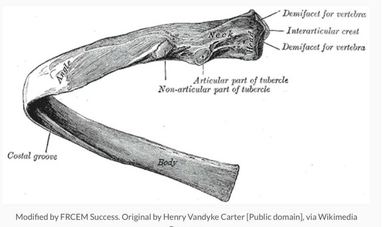


Modified by FRCEM Success. Original by Henry Vandyke Carter [Public domain], via Wikimedia Commons

**Atypical ribs**

The atypical ribs consist of ribs 1, 2, 10, 11 and 12.

| Atypical rib | Features |
|---|---|
| Rib 1 | Shorter and wider, single facet for articulation with T1, scalene tubercle |
| Rib 2 | Flat, roughened area for attachment of serratus anterior muscle |
| Rib 10 | Single facet for articulation with T10 |
| Rib 11 | No neck, single facet for articulation with T11 |
| Rib 12 | No neck, single facet for articulation with T12 |

- Rib 1 is shorter and wider than the other ribs. The head of rib 1 has only one facet for articulation with the body of its own vertebra (T1); it does NOT articulate with vertebra C7. The superior surface of rib 1 is characterised by the scalene tubercle about midway along the body, which separates two smooth grooves in the rib made by the subclavian vein anteriorly and the subclavian artery posteriorly.
- Like rib 1, rib 2 is flat but twice as long. It has a roughened area on its upper surface where the serratus anterior muscle attaches.
- The head of rib 10 only has a single facet for articulation with the body of its own vertebra (T10).
- Ribs 11 and 12 have no neck, and have only one facet for articulation with the bodies of their own vertebrae (T11 and T12).

< Previous | Next >

Something wrong?

## Question Navigator

1 Answered
2 Answered
3 Answered
4 Answered
5 Answered
6 Answered
7 Answered
8 Answered
9 Answered
10 Answered
11 Answered
12 Answered



©2014 - 2017 FRCEM Success | Website designed & hosted by Cyberfrog Design

# Anatomy: Thorax

Question 84 of 134

## The tricuspid valve is best auscultated at which of the following sites:

a Just left of the lower part of the sternum near the fifth intercostal space

b In the left fifth intercostal space at the midclavicular line

c Over the medial end of the left second intercostal space

d Over the medial end of the right second intercostal space

e Just right of the lower part of the sternum near the fourth intercostal space

< Previous | Next > | See Answer

Something wrong?

Question Navigator

1 Answered
2 Answered
3 Answered
4 Answered
5 Answered
6 Answered
7 Answered
8 Answered
9 Answered
10 Answered
11 Answered
12 Answered



©2014 - 2017 FRCEM Success | Website designed & hosted by Cyberfrog Design

# Anatomy: Thorax

Question 84 of 134

The tricuspid valve is best auscultated at which of the following sites:

a) **Just left of the lower part of the sternum near the fifth intercostal space** ✔
b) In the left fifth intercostal space at the midclavicular line
c) Over the medial end of the left second intercostal space
d) Over the medial end of the right second intercostal space
e) Just right of the lower part of the sternum near the fourth intercostal space

## Answer

The tricuspid valve is heard just to the left of the lower part of the sternum near the fifth intercostal space.

## Notes

| Heart valve | Surface marking | Auscultation position |
|---|---|---|
| Tricuspid valve | Posterior to right half of sternum at level of 4th ICS | Left of sternum near 5th ICS |
| Mitral valve | Posterior to left half of sternum at level of 4th costal cartilage | Left 5th ICS in midclavicular line |
| Pulmonary valve | Posterior to third left chondrosternal joint | Medial end of left 2nd ICS |
| Aortic valve | Posterior to left half of sternum at level of 3rd ICS | Medial end of right 2nd ICS |

**Surface marking of heart valves**

- The tricuspid valve is located posterior to the right half of the sternum at the level of the fourth intercostal space.
- The mitral valve is located posterior to the left half of the sternum at the level of the fourth costal cartilage.
- The pulmonary valve is located posterior to the third left chondrosternal joint.
- The aortic valve is located posterior to the left half of the sternum at the level of the third intercostal space.

**Auscultation positions of heart valves**

Heart valves should be auscultated by positioning the stethoscope downstream from the flow of blood through the valves.

- The tricuspid valve is heard just to the left of the lower part of the sternum near the fifth intercostal space.
- The mitral valve is heard over the apex of the heart in the left fifth intercostal space at the midclavicular line.
- The pulmonary valve is heard over the medial end of the left second intercostal space.
- The aortic valve is heard over the medial end of the right second intercostal space.

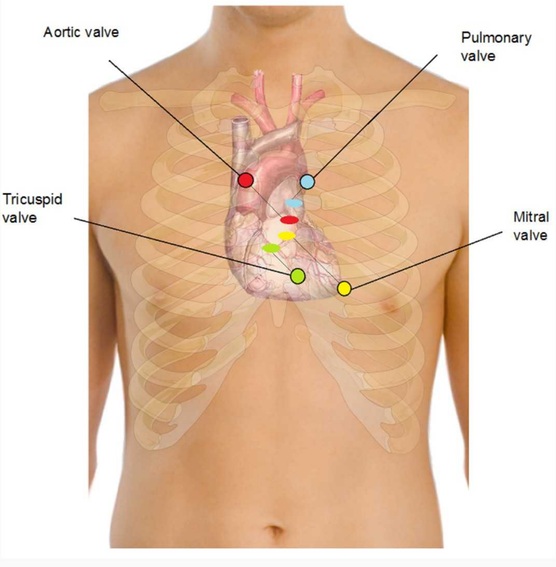


Modified by FRCEM Success. Original by Mikael Häggström [Public domain], via Wikimedia Commons

< Previous | Next > | Something wrong?

## Question Navigator

1 Answered
2 Answered
3 Answered
4 Answered
5 Answered
6 Answered
7 Answered
8 Answered
9 Answered
10 Answered
11 Answered
12 Answered



©2014 - 2017 FRCEM Success | Website designed & hosted by Cyberfrog Design

# Anatomy: Thorax

Question 85 of 134

A 45 year old man presents to ED complaining of severe retrosternal pain that is worse on coughing, and relieved by sitting forwards. The pain radiates to his left shoulder. On examination a pericardial rub is heard, and acute pericarditis is diagnosed. Which of the following nerves is responsible for the radiating pain to the shoulder:

a Intercostal nerve

b Intercostobrachial nerve

c Phrenic nerve

d Cardiopulmonary nerve

e Long thoracic nerve

< Previous | Next > | See Answer

Something wrong?

## Question Navigator

1 Answered
2 Answered
3 Answered
4 Answered
5 Answered
6 Answered
7 Answered
8 Answered
9 Answered
10 Answered
11 Answered
12 Answered



©2014 - 2017 FRCEM Success | Website designed & hosted by Cyberfrog Design

# Anatomy: Thorax

Question 85 of 134

A 45 year old man presents to ED complaining of severe retrosternal pain that is worse on coughing, and relieved by sitting forwards. The pain radiates to his left shoulder. On examination a pericardial rub is heard, and acute pericarditis is diagnosed. Which of the following nerves is responsible for the radiating pain to the shoulder:

**a)** Intercostal nerve
**b)** **Intercostobrachial nerve** ✗
**c)** Phrenic nerve ✓
**d)** Cardiopulmonary nerve
**e)** Long thoracic nerve

## Answer

The fibrous pericardium is innervated by the phrenic nerve (C3 – C5). Irritation of the pericardium in pericarditis will result in pain being referred to the supraclavicular region of the shoulder and the C3 – C5 dermatomes in the neck region.

## Notes

The pericardium is a fibroserous sac surrounding the heart and the roots of the great vessels in the middle mediastinum. It is composed of two main layers; the fibrous pericardium and the serous pericardium.

**Serous pericardium**

The serous pericardium itself is divided into two parts which are continuous at the roots of the great vessels; the parietal layer which lines the inner surface of the fibrous pericardium and the visceral layer which lines the heart itself.

The parietal and visceral layer of serous pericardium are separated by the pericardial cavity which normally contains a small amount of lubricating serous fluid which reduces friction during normal movement of the heart.

**Fibrous pericardium**

The fibrous pericardium is a tough, inelastic sheath which fixes the heart in position (through its attachments to the central tendon of the diaphragm, the sternum and the tunica adventitia of the great vessels) and prevents sudden overfilling and distension of the heart.

Cardiac tamponade is acute compression of the heart caused by rapid accumulation of fluid or blood in the pericardial cavity from trauma (to the heart, great vessels or pericardial vessels) or pericardial effusion. The inflexibility of the fibrous pericardium results in increased intrapericardial pressure, with subsequent compression of venous return and reduced cardiac output.

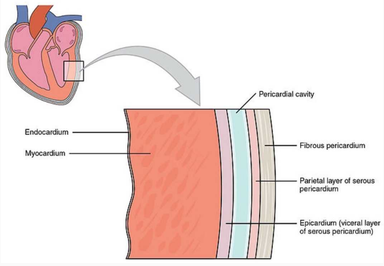


By OpenStax College [CC BY 3.0 (http://creativecommons.org/licenses/by/3.0)], via Wikimedia Commons

**Innervation**

The pericardium receives its nerve supply from the vagus nerve, the sympathetic trunks and the phrenic nerves.

Somatic sensation from the parietal pericardium is carried by somatic afferent fibres in the phrenic nerves (C3 – C5); it is for this reason that pain related to a pericardial problem may be referred to the supraclavicular region of the shoulder or the lateral neck area dermatomes for spinal cord segments C3 – C5.

**Pericardial aspiration (pericardiocentesis)**

Pericardiocentesis is a surgical puncture of the pericardial cavity for the aspiration of fluid, which is necessary to relieve the pressure of accumulated fluid in the heart.

A needle is inserted into the pericardial cavity 1 – 2 cm inferior to the left of the xiphochondral junction (between the xiphisternum and the left costal margin) at a 45 degree angle and advanced aiming toward the tip of the left scapula (site marked by cross in image below).

Complications of pericardiocentesis include:

- Aspiration of ventricular blood instead of pericardial blood
- Laceration of ventricular epicardium or myocardium
- Laceration of coronary artery or vein
- Ventricular fibrillation
- Pneumothorax secondary to lung puncture
- Puncture of great vessels with worsening pericardial tamponade
- Mediastinitis secondary to oesophageal puncture

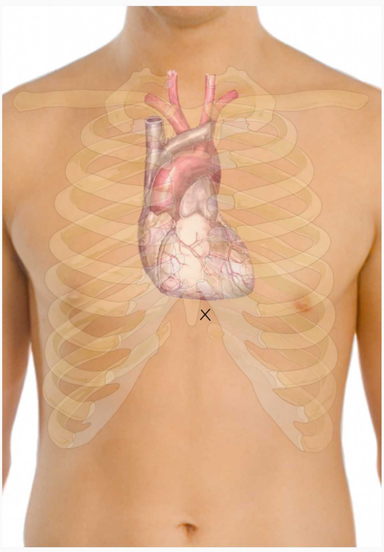

Modified by FRCEM Success. Original by Mikael Häggström (See above. All used images are in public domain.) [Public domain], via Wikimedia Commons

Question Navigator

1 Answered
2 Answered
3 Answered
4 Answered
5 Answered
6 Answered
7 Answered
8 Answered
9 Answered
10 Answered
11 Answered
12 Answered

< Previous | Next >

Something wrong?



©2014 - 2017 FRCEM Success | Website designed & hosted by Cyberfrog Design

# Anatomy: Thorax

Question 86 of 134

A 72 year old man complains of dysphagia. Imaging and barium swallow investigations show significant cardiac hypertrophy with compression of the oesophagus directly posterior to the heart. Which of the following is the most likely cause of the patient's symptoms:

a Mitral stenosis

b Tricuspid stenosis

c Aortic regurgitation

d Pulmonary stenosis

e Tricuspid regurgitation

< Previous | Next > | See Answer

Something wrong?

## Question Navigator

1 Answered
2 Answered
3 Answered
4 Answered
5 Answered
6 Answered
7 Answered
8 Answered
9 Answered
10 Answered
11 Answered
12 Answered



©2014 - 2017 FRCEM Success | Website designed & hosted by Cyberfrog Design

# Anatomy: Thorax

Question 86 of 134

A 72 year old man complains of dysphagia. Imaging and barium swallow investigations show significant cardiac hypertrophy with compression of the oesophagus directly posterior to the heart. Which of the following is the most likely cause of the patient's symptoms:

**a)** **Mitral stenosis** ✔
**b)** Tricuspid stenosis
**c)** Aortic regurgitation
**d)** Pulmonary stenosis
**e)** Tricuspid regurgitation

## Answer

The oesophagus lies directly posterior to the left atrium. Mitral stenosis can cause left atrial enlargement with subsequent compression of the oesophagus.

## Notes

**Anatomical extent**

The oesophagus is a muscular tube passing between the pharynx in the neck and the stomach in the abdomen. The oesophagus begins at the inferior border of the cricoid cartilage opposite vertebra C6, pierces the diaphragm at the esophageal hiatus at T10 and ends at the cardiac opening of the stomach opposite vertebra T11.

**Structure**

The oesophagus consists of an internal circular and external longitudinal layer of muscle. The external longitudinal layer is comprised of different muscle types in each third of the oesophagus; superior third – voluntary striated muscle, middle third – voluntary striated and smooth muscle and inferior third – smooth muscle.

**Relations**

The oesophagus descends on the anterior aspect of the bodies of the vertebrae, immediately posterior to the trachea and the recurrent laryngeal nerves, generally in the midline position. The oesophagus is crossed anteriorly by the aortic arch. As it approaches the diaphragm, the oesophagus moves anteriorly and to the left, crossing from the right side of the thoracic aorta to eventually assume a position anterior to it, before passing through the diaphragm.

Posterior to the oesophagus, the thoracic duct is on the right side inferiorly but crosses to the left more superiorly (at T5). Other structures posteriorly include portions of the hemiazygos veins and the right posterior intercostal vessels.

Anterior to the oesophagus below the tracheal bifurcation are the right pulmonary artery and the left main bronchus. The oesophagus then passes immediately posterior to the left atrium, separated from it only by pericardium. Inferior to the left atrium, the oesophagus is related to the diaphragm.

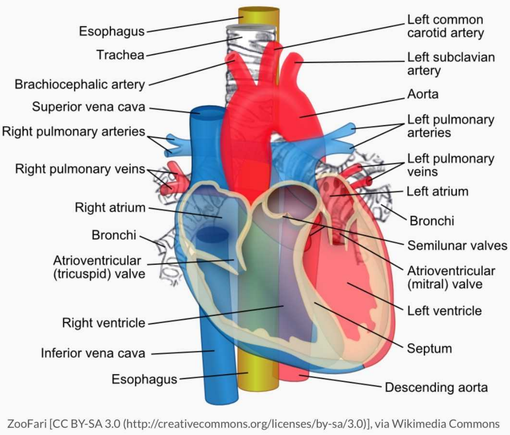


ZooFari [CC BY-SA 3.0 (http://creativecommons.org/licenses/by-sa/3.0)], via Wikimedia Commons

**Points of constriction**

As the oesophagus is a flexible muscular tube, it is compressed by surrounding structures at four locations:

- 1) the junction of the oesophagus with the pharynx in the neck (upper oesophageal sphincter formed by the cricopharyngeus muscle)
- 2) in the superior mediastinum where the oesophagus is crossed by the arch of the aorta
- 3) in the posterior mediastinum where the oesophagus is compressed by the left main bronchus
- 4) in the posterior mediastinum at the oesophageal hiatus in the diaphragm.

Clinically these compressions are important when passing instruments or assessing swallowed objects.

**Innervation**

Oesophageal innervation is complex, oesophageal branches arise from the vagus nerves and sympathetic trunks. The visceral afferents that pass through the sympathetic trunks and the splanchnic nerves are the primary participants in detection of oesophageal pain and transmission of this information to various levels of the central nervous system.

< Previous | Next >

Something wrong?

## Question Navigator

1 Answered
2 Answered
3 Answered
4 Answered
5 Answered
6 Answered
7 Answered
8 Answered
9 Answered
10 Answered
11 Answered
12 Answered



©2014 - 2017 FRCEM Success | Website designed & hosted by Cyberfrog Design

# Anatomy: Thorax

Question 87 of 134

A 45 year old lifelong smoker presents to ED complaining of shortness of breath and chest pain. Imaging shows a tumour invading the lung surface anterior to the hilum. Which of the following structures is most likely affected:

a Intercostal nerve

b Vagus nerve

c Recurrent laryngeal nerve

d Phrenic nerve

e Cardiopulmonary nerve

< Previous | Next > | See Answer

Something wrong?

## Question Navigator

1 Answered
2 Answered
3 Answered
4 Answered
5 Answered
6 Answered
7 Answered
8 Answered
9 Answered
10 Answered
11 Answered
12 Answered



©2014 - 2017 FRCEM Success | Website designed & hosted by Cyberfrog Design

# Anatomy: Thorax

Question 87 of 134

A 45 year old lifelong smoker presents to ED complaining of shortness of breath and chest pain. Imaging shows a tumour invading the lung surface anterior to the hilum. Which of the following structures is most likely affected:

**a)** Intercostal nerve
**b)** Vagus nerve
**c)** Recurrent laryngeal nerve
**d)** **Phrenic nerve** ✔
**e)** Cardiopulmonary nerve

## Answer

The vagus nerves pass immediately posteriorly to the lung roots, while the phrenic nerves pass immediately anterior to them, between the anterior medial aspect of the lung and the mediastinum. The recurrent laryngeal nerves arise from the vagus nerve before the vagus nerves pass behind the hila of the lungs.

## Notes

The lungs lie on either side of the mediastinum, each surrounded by a pleural cavity. They are suspended from the mediastinum by the root of the lung, a short tubular collection of structures.

**Lung root**

The root is lined by a layer of mediastinal pleura that reflects onto the surface of the lungs as visceral pleura. The region outlined by this pleural reflection on the medial surface of the lung is the hilum, where structures enter and leave.

The hila are located at the level of the 3rd – 4th costal cartilage anteriorly, and the T5 – T7 vertebrae posteriorly.

Each lung root contains:

- a pulmonary artery
- two pulmonary veins
- a main bronchus
- bronchial vessels,
- nerves and
- lymphatics.

Generally the pulmonary artery is superior in the lung root, the pulmonary veins are inferior and the bronchi are somewhat posterior in position.

In the mediastinum, the vagus nerves pass immediately posteriorly to the lung roots, while the phrenic nerves pass immediately anterior to them.

On the right side, the lobar bronchus to the superior lobe branches from the main bronchus in the root, whereas on the left, it branches within the lung itself.

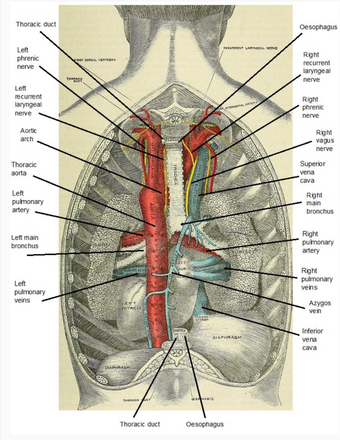


Modified by FRCEM Success. Original by Gray, Henry, 1825-1861; Carter, H. V. (Henry Vandyke), 1831-1897; Pick, T. Pickering (Thomas Pickering), 1841-1919 [No restrictions], via Wikimedia Commons

**Relations**

The medial surface of the right lung lies adjacent to:

- the heart
- the inferior vena cava
- the superior vena cava
- the azygos vein
- the oesophagus

The medial surface of the left lung lies adjacent to:

- the heart
- the aortic arch
- the thoracic aorta
- the oesophagus.

The right and left subclavian arteries and veins arch over and are related to the superior lobe of the right and left lung as they pass over the dome of the cervical pleura and into the axilla.

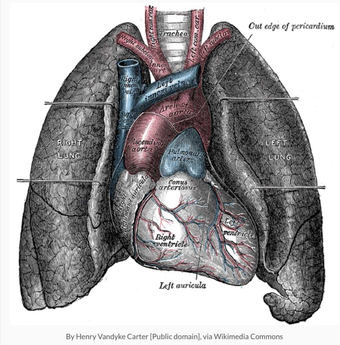


By Henry Vandyke Carter [Public domain], via Wikimedia Commons

**Blood supply**

The right and left pulmonary arteries originate from the pulmonary trunk (at the vertebral level T4/T5) and carry deoxygenated blood to the lungs.

On each side a superior and inferior pulmonary vein carries oxygenated blood from the lungs back to the heart.

The bronchi (down to the terminal bronchioles), lung roots, visceral pleura and supporting lung tissues receive their nutrient blood supply from the bronchial arteries, which arise from the descending aorta.

**Lymphatics**

Lymph from the lungs drains via hilar, tracheobronchial and mediastinal lymph nodes.

**Innervation**

The nerve supply to the lungs is from the anterior and posterior pulmonary plexus (networks of nerves derived from the sympathetic trunk and vagus nerve).

The parasympathetic nerve supply, carried by the vagus nerve, stimulates secretion from the bronchial glands, contraction of bronchial smooth muscle, and vasodilation of the pulmonary vessels. The vagus nerve also carries afferent fibres of pain, cough reflex and stretch of the lung (during inspiration).

The sympathetic nerve supply stimulates relaxation of bronchial smooth muscle, and vasoconstriction of the pulmonary vessels.

Question Navigator

1 Answered
2 Answered
3 Answered
4 Answered
5 Answered
6 Answered
7 Answered
8 Answered
9 Answered
10 Answered
11 Answered
12 Answered

< Previous | Next >

Something wrong?



©2014 - 2017 FRCEM Success | Website designed & hosted by Cyberfrog Design

# Anatomy: Thorax

Question 88 of 134

## The coronary arteries arise from which of the following:

a Aortic arch

b Ascending aorta

c Pulmonary trunk

d Brachiocephalic trunk

e Descending aorta

< Previous | Next > | See Answer

Something wrong?

## Question Navigator

1 Answered
2 Answered
3 Answered
4 Answered
5 Answered
6 Answered
7 Answered
8 Answered
9 Answered
10 Answered
11 Answered
12 Answered



©2014 - 2017 FRCEM Success | Website designed & hosted by Cyberfrog Design

# Anatomy: Thorax

Question 88 of 134

The coronary arteries arise from which of the following:

a) Aortic arch
b) **Ascending aorta** ✔
c) Pulmonary trunk
d) Brachiocephalic trunk
e) Descending aorta

## Answer

The right and left coronary arteries arise from the right and left aortic sinuses in the initial portion of the ascending aorta and supply the muscle and other tissues of the heart.

## Notes

The right and left coronary arteries arise from the right and left aortic sinuses in the initial portion of the ascending aorta and supply the muscle and other tissues of the heart.

| Artery | Territory of supply |
|---|---|
| Right coronary artery | Right atrium and ventricle, sinoatrial node, atrioventricular node |
| Right marginal branch | Inferior aspect of right ventricle |
| Posterior interventricular branch | Posterior aspect of right and left ventricles, posterior one-third of interventricular septum |
| Left coronary artery | Via main branches below |
| Anterior interventricular branch | Right and left ventricles, anterior two-thirds of interventricular septum |
| Left circumflex branch | Left atrium and left ventricle |

**Territories of supply**

Although there is variation, in most people the territories of supply are as follows:

The right coronary artery supplies:

- the right atrium
- most of the right ventricle
- the sinoatrial and atrioventricular nodes
- the interatrial septum
- a portion of the left atrium
- the posteroinferior one-third of the interventricular septum
- a portion of the posterior part of the left ventricle

The left coronary artery supplies:

- most of the left atrium
- most of the left ventricle
- a portion of the right ventricle
- most of the interventricular septum (including the atrioventricular bundle and branches)

**Branches**

The right coronary artery supplies the right atrium, the sinoatrial node and the atrioventricular node (via the SA and AV nodal branches) and gives rise to two principal branches:

- the right marginal branch (supplying the inferior margin of the right ventricle and the apex)
- the posterior interventricular branch (supplying the posterior aspect of the right and left ventricles and the posterior one-third of the interventricular septum).

The left coronary artery gives rise to two principal branches:

- the anterior interventricular branch (supplying the right and left ventricles, the apex and the anterior two-thirds of the interventricular septum)
- the circumflex branch (supplying the left atrium and left ventricle).

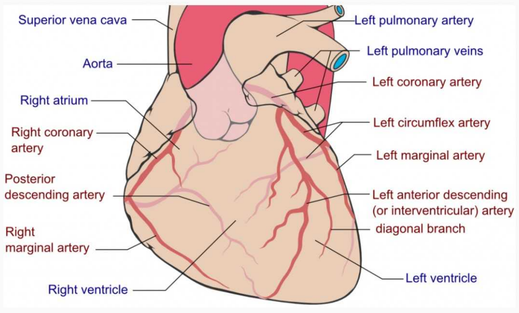


By Coronary.pdf: Patrick J. Lynch, medical illustrator derivative work: Fred the Oyster (talk) adaption and further labeling: Mikael Häggström (Coronary.pdf) [CC BY-SA 3.0 (http://creativecommons.org/licenses/by-sa/3.0)], via Wikimedia Commons

< Previous | Next > | Something wrong?

## Question Navigator

1 Answered
2 Answered
3 Answered
4 Answered
5 Answered
6 Answered
7 Answered
8 Answered
9 Answered
10 Answered
11 Answered
12 Answered



©2014 - 2017 FRCEM Success | Website designed & hosted by Cyberfrog Design

# Anatomy: Thorax

Question 89 of 134

## The pulmonary valve is best auscultated at which of the following sites:

a Over the medial end of the left third intercostal space

b Over the medial end of the right third intercostal space

c Over the medial end of the left second intercostal space

d Over the medial end of the right second intercostal space

e Just right of the lower part of the sternum near the fourth intercostal space

< Previous | Next > | See Answer

Something wrong?

Question Navigator

1 Answered
2 Answered
3 Answered
4 Answered
5 Answered
6 Answered
7 Answered
8 Answered
9 Answered
10 Answered
11 Answered
12 Answered



©2014 - 2017 FRCEM Success | Website designed & hosted by Cyberfrog Design

# Anatomy: Thorax

Question 89 of 134

The pulmonary valve is best auscultated at which of the following sites:

a) Over the medial end of the left third intercostal space
b) Over the medial end of the right third intercostal space
c) **Over the medial end of the left second intercostal space** ✔
d) Over the medial end of the right second intercostal space
e) Just right of the lower part of the sternum near the fourth intercostal space

## Answer

The pulmonary valve is heard over the medial end of the left second intercostal space.

## Notes

| Heart valve | Surface marking | Auscultation position |
|---|---|---|
| Tricuspid valve | Posterior to right half of sternum at level of 4th ICS | Left of sternum near 5th ICS |
| Mitral valve | Posterior to left half of sternum at level of 4th costal cartilage | Left 5th ICS in midclavicular line |
| Pulmonary valve | Posterior to third left chondrosternal joint | Medial end of left 2nd ICS |
| Aortic valve | Posterior to left half of sternum at level of 3rd ICS | Medial end of right 2nd ICS |

**Surface marking of heart valves**

- The tricuspid valve is located posterior to the right half of the sternum at the level of the fourth intercostal space.
- The mitral valve is located posterior to the left half of the sternum at the level of the fourth costal cartilage.
- The pulmonary valve is located posterior to the third left chondrosternal joint.
- The aortic valve is located posterior to the left half of the sternum at the level of the third intercostal space.

**Auscultation positions of heart valves**

Heart valves should be auscultated by positioning the stethoscope downstream from the flow of blood through the valves.

- The tricuspid valve is heard just to the left of the lower part of the sternum near the fifth intercostal space.
- The mitral valve is heard over the apex of the heart in the left fifth intercostal space at the midclavicular line.
- The pulmonary valve is heard over the medial end of the left second intercostal space.
- The aortic valve is heard over the medial end of the right second intercostal space.

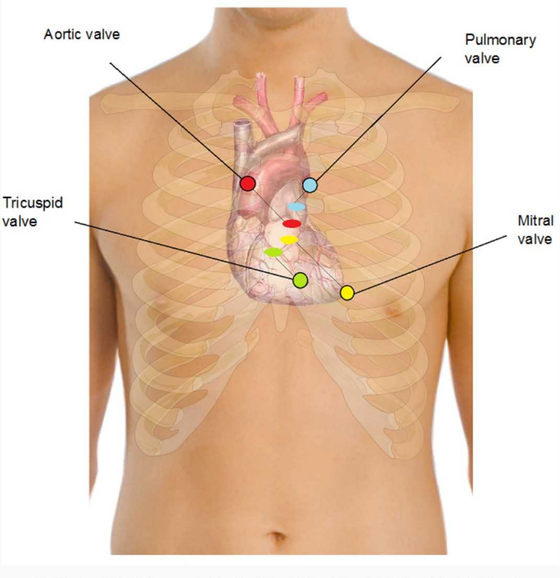


Modified by FRCEM Success. Original by Mikael Häggström [Public domain], via Wikimedia Commons

< Previous | Next >

Something wrong?

## Question Navigator

1 Answered
2 Answered
3 Answered
4 Answered
5 Answered
6 Answered
7 Answered
8 Answered
9 Answered
10 Answered
11 Answered
12 Answered



©2014 - 2017 FRCEM Success | Website designed & hosted by Cyberfrog Design

# Anatomy: Thorax

Question 90 of 134

## Regarding the pleurae, which of the following statements is CORRECT:

a The pleural cavity extends above the first costal cartilage.

b The lungs fill the extent of the pleural cavities.

c The visceral pleura is innervated by intercostal nerves.

d The costal pleura is innervated by the phrenic nerve.

e The pleural cavity extends above the neck of the first rib.

< Previous | Next > | See Answer

Something wrong?

## Question Navigator

1 Answered
2 Answered
3 Answered
4 Answered
5 Answered
6 Answered
7 Answered
8 Answered
9 Answered
10 Answered
11 Answered
12 Answered



©2014 - 2017 FRCEM Success | Website designed & hosted by Cyberfrog Design

# Anatomy: Thorax

Question 90 of 134

Regarding the pleurae, which of the following statements is CORRECT:

a) The pleural cavity extends above the first costal cartilage. ✔
b) The lungs fill the extent of the pleural cavities.
c) The visceral pleura is innervated by intercostal nerves.
d) **The costal pleura is innervated by the phrenic nerve.** ✖
e) The pleural cavity extends above the neck of the first rib.

## Answer

Superiorly, the pleural cavity projects as much as 3 – 4 cm above the first costal cartilage but does not extend above the neck of rib 1. The two pleurae approach each other medially but are separated by the middle mediastinum. The costal pleura (the part of the parietal pleura related to the ribs and intercostal spaces) is innervated by the intercostal nerves. The lungs do not completely fill the pleural cavities, producing two pleural recesses, the costomediastinal and costodiaphragmatic recesses, in which fluids can collect.

## Notes

Each lung is surrounded by a pleura. The pleura consists of two parts, the parietal pleura (which lines the thoracic cavity) and the visceral pleura (which lines the lungs). The two parts of the pleura are continuous with each other at the hilum of each lung. The potential space between these two parts of the pleura is called the pleural cavity.

**Pleural cavity**

The pleural cavity normally contains a small amount of lubricating fluid to allow the visceral pleura attached to the lungs to smoothly slide over the parietal pleura attached to the thoracic wall during respiration. The serous fluid also produces a surface tension, pulling the parietal and visceral pleura together. This ensures that when the thorax expands, the lung also expands, filling with air.

**Innervation**

The parietal pleura is innervated by somatic afferent fibres. The costal pleura (pleura related to the ribs and intercostal spaces) is innervated by branches of the intercostal nerves, and pain is felt in relation to the thoracic wall. The diaphragmatic pleura (covering the diaphragm) and the mediastinal pleura (covering the mediastinum) are innervated mainly by the phrenic nerves (C3 – C5), and pain is referred the the C3 – C5 dermatomes (lateral neck and supraclavicular region of shoulder).

Although the visceral pleura is innervated by visceral afferent fibres, pain is not generally elicited from this tissue.

**Surface markings**

Superiorly the pleural cavity projects as much as 3 – 4 cm above the first costal cartilage but does not extend above the neck of rib 1.

Anteriorly the pleurae approach each other posterior to the upper part of the sternum. At the lower part of the sternum the left pleura does not come as close to the midline as the right pleura because the middle mediastinum bulges to the left.

Inferiorly the pleura reflects onto the diaphragm above the costal margin. The inferior margin of the pleural cavity is a line that runs between rib 8 in the midclavicular line, rib 10 in the midaxillary line and vertebra T12 posteriorly.

The inferior margin of the lung in quiet respiration is a line that runs between rib 6 in the midclavicular line, rib 8 in the midaxillary line and vertebra T10 posteriorly.

The lungs therefore do not completely fill the pleural cavities, producing two pleural recesses, the costomediastinal and costodiaphragmatic recesses, in which fluids can collect.

The costomediastinal recess occurs on each side where the the costal pleura is opposed to mediastinal pleura, particularly on the left side in the region overlying the heart.

The costodiaphragmatic recess occurs between the costal and diaphragmatic pleura. It is the region between the inferior margin of the lung and the inferior margin of the pleural cavity and is clinically important for pleural aspiration.

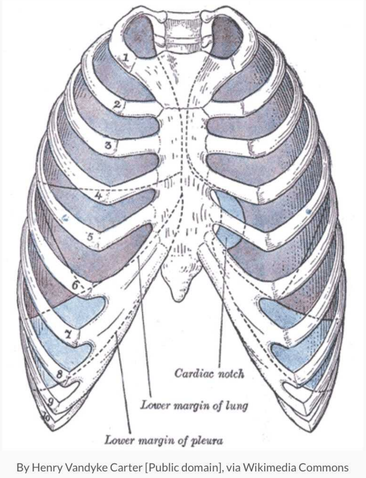


By Henry Vandyke Carter [Public domain], via Wikimedia Commons

< Previous | Next >

Something wrong?

## Question Navigator

1 Answered
2 Answered
3 Answered
4 Answered
5 Answered
6 Answered
7 Answered
8 Answered
9 Answered
10 Answered
11 Answered
12 Answered



©2014 - 2017 FRCEM Success | Website designed & hosted by Cyberfrog Design

# Anatomy: Thorax

Question 91 of 134

A 65 year old, lifelong smoker, presents to ED complaining of sudden onset chest pain and shortness of breath. X-ray demonstrates left sided pneumothorax and your consultant has agreed to observe you insert a chest drain. Which of the following sites is the most appropriate to place the chest drain:

a Second intercostal space midclavicular line

b Third intercostal space midaxillary line

c Fourth intercostal space midclavicular line

d Fifth intercostal space midaxillary line

e Sixth intercostal space midaxillary line

< Previous | Next > | See Answer

Something wrong?

## Question Navigator

1 Answered
2 Answered
3 Answered
4 Answered
5 Answered
6 Answered
7 Answered
8 Answered
9 Answered
10 Answered
11 Answered
12 Answered



©2014 - 2017 FRCEM Success | Website designed & hosted by Cyberfrog Design

# Anatomy: Thorax

Question 91 of 134

A 65 year old, lifelong smoker, presents to ED complaining of sudden onset chest pain and shortness of breath. X-ray demonstrates left sided pneumothorax and your consultant has agreed to observe you insert a chest drain. Which of the following sites is the most appropriate to place the chest drain:

**a)** Second intercostal space midclavicular line
**b)** Third intercostal space midaxillary line
**c)** Fourth intercostal space midclavicular line
**d)** **Fifth intercostal space midaxillary line** ✔
**e)** Sixth intercostal space midaxillary line

## Answer

The chest drain should be placed in the fifth intercostal space in the midaxillary line.

## Notes

The intercostal space lies between adjacent ribs and mostly contains intercostal muscles. Since there are 12 ribs on each side, there are 11 intercostal spaces, each numbered for the rib superior to it.

Intercostal nerves and major associated arteries and veins lie in the costal groove along the inferior margin of the rib, lying in a plane between the internal and innermost intercostal muscles.

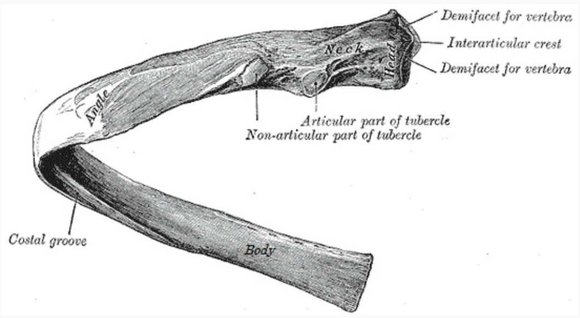


Modified by FRCEM Success. Original by Henry Vandyke Carter [Public domain], via Wikimedia Commons

In each space, the vein is the most superior structure and is therefore highest in the costal groove. The artery is inferior to the vein and the nerve inferior to the artery and often not protected by the groove. Therefore the nerve is the most vulnerable structure in a penetrating injury to the upper aspect of the intercostal space. Small collateral branches of the major intercostal nerves and vessels are often present superior to the inferior rib below.

Any needle or tube (e.g. in needle thoracocentesis, pleural aspiration or chest drain insertion) being inserted in the intercostal space should be placed immediately above the superior margin of a rib to avoid injury to the intercostal neurovascular bundle.

### Needle thoracocentesis

Needle thoracocentesis is indicated in patients in critical condition with rapid deterioration who have a life-threatening tension pneumothorax where urgent chest drain insertion is not possible.

The needle should be placed just superior to the third rib, in the second intercostal space, in the midclavicular line on the affected side.

Complications of needle thoracocentesis include local haematoma, pneumothorax and lung laceration.

### Chest drain insertion

Chest drain insertion is the definitive treatment for tension pneumothorax. Chest drain insertion normally occurs at the fifth intercostal space in the midaxillary line on the affected side.

Complications of chest drain insertion include:

- laceration or puncture of intrathoracic or intraabdominal organs
- introduction of pleural infection
- damage to the intercostal nerve (resulting in intercostal neuralgia)
- damage to the intercostal artery or vein (resulting in haemopneumothorax)
- chest drain kinking, clogging or dislodgement or disconnection from underwater seal
- persistent pneumothorax
- subcutaneous emphysema
- recurrence of pneumothorax upon removal of chest drain.

< Previous | Next >

Something wrong?

## Question Navigator

1 Answered
2 Answered
3 Answered
4 Answered
5 Answered
6 Answered
7 Answered
8 Answered
9 Answered
10 Answered
11 Answered
12 Answered



©2014 - 2017 FRCEM Success | Website designed & hosted by Cyberfrog Design

# Anatomy: Thorax

Question 92 of 134

## The aortic valve is best auscultated at which of the following sites:

a Over the medial end of the left third intercostal space

b Over the medial end of the right third intercostal space

c Over the medial end of the left second intercostal space

d Over the medial end of the right second intercostal space

e Just right of the lower part of the sternum near the fourth intercostal space

< Previous | Next > | See Answer

Something wrong?

Question Navigator

1 Answered
2 Answered
3 Answered
4 Answered
5 Answered
6 Answered
7 Answered
8 Answered
9 Answered
10 Answered
11 Answered
12 Answered



©2014 - 2017 FRCEM Success | Website designed & hosted by Cyberfrog Design

# Anatomy: Thorax

Question 92 of 134

The aortic valve is best auscultated at which of the following sites:

a) Over the medial end of the left third intercostal space
b) Over the medial end of the right third intercostal space
c) Over the medial end of the left second intercostal space
d) **Over the medial end of the right second intercostal space** ✔
e) Just right of the lower part of the sternum near the fourth intercostal space

## Answer

The aortic valve is heard over the medial end of the right second intercostal space.

## Notes

| Heart valve | Surface marking | Auscultation position |
|---|---|---|
| Tricuspid valve | Posterior to right half of sternum at level of 4th ICS | Left of sternum near 5th ICS |
| Mitral valve | Posterior to left half of sternum at level of 4th costal cartilage | Left 5th ICS in midclavicular line |
| Pulmonary valve | Posterior to third left chondrosternal joint | Medial end of left 2nd ICS |
| Aortic valve | Posterior to left half of sternum at level of 3rd ICS | Medial end of right 2nd ICS |

**Surface marking of heart valves**

- The tricuspid valve is located posterior to the right half of the sternum at the level of the fourth intercostal space.
- The mitral valve is located posterior to the left half of the sternum at the level of the fourth costal cartilage.
- The pulmonary valve is located posterior to the third left chondrosternal joint.
- The aortic valve is located posterior to the left half of the sternum at the level of the third intercostal space.

**Auscultation positions of heart valves**

Heart valves should be auscultated by positioning the stethoscope downstream from the flow of blood through the valves.

- The tricuspid valve is heard just to the left of the lower part of the sternum near the fifth intercostal space.
- The mitral valve is heard over the apex of the heart in the left fifth intercostal space at the midclavicular line.
- The pulmonary valve is heard over the medial end of the left second intercostal space.
- The aortic valve is heard over the medial end of the right second intercostal space.

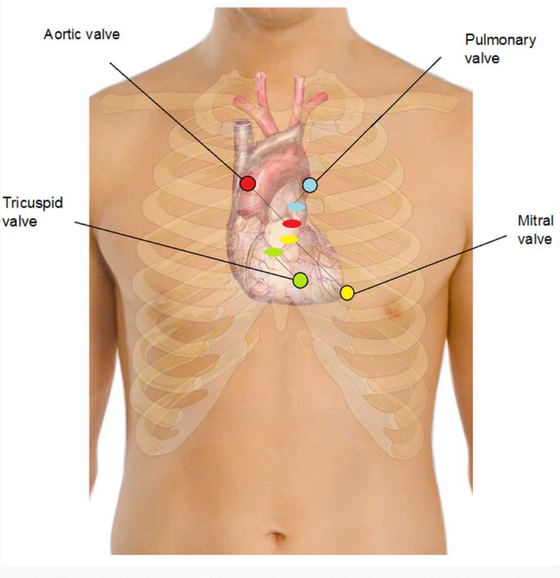


Modified by FRCEM Success. Original by Mikael Häggström [Public domain], via Wikimedia Commons

< Previous | Next >

Something wrong?

## Question Navigator

1 Answered
2 Answered
3 Answered
4 Answered
5 Answered
6 Answered
7 Answered
8 Answered
9 Answered
10 Answered
11 Answered
12 Answered



©2014 - 2017 FRCEM Success | Website designed & hosted by Cyberfrog Design

# Anatomy: Thorax

Question 93 of 134

## Which of the following best describes the surface marking of the pulmonary valve:

a Posterior to the right half of the sternum at the level of the fourth intercostal space

b Posterior to the left half of the sternum at the level of the fourth costal cartilage

c Posterior to the third left chondrosternal joint

d Posterior to the left half of the sternum at the level of the third intercostal space

e Posterior to the right half of the sternum at the level of the third costal cartilage

< Previous | Next > | See Answer

Something wrong?

## Question Navigator

1 Answered
2 Answered
3 Answered
4 Answered
5 Answered
6 Answered
7 Answered
8 Answered
9 Answered
10 Answered
11 Answered
12 Answered



©2014 - 2017 FRCEM Success | Website designed & hosted by Cyberfrog Design

# Anatomy: Thorax

Question 94 of 134

## At rest, the left dome of the diaphragm normally reaches as high as which of the following:

a Third intercostal space

b Fourth intercostal space

c Fifth intercostal space

d Sixth intercostal space

e Seventh intercostal space

< Previous | Next > | See Answer

Something wrong?

## Question Navigator

1 Answered
2 Answered
3 Answered
4 Answered
5 Answered
6 Answered
7 Answered
8 Answered
9 Answered
10 Answered
11 Answered
12 Answered



©2014 - 2017 FRCEM Success | Website designed & hosted by Cyberfrog Design

# Anatomy: Thorax

Question 94 of 134

At rest, the left dome of the diaphragm normally reaches as high as which of the following:

**a)** Third intercostal space
**b)** Fourth intercostal space
**c)** Fifth intercostal space ✔
**d)** **Sixth intercostal space** ✖
**e)** Seventh intercostal space

## Answer

At rest the right dome of the diaphragm lies slightly higher than the left; this is thought to be due to the position of the liver. In normal expiration, the normal upper limits of the superior margins are the fifth rib for the right dome, the fifth intercostal space for the left dome and the xiphoid process for the central tendon.

## Notes

The diaphragm is a musculotendinous structure that separates the thoracic cavity from the abdominal cavity.

| Structure | Diaphragm |
|---|---|
| Primary function | Respiration – contraction of diaphragm flattens diaphragm increasing vertical dimension of thorax (inspiration), relaxation of diaphragm elevates diaphragm decreasing vertical dimension of thorax (expiration) |
| Secondary functions | Assists in straining movements by increasing intra-abdominal pressure, acts as functional sphincter on oesophagus preventing acid reflux |
| Peripheral attachments | Xiphoid process of sternum, costal cartilages ribs 7 – 10, ends of ribs 11 and 12, arcuate ligaments and lumbar vertebrae |
| Central attachment | Fuses with fibrous pericardium superiorly |
| Surface markings | Attachments: vertebrae T8/T9 anteriorly, vertebra T12 posteriorly, Domes: right dome 5th rib, left dome 5th intercostal space |
| Openings | Oesophageal opening at T10 (oesophagus, vagus nerve), aortic opening at T12 (aorta, thoracic duct and azygos vein), caval opening at T8 (inferior vena cava and right phrenic nerve) |
| Innervation | Phrenic nerve (C3 – C5) |

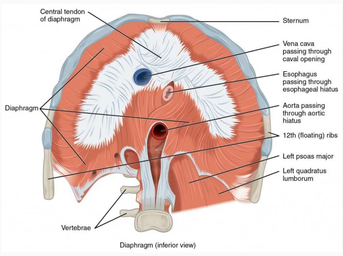


By OpenStax [CC BY 4.0 (http://creativecommons.org/licenses/by/4.0)], via Wikimedia Commons

**Function**

The diaphragm performs an important function in respiration; contraction of the domes of the diaphragm in inspiration flattens the diaphragm, increasing the vertical dimension of the thorax and vice versa in expiration, with relaxation and elevation of the diaphragm reducing the vertical dimension of the thorax.

The diaphragm is also involved in non-respiratory functions; helping to expel vomit, faeces, and urine from the body by increasing intraabdominal pressure, and preventing acid reflux by exerting pressure on the oesophagus as it passes through the oesophageal opening.

**Attachments**

The diaphragm is attached peripherally to:

- the xiphoid process of the sternum and the costal cartilages of ribs 7 – 10 (the costal margin) anteriorly
- the ends of ribs 11 and 12 laterally
- the arcuate ligaments and vertebrae posteriorly.

From these peripheral attachments, muscle fibres converge to form the central tendon which fuses with the fibrous pericardium superiorly.

**Surface markings**

In the medial sagittal plane, the diaphragm slopes inferiorly from its anterior attachment to the xiphoid at approximately vertebral level T8/T9 to its posterior attachment to the median arcuate ligament at approximately vertebral level T12.

At rest the right dome of the diaphragm lies slightly higher than the left; this is thought to be due to the position of the liver. In normal expiration, the normal upper limits of the superior margins are the fifth rib for the right dome, the fifth intercostal space for the left dome and the xiphoid process for the central tendon.

**Diaphragmatic openings**

Structures travelling between the thorax and abdomen must pass through the diaphragm via three main openings.

The oesophageal opening at vertebral level T10 transmits:

- the oesophagus
- the anterior and posterior vagal trunks
- oesophageal branches of the left gastric vessels
- a few lymphatics.

The aortic opening at vertebral level T12 transmits:

- the aorta
- the thoracic duct
- the azygos vein and sometimes the hemiazygos vein.

The caval opening at vertebral level T8 transmits:

- the inferior vena cava
- the right phrenic nerve.

**Innervation**

The entire motor supply of the diaphragm is from the right and left phrenic nerves (C3 – C5) which penetrate the diaphragm and innervate it from its abdominal surface.

Damage to the phrenic nerve will result in hemiparalysis of the diaphragm. Paralysis of the diaphragm produces a paradoxical movement. The affected side of the diaphragm moves upwards during inspiration (as it is pushed superiorly by the abdominal viscera that are being actively compressed by the other half), and downwards during expiration.

A unilateral diaphragmatic paralysis is usually asymptomatic, and is most often an incidental finding on x-ray. If both sides are paralysed, the patient may experience poor exercise tolerance, orthopnoea and fatigue. Lung function tests will show a restrictive deficit.

**Diaphragmatic herniation**

Diaphragmatic hernias are defined as congenital or acquired defects in the diaphragm. There are two main types of congenital diaphragmatic hernias; Bochdalek hernias and Morgagni hernias.

Acquired diaphragmatic hernias include traumatic diaphragmatic rupture, hiatus hernia and iatrogenic diaphragmatic hernias. Depending on the location and size of the defect, retroperitoneal or intra-abdominal organs and tissues can prolapse into the thoracic cavity due to the negative intrathoracic pressure.

Diaphragmatic rupture usually results from blunt abdominal trauma, which is typically associated with motor-vehicle accidents; the most commonly herniated viscera are the stomach and colon on the left side, and the liver on the right side.

In hiatus hernia, the stomach herniates through the oesophageal opening of the diaphragm, typically resulting in symptoms of acid reflux.

< Previous | Next >

Something wrong?

## Question Navigator

1 Answered
2 Answered
3 Answered
4 Answered
5 Answered
6 Answered
7 Answered
8 Answered
9 Answered
10 Answered
11 Answered
12 Answered



©2014 - 2017 FRCEM Success | Website designed & hosted by Cyberfrog Design

# Anatomy: Thorax

Question 95 of 134

A 49 year old patient presents to ED with vomiting and abdominal distension. X-ray shows small bowel obstruction. A nasogastric tube is inserted. Which of the following is least likely to be a site at which resistance would be expected as the tube passes from the nose to the stomach:

a At the junction of the oesophagus with the pharynx

b In the superior mediastinum where the oesophagus is crossed by the arch of the aorta

c In the posterior mediastinum where the oesophagus is crossed by the pulmonary trunk

d In the posterior mediastinum where the oesophagus is crossed by the left main bronchus

e At the oesophageal hiatus in the diaphragm

< Previous | Next > | See Answer

Something wrong?

## Question Navigator

1 Answered
2 Answered
3 Answered
4 Answered
5 Answered
6 Answered
7 Answered
8 Answered
9 Answered
10 Answered
11 Answered
12 Answered



©2014 - 2017 FRCEM Success | Website designed & hosted by Cyberfrog Design

# Anatomy: Thorax

Question 95 of 134

A 49 year old patient presents to ED with vomiting and abdominal distension. X-ray shows small bowel obstruction. A nasogastric tube is inserted. Which of the following is least likely to be a site at which resistance would be expected as the tube passes from the nose to the stomach:

**a)** At the junction of the oesophagus with the pharynx
**b)** In the superior mediastinum where the oesophagus is crossed by the arch of the aorta
**c)**
**In the posterior mediastinum where the oesophagus is crossed by the pulmonary trunk**
**d)** In the posterior mediastinum where the oesophagus is crossed by the left main bronchus
**e)** At the oesophageal hiatus in the diaphragm

## Answer

As the oesophagus is a flexible muscular tube, it is compressed by surrounding structures at four locations:

- 1) the junction of the oesophagus with the pharynx in the neck (upper oesophageal sphincter formed by the cricopharyngeus muscle)
- 2) in the superior mediastinum where the oesophagus is crossed by the arch of the aorta
- 3) in the posterior mediastinum where the oesophagus is compressed by the left main bronchus
- 4) in the posterior mediastinum at the oesophageal hiatus in the diaphragm.

## Notes

### Anatomical extent

The oesophagus is a muscular tube passing between the pharynx in the neck and the stomach in the abdomen. The oesophagus begins at the inferior border of the cricoid cartilage opposite vertebra C6, pierces the diaphragm at the esophageal hiatus at T10 and ends at the cardiac opening of the stomach opposite vertebra T11.

### Structure

The oesophagus consists of an internal circular and external longitudinal layer of muscle. The external longitudinal layer is comprised of different muscle types in each third of the oesophagus; superior third – voluntary striated muscle, middle third – voluntary striated and smooth muscle and inferior third – smooth muscle.

### Relations

The oesophagus descends on the anterior aspect of the bodies of the vertebrae, immediately posterior to the trachea and the recurrent laryngeal nerves, generally in the midline position. The oesophagus is crossed anteriorly by the aortic arch. As it approaches the diaphragm, the oesophagus moves anteriorly and to the left, crossing from the right side of the thoracic aorta to eventually assume a position anterior to it, before passing through the diaphragm.

Posterior to the oesophagus, the thoracic duct is on the right side inferiorly but crosses to the left more superiorly (at T5). Other structures posteriorly include portions of the hemiazygos veins and the right posterior intercostal vessels.

Anterior to the oesophagus below the tracheal bifurcation are the right pulmonary artery and the left main bronchus. The oesophagus then passes immediately posterior to the left atrium, separated from it only by pericardium. Inferior to the left atrium, the oesophagus is related to the diaphragm.

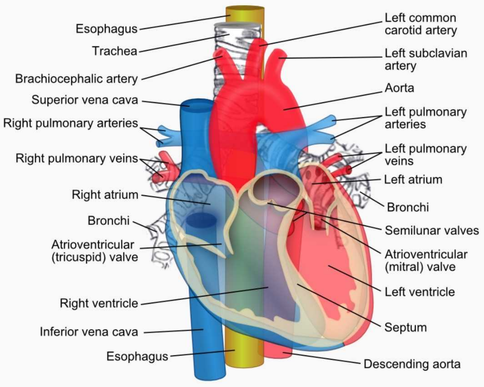


ZooFari [CC BY-SA 3.0 (http://creativecommons.org/licenses/by-sa/3.0)], via Wikimedia Commons

### Points of constriction

As the oesophagus is a flexible muscular tube, it is compressed by surrounding structures at four locations:

- 1) the junction of the oesophagus with the pharynx in the neck (upper oesophageal sphincter formed by the cricopharyngeus muscle)
- 2) in the superior mediastinum where the oesophagus is crossed by the arch of the aorta
- 3) in the posterior mediastinum where the oesophagus is compressed by the left main bronchus
- 4) in the posterior mediastinum at the oesophageal hiatus in the diaphragm.

Clinically these compressions are important when passing instruments or assessing swallowed objects.

### Innervation

Oesophageal innervation is complex, oesophageal branches arise from the vagus nerves and sympathetic trunks. The visceral afferents that pass through the sympathetic trunks and the splanchnic nerves are the primary participants in detection of oesophageal pain and transmission of this information to various levels of the central nervous system.

< Previous | Next >

Something wrong?

Question Navigator

1 Answered
2 Answered
3 Answered
4 Answered
5 Answered
6 Answered
7 Answered
8 Answered
9 Answered
10 Answered
11 Answered
12 Answered



©2014 - 2017 FRCEM Success | Website designed & hosted by Cyberfrog Design

# Anatomy: Thorax

Question 96 of 134

## The following structures all lies anterior to the oesophagus except for the:

a Trachea

b Left recurrent laryngeal nerve

c Left main bronchus

d Pericardium

e Thoracic duct

< Previous | Next > | See Answer

Something wrong?

Question Navigator

1 Answered
2 Answered
3 Answered
4 Answered
5 Answered
6 Answered
7 Answered
8 Answered
9 Answered
10 Answered
11 Answered
12 Answered



©2014 - 2017 FRCEM Success | Website designed & hosted by Cyberfrog Design

# Anatomy: Thorax

Question 96 of 134

The following structures all lies anterior to the oesophagus except for the:

a) Trachea
b) Left recurrent laryngeal nerve
c) Left main bronchus
d) Pericardium
e) **Thoracic duct** ✔

## Answer

Posterior to the oesophagus, the thoracic duct is on the right side inferiorly but crosses to the left more superiorly (at T5).

## Notes

**Anatomical extent**

The oesophagus is a muscular tube passing between the pharynx in the neck and the stomach in the abdomen. The oesophagus begins at the inferior border of the cricoid cartilage opposite vertebra C6, pierces the diaphragm at the esophageal hiatus at T10 and ends at the cardiac opening of the stomach opposite vertebra T11.

**Structure**

The oesophagus consists of an internal circular and external longitudinal layer of muscle. The external longitudinal layer is comprised of different muscle types in each third of the oesophagus; superior third – voluntary striated muscle, middle third – voluntary striated and smooth muscle and inferior third – smooth muscle.

**Relations**

The oesophagus descends on the anterior aspect of the bodies of the vertebrae, immediately posterior to the trachea and the recurrent laryngeal nerves, generally in the midline position. The oesophagus is crossed anteriorly by the aortic arch. As it approaches the diaphragm, the oesophagus moves anteriorly and to the left, crossing from the right side of the thoracic aorta to eventually assume a position anterior to it, before passing through the diaphragm.

Posterior to the oesophagus, the thoracic duct is on the right side inferiorly but crosses to the left more superiorly (at T5). Other structures posteriorly include portions of the hemiazygos veins and the right posterior intercostal vessels.

Anterior to the oesophagus below the tracheal bifurcation are the right pulmonary artery and the left main bronchus. The oesophagus then passes immediately posterior to the left atrium, separated from it only by pericardium. Inferior to the left atrium, the oesophagus is related to the diaphragm.

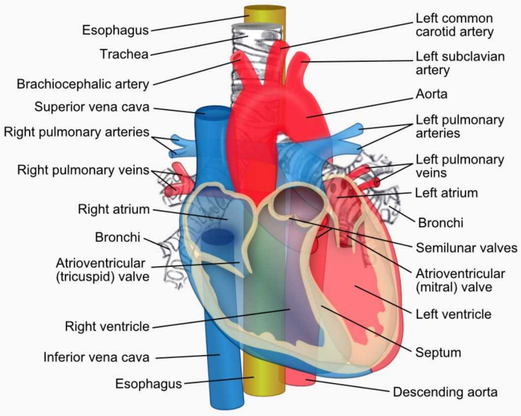


ZooFari [CC BY-SA 3.0 (http://creativecommons.org/licenses/by-sa/3.0)], via Wikimedia Commons

**Points of constriction**

As the oesophagus is a flexible muscular tube, it is compressed by surrounding structures at four locations:

- 1) the junction of the oesophagus with the pharynx in the neck (upper oesophageal sphincter formed by the cricopharyngeus muscle)
- 2) in the superior mediastinum where the oesophagus is crossed by the arch of the aorta
- 3) in the posterior mediastinum where the oesophagus is compressed by the left main bronchus
- 4) in the posterior mediastinum at the oesophageal hiatus in the diaphragm.

Clinically these compressions are important when passing instruments or assessing swallowed objects.

**Innervation**

Oesophageal innervation is complex, oesophageal branches arise from the vagus nerves and sympathetic trunks. The visceral afferents that pass through the sympathetic trunks and the splanchnic nerves are the primary participants in detection of oesophageal pain and transmission of this information to various levels of the central nervous system.

< Previous | Next >

Something wrong?

## Question Navigator

1 Answered
2 Answered
3 Answered
4 Answered
5 Answered
6 Answered
7 Answered
8 Answered
9 Answered
10 Answered
11 Answered
12 Answered



©2014 - 2017 FRCEM Success | Website designed & hosted by Cyberfrog Design

# Anatomy: Thorax

Question 97 of 134

## The horizontal fissure of the lung separates which of the following:

a Right superior and inferior lobes

b Right superior and middle lobes

c Left superior and inferior lobes

d Left superior and middle lobes

e Right middle and inferior lobes

< Previous | Next > | See Answer

Something wrong?

## Question Navigator

1 Answered
2 Answered
3 Answered
4 Answered
5 Answered
6 Answered
7 Answered
8 Answered
9 Answered
10 Answered
11 Answered
12 Answered



©2014 - 2017 FRCEM Success | Website designed & hosted by Cyberfrog Design

# Anatomy: Thorax

Question 97 of 134

The horizontal fissure of the lung separates which of the following:

a) Right superior and inferior lobes
b) **Right superior and middle lobes** ✔
c) Left superior and inferior lobes
d) Left superior and middle lobes
e) Right middle and inferior lobes

## Answer

The horizontal fissure separates the right superior lobe from the right middle lobe.

## Notes

The lungs lie on either side of the mediastinum, each surrounded by a pleural cavity. The right lung is normally a little larger than the left lung because the middle mediastinum, containing the heart, bulges more to the left than to the right.

**Lobes and fissures**

The right lung has three lobes and two fissures; the oblique fissure separates the inferior lobe from the superior and middle lobe whilst the horizontal fissure separates the superior lobe from the middle lobe.

The left lung has two lobes separated by the oblique fissure.

The oblique fissure may be an evolutionary development to permit greater transmission of diaphragmatic excursions to the superior lobe. In this way the upper lobe can expand to a relatively greater extent for a given increase in the superoinferior diameter of the pleural cavity.

**Surface marking**

The inferior margin of the lung in quiet respiration is a line that runs between rib 6 in the midclavicular line, rib 8 in the midaxillary line and vertebra T10 posteriorly.

In quiet respiration, the approximate position of the right oblique fissure can be marked by a line on the thoracic wall that begins at the spinous process of vertebra T4, crosses the fifth intercostal space laterally and then follows the contour of rib 6 anteriorly. The horizontal fissure follows the fourth intercostal space from the sternum until it meets the oblique fissure as it crosses rib 5.

The oblique fissure in the left lung is slightly more oblique than the corresponding fissure in the right lung. In quiet respiration, the approximate position of the oblique fissure can be marked by a line on the thoracic wall that begins between the spinous processes of vertebrae T3 and T4, crosses the fifth intercostal space laterally and then follows the contour of rib 6 anteriorly.

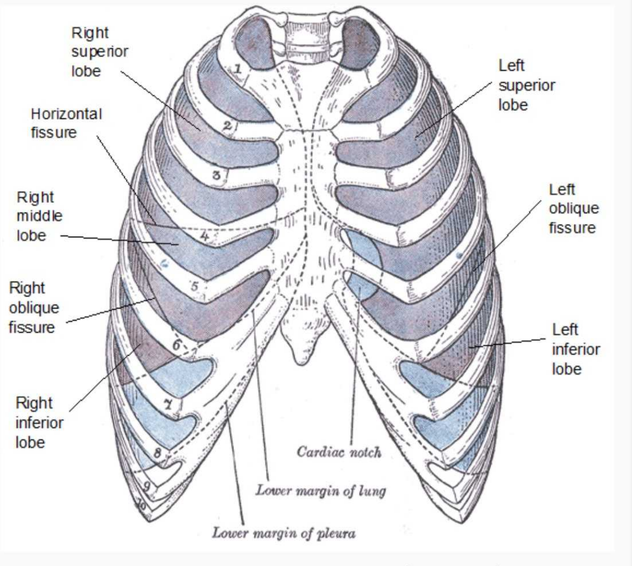


Modified by FRCEM Success. Original by Henry Vandyke Carter [Public domain], via Wikimedia Commons

< Previous | Next > | Something wrong?

## Question Navigator

1 Answered
2 Answered
3 Answered
4 Answered
5 Answered
6 Answered
7 Answered
8 Answered
9 Answered
10 Answered
11 Answered
12 Answered



©2014 - 2017 FRCEM Success | Website designed & hosted by Cyberfrog Design

# Anatomy: Thorax

Question 98 of 134

## In most people, the sinoatrial node is supplied by which of the following coronary vessels:

a Right coronary artery

b Left circumflex branch

c Posterior interventricular branch

d Anterior interventricular branch

e Left coronary artery

< Previous | Next > | See Answer

Something wrong?

Question Navigator

1 Answered
2 Answered
3 Answered
4 Answered
5 Answered
6 Answered
7 Answered
8 Answered
9 Answered
10 Answered
11 Answered
12 Answered



©2014 - 2017 FRCEM Success | Website designed & hosted by Cyberfrog Design

# Anatomy: Thorax

Question 98 of 134

In most people, the sinoatrial node is supplied by which of the following coronary vessels:

**a)** **Right coronary artery** ✔
**b)** Left circumflex branch
**c)** Posterior interventricular branch
**d)** Anterior interventricular branch
**e)** Left coronary artery

## Answer

The sinoatrial node is usually supplied by the SA nodal branch of the right coronary artery.

## Notes

The right and left coronary arteries arise from the right and left aortic sinuses in the initial portion of the ascending aorta and supply the muscle and other tissues of the heart.

| Artery | Territory of supply |
|---|---|
| Right coronary artery | Right atrium and ventricle, sinoatrial node, atrioventricular node |
| Right marginal branch | Inferior aspect of right ventricle |
| Posterior interventricular branch | Posterior aspect of right and left ventricles, posterior one-third of interventricular septum |
| Left coronary artery | Via main branches below |
| Anterior interventricular branch | Right and left ventricles, anterior two-thirds of interventricular septum |
| Left circumflex branch | Left atrium and left ventricle |

**Territories of supply**

Although there is variation, in most people the territories of supply are as follows:

The right coronary artery supplies:

- the right atrium
- most of the right ventricle
- the sinoatrial and atrioventricular nodes
- the interatrial septum
- a portion of the left atrium
- the posteroinferior one-third of the interventricular septum
- a portion of the posterior part of the left ventricle

The left coronary artery supplies:

- most of the left atrium
- most of the left ventricle
- a portion of the right ventricle
- most of the interventricular septum (including the atrioventricular bundle and branches)

**Branches**

The right coronary artery supplies the right atrium, the sinoatrial node and the atrioventricular node (via the SA and AV nodal branches) and gives rise to two principal branches:

- the right marginal branch (supplying the inferior margin of the right ventricle and the apex)
- the posterior interventricular branch (supplying the posterior aspect of the right and left ventricles and the posterior one-third of the interventricular septum).

The left coronary artery gives rise to two principal branches:

- the anterior interventricular branch (supplying the right and left ventricles, the apex and the anterior two-thirds of the interventricular septum)
- the circumflex branch (supplying the left atrium and left ventricle).

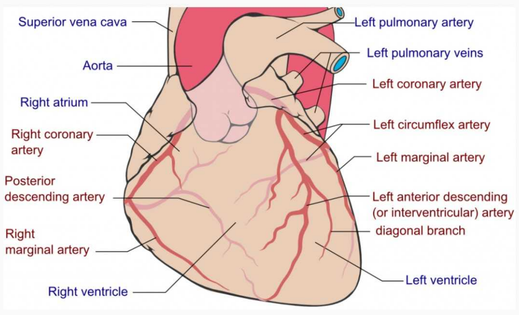


By Coronary.pdf: Patrick J. Lynch, medical illustrator derivative work: Fred the Oyster (talk) adaption and further labeling: Mikael Häggström (Coronary.pdf) [CC BY-SA 3.0 (http://creativecommons.org/licenses/by-sa/3.0)], via Wikimedia Commons

< Previous | Next > | Something wrong?

## Question Navigator

1 Answered
2 Answered
3 Answered
4 Answered
5 Answered
6 Answered
7 Answered
8 Answered
9 Answered
10 Answered
11 Answered
12 Answered



©2014 - 2017 FRCEM Success | Website designed & hosted by Cyberfrog Design

# Anatomy: Thorax

Question 99 of 134

## The lower limit of the heart on the left side of the sternum is the:

a Third intercostal space

b Fourth intercostal space

c Fifth intercostal space

d Sixth intercostal space

e Seventh intercostal space

< Previous | Next > | See Answer

Something wrong?

## Question Navigator

1 Answered
2 Answered
3 Answered
4 Answered
5 Answered
6 Answered
7 Answered
8 Answered
9 Answered
10 Answered
11 Answered
12 Answered



©2014 - 2017 FRCEM Success | Website designed & hosted by Cyberfrog Design

# Anatomy: Thorax

Question 99 of 134

The lower limit of the heart on the left side of the sternum is the:

a) Third intercostal space
b) Fourth intercostal space
c) **Fifth intercostal space** ✔
d) Sixth intercostal space
e) Seventh intercostal space

## Answer

The lower limit of the heart extends from the sternal end of the right sixth costal cartilage to the apex in the fifth intercostal space near the midclavicular line.

## Notes

Surface markings

| Heart | Surface marking |
|---|---|
| Right upper limit | Third costal cartilage |
| Left upper limit | Second intercostal space |
| Right lower limit | Sixth costal cartilage |
| Left lower limit | Fifth intercostal space |

The upper limit of the heart reaches as high as the third costal cartilage on the right side of the sternum and the second intercostal space on the left side of the sternum.

The lower limit of the heart extends from the sternal end of the right sixth costal cartilage to the apex in the fifth intercostal space near the midclavicular line.

The right margin of the heart therefore extends from the right third costal cartilage to near the right sixth costal cartilage and the left margin of the heart extends from the left second intercostal space to the apex located near the midclavicular line in the fifth intercostal space.

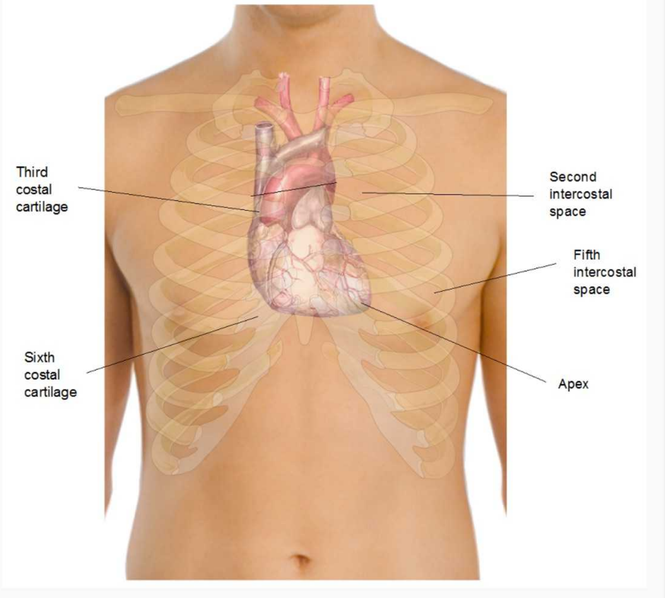


Modified by FRCEM Success. Original by Mikael Häggström[Public domain], via Wikimedia Commons

< Previous | Next >

Something wrong?

## Question Navigator

1 Answered
2 Answered
3 Answered
4 Answered
5 Answered
6 Answered
7 Answered
8 Answered
9 Answered
10 Answered
11 Answered
12 Answered



©2014 - 2017 FRCEM Success | Website designed & hosted by Cyberfrog Design

# Anatomy: Thorax

Question 100 of 134

## The right atrium is primarily supplied by which of the following coronary vessels:

- a Right coronary artery
- b Right marginal branch
- Posterior interventricular branch
- d Anterior interventricular branch
- e Left circumflex branch

< Previous | Next > | See Answer

Something wrong?

## Question Navigator

1 Answered
2 Answered
3 Answered
4 Answered
5 Answered
6 Answered
7 Answered
8 Answered
9 Answered
10 Answered
11 Answered
12 Answered



©2014 - 2017 FRCEM Success | Website designed & hosted by Cyberfrog Design

# Anatomy: Thorax

Question 100 of 134

The right atrium is primarily supplied by which of the following coronary vessels:

**a)** **Right coronary artery** ✔
**b)** Right marginal branch
**c)** Posterior interventricular branch
**d)** Anterior interventricular branch
**e)** Left circumflex branch

## Answer

The right atrium receives its blood supply primarily from the right coronary artery.

## Notes

The right and left coronary arteries arise from the right and left aortic sinuses in the initial portion of the ascending aorta and supply the muscle and other tissues of the heart.

| Artery | Territory of supply |
|---|---|
| Right coronary artery | Right atrium and ventricle, sinoatrial node, atrioventricular node |
| Right marginal branch | Inferior aspect of right ventricle |
| Posterior interventricular branch | Posterior aspect of right and left ventricles, posterior one-third of interventricular septum |
| Left coronary artery | Via main branches below |
| Anterior interventricular branch | Right and left ventricles, anterior two-thirds of interventricular septum |
| Left circumflex branch | Left atrium and left ventricle |

**Territories of supply**

Although there is variation, in most people the territories of supply are as follows:

The right coronary artery supplies:

- the right atrium
- most of the right ventricle
- the sinoatrial and atrioventricular nodes
- the interatrial septum
- a portion of the left atrium
- the posteroinferior one-third of the interventricular septum
- a portion of the posterior part of the left ventricle

The left coronary artery supplies:

- most of the left atrium
- most of the left ventricle
- a portion of the right ventricle
- most of the interventricular septum (including the atrioventricular bundle and branches)

**Branches**

The right coronary artery supplies the right atrium, the sinoatrial node and the atrioventricular node (via the SA and AV nodal branches) and gives rise to two principal branches:

- the right marginal branch (supplying the inferior margin of the right ventricle and the apex)
- the posterior interventricular branch (supplying the posterior aspect of the right and left ventricles and the posterior one-third of the interventricular septum).

The left coronary artery gives rise to two principal branches:

- the anterior interventricular branch (supplying the right and left ventricles, the apex and the anterior two-thirds of the interventricular septum)
- the circumflex branch (supplying the left atrium and left ventricle).

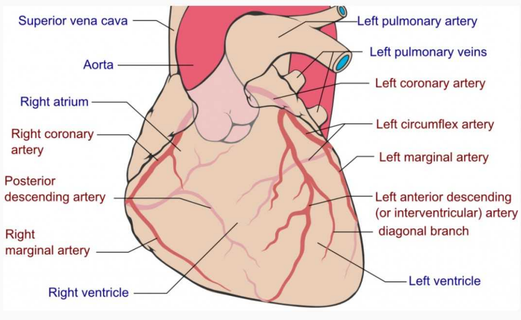


By Coronary.pdf: Patrick J. Lynch, medical illustrator derivative work: Fred the Oyster (talk) adaption and further labeling: Mikael Häggström (Coronary.pdf) [CC BY-SA 3.0 (http://creativecommons.org/licenses/by-sa/3.0)], via Wikimedia Commons

< Previous | Next >

Something wrong?

## Question Navigator

1 Answered
2 Answered
3 Answered
4 Answered
5 Answered
6 Answered
7 Answered
8 Answered
9 Answered
10 Answered
11 Answered
12 Answered



©2014 - 2017 FRCEM Success | Website designed & hosted by Cyberfrog Design

# Anatomy: Thorax

Question 101 of 134

A patient is brought to ED having been involved in a road traffic accident. Imaging shows a fracture of the T3 vertebral body with compression of the T3 spinal nerve root. The T3 dermatome is best tested at which of the following landmarks:

a At the apex of the axilla

b In the third intercostal space

c At the level of the nipples

d In the fourth intercostal space

e At the level of the sternal angle

< Previous | Next > | See Answer

Something wrong?

## Question Navigator

1 Answered
2 Answered
3 Answered
4 Answered
5 Answered
6 Answered
7 Answered
8 Answered
9 Answered
10 Answered
11 Answered
12 Answered



©2014 - 2017 FRCEM Success | Website designed & hosted by Cyberfrog Design

# Anatomy: Thorax

Question 101 of 134

A patient is brought to ED having been involved in a road traffic accident. Imaging shows a fracture of the T3 vertebral body with compression of the T3 spinal nerve root. The T3 dermatome is best tested at which of the following landmarks:

**a)** At the apex of the axilla
**b)** **In the third intercostal space** ✔
**c)** At the level of the nipples
**d)** In the fourth intercostal space
**e)** At the level of the sternal angle

## Answer

The T3 dermatome is best tested at the midclavicular line and the third intercostal space.

## Notes

| Dermatome | Landmark |
|---|---|
| T1 | Medial antecubital fossa |
| T2 | Apex of axilla |
| T3 | Third intercostal space |
| T4 | Level of nipples (fourth intercostal space) |
| T5 | Fifth intercostal space |
| T6 | Level of xiphisternum |
| T7 | One-quarter distance between xiphisternum and umbilicus |
| T8 | One-half distance between xiphisternum and umbilicus |
| T9 | Three-quarter distance between xiphisternum and umbilicus |
| T10 | Level of umbilicus |
| T11 | Midway between umbilicus and inguinal ligament |
| T12 | Midpoint of inguinal ligament |

**Dermatome assessment**

- The T1 dermatome is best tested on the medial (ulnar) side of the antecubital fossa, just proximal to the medial epicondyle of the humerus.
- The T2 dermatome is best tested at the apex of the axilla.
- The T3 dermatome is best tested at the midclavicular line and the third intercostal space.
- The T4 dermatome is best tested at the midclavicular line and the fourth intercostal space, located at the level of the nipples.
- The T5 dermatome is best tested at the midclavicular line and the fifth intercostal space, located midway between the level of the nipples and the level of the xiphisternum.
- The T6 dermatome is best tested at the midclavicular line, located at the level of the xiphisternum.
- The T7 dermatome is best tested at the midclavicular line, one quarter the distance between the level of the xiphisternum and the level of the umbilicus.
- The T8 dermatome is best tested at the midclavicular line, one half the distance between the level of the xiphisternum and the level of the umbilicus.
- The T9 dermatome is best tested at the midclavicular line, three quarters of the distance between the level of the xiphisternum and the level of the umbilicus.
- The T10 dermatome is best tested at the midclavicular line, located at the level of the umbilicus.
- The T11 dermatome is best tested at the midclavicular line, midway between the level of the umbilicus and the inguinal ligament.
- The T12 dermatome is best tested at the midclavicular line, over the midpoint of the inguinal ligament.

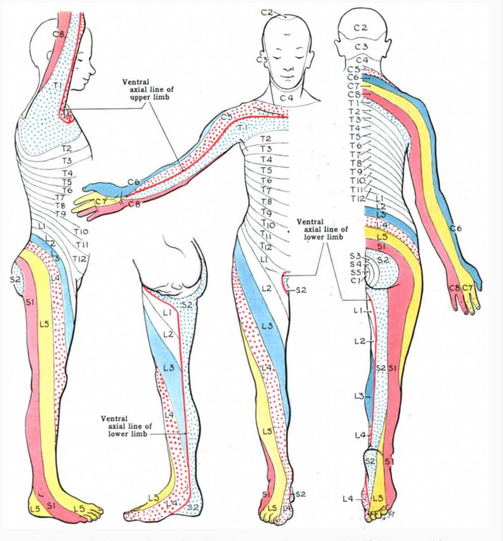


By Grant, John Charles Boileau (An atlas of anatomy, / by regions 1962) [Public domain], via Wikimedia Commons

< Previous | Next >

Something wrong?

## Question Navigator

1 Answered
2 Answered
3 Answered
4 Answered
5 Answered
6 Answered
7 Answered
8 Answered
9 Answered
10 Answered
11 Answered
12 Answered



©2014 - 2017 FRCEM Success | Website designed & hosted by Cyberfrog Design

# Anatomy: Thorax

Question 102 of 134

## The T5 dermatome is best tested at which of the following landmarks:

a At the level of the sternal angle

b At the level of the nipples

c In the fourth intercostal space

d At the level of the xiphisternum

e In the fifth intercostal space

< Previous | Next > | See Answer

Something wrong?

## Question Navigator

1 Answered
2 Answered
3 Answered
4 Answered
5 Answered
6 Answered
7 Answered
8 Answered
9 Answered
10 Answered
11 Answered
12 Answered



©2014 - 2017 FRCEM Success | Website designed & hosted by Cyberfrog Design

# Anatomy: Thorax

Question 102 of 134

The T5 dermatome is best tested at which of the following landmarks:

a) At the level of the sternal angle
b) At the level of the nipples
c) In the fourth intercostal space
d) At the level of the xiphisternum
e) **In the fifth intercostal space** ✔

## Answer

The T5 dermatome is best tested at the midclavicular line and the fifth intercostal space, located midway between the level of the nipples and the level of the xiphisternum.

## Notes

| Dermatome | Landmark |
|---|---|
| T1 | Medial antecubital fossa |
| T2 | Apex of axilla |
| T3 | Third intercostal space |
| T4 | Level of nipples (fourth intercostal space) |
| T5 | Fifth intercostal space |
| T6 | Level of xiphisternum |
| T7 | One-quarter distance between xiphisternum and umbilicus |
| T8 | One-half distance between xiphisternum and umbilicus |
| T9 | Three-quarter distance between xiphisternum and umbilicus |
| T10 | Level of umbilicus |
| T11 | Midway between umbilicus and inguinal ligament |
| T12 | Midpoint of inguinal ligament |

**Dermatome assessment**

- The T1 dermatome is best tested on the medial (ulnar) side of the antecubital fossa, just proximal to the medial epicondyle of the humerus.
- The T2 dermatome is best tested at the apex of the axilla.
- The T3 dermatome is best tested at the midclavicular line and the third intercostal space.
- The T4 dermatome is best tested at the midclavicular line and the fourth intercostal space, located at the level of the nipples.
- The T5 dermatome is best tested at the midclavicular line and the fifth intercostal space, located midway between the level of the nipples and the level of the xiphisternum.
- The T6 dermatome is best tested at the midclavicular line, located at the level of the xiphisternum.
- The T7 dermatome is best tested at the midclavicular line, one quarter the distance between the level of the xiphisternum and the level of the umbilicus.
- The T8 dermatome is best tested at the midclavicular line, one half the distance between the level of the xiphisternum and the level of the umbilicus.
- The T9 dermatome is best tested at the midclavicular line, three quarters of the distance between the level of the xiphisternum and the level of the umbilicus.
- The T10 dermatome is best tested at the midclavicular line, located at the level of the umbilicus.
- The T11 dermatome is best tested at the midclavicular line, midway between the level of the umbilicus and the inguinal ligament.
- The T12 dermatome is best tested at the midclavicular line, over the midpoint of the inguinal ligament.

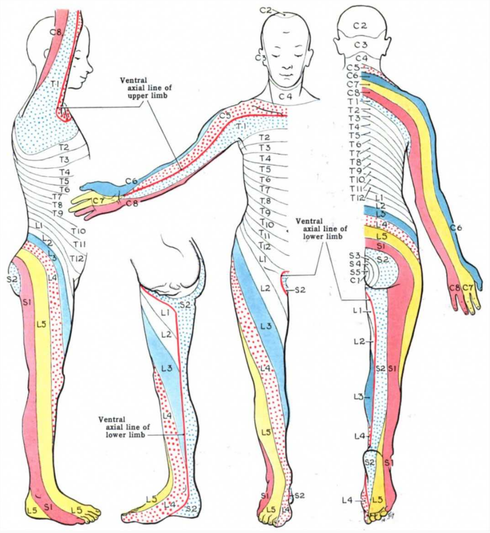


By Grant, John Charles Boileau (An atlas of anatomy. / by regions 1962) [Public domain], via Wikimedia Commons

< Previous | Next >

Something wrong?

## Question Navigator

1 Answered
2 Answered
3 Answered
4 Answered
5 Answered
6 Answered
7 Answered
8 Answered
9 Answered
10 Answered
11 Answered
12 Answered



©2014 - 2017 FRCEM Success | Website designed & hosted by Cyberfrog Design

# Anatomy: Thorax

Question 103 of 134

## The peripheral diaphragm is attached anterolaterally to which of the following structures:

a Xiphoid process of the sternum, the costal margin and to ribs 11 – 12

b Manubrium of the sternum and costal cartilages of ribs 7 – 12

c Ribs 5 – 10 and the arcuate ligament

d Ribs 5 – 10

e Pericardium

< Previous | Next > | See Answer

Something wrong?

## Question Navigator

1 Answered
2 Answered
3 Answered
4 Answered
5 Answered
6 Answered
7 Answered
8 Answered
9 Answered
10 Answered
11 Answered
12 Answered



©2014 - 2017 FRCEM Success | Website designed & hosted by Cyberfrog Design

# Anatomy: Thorax

Question 103 of 134

The peripheral diaphragm is attached anterolaterally to which of the following structures:

**a)** Xiphoid process of the sternum, the costal margin and to ribs 11 – 12 ✔
**b)** Manubrium of the sternum and costal cartilages of ribs 7 – 12
**c)** **Ribs 5 – 10 and the arcuate ligament** ✖
**d)** Ribs 5 – 10
**e)** Pericardium

## Answer

The diaphragm is attached peripherally to the xiphoid process of the sternum and the costal cartilages of ribs 7 – 10 (the costal margin) anteriorly, the ends of ribs 11 and 12 laterally, the arcuate ligaments and vertebrae posteriorly.

## Notes

The diaphragm is a musculotendinous structure that separates the thoracic cavity from the abdominal cavity.

| Structure | Diaphragm |
|---|---|
| Primary function | Respiration – contraction of diaphragm flattens diaphragm increasing vertical dimension of thorax (inspiration), relaxation of diaphragm elevates diaphragm decreasing vertical dimension of thorax (expiration) |
| Secondary functions | Assists in straining movements by increasing intra-abdominal pressure, acts as functional sphincter on oesophagus preventing acid reflux |
| Peripheral attachments | Xiphoid process of sternum, costal cartilages ribs 7 – 10, ends of ribs 11 and 12, arcuate ligaments and lumbar vertebrae |
| Central attachment | Fuses with fibrous pericardium superiorly |
| Surface markings | Attachments: vertebrae T8/T9 anteriorly, vertebra T12 posteriorly, Domes: right dome 5th rib, left dome 5th intercostal space |
| Openings | Oesophageal opening at T10 (oesophagus, vagus nerve), aortic opening at T12 (aorta, thoracic duct and azygos vein), caval opening at T8 (inferior vena cava and right phrenic nerve) |
| Innervation | Phrenic nerve (C3 – C5) |

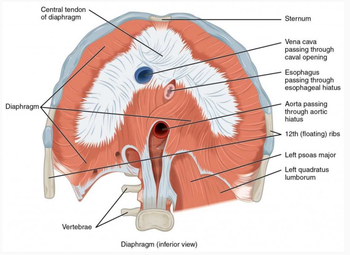


By OpenStax [CC BY 4.0 (http://creativecommons.org/licenses/by/4.0)], via Wikimedia Commons

### Function

The diaphragm performs an important function in respiration; contraction of the domes of the diaphragm in inspiration flattens the diaphragm, increasing the vertical dimension of the thorax and vice versa in expiration, with relaxation and elevation of the diaphragm reducing the vertical dimension of the thorax.

The diaphragm is also involved in non-respiratory functions; helping to expel vomit, faeces, and urine from the body by increasing intraabdominal pressure, and preventing acid reflux by exerting pressure on the oesophagus as it passes through the oesophageal opening.

### Attachments

The diaphragm is attached peripherally to:

- the xiphoid process of the sternum and the costal cartilages of ribs 7 – 10 (the costal margin) anteriorly
- the ends of ribs 11 and 12 laterally
- the arcuate ligaments and vertebrae posteriorly.

From these peripheral attachments, muscle fibres converge to form the central tendon which fuses with the fibrous pericardium superiorly.

### Surface markings

In the medial sagittal plane, the diaphragm slopes inferiorly from its anterior attachment to the xiphoid at approximately vertebral level T8/T9 to its posterior attachment to the median arcuate ligament at approximately vertebral level T12.

At rest the right dome of the diaphragm lies slightly higher than the left; this is thought to be due to the position of the liver. In normal expiration, the normal upper limits of the superior margins are the fifth rib for the right dome, the fifth intercostal space for the left dome and the xiphoid process for the central tendon.

### Diaphragmatic openings

Structures travelling between the thorax and abdomen must pass through the diaphragm via three main openings.

The oesophageal opening at vertebral level T10 transmits:

- the oesophagus
- the anterior and posterior vagal trunks
- oesophageal branches of the left gastric vessels
- a few lymphatics.

The aortic opening at vertebral level T12 transmits:

- the aorta
- the thoracic duct
- the azygos vein and sometimes the hemiazygos vein.

The caval opening at vertebral level T8 transmits:

- the inferior vena cava
- the right phrenic nerve.

### Innervation

The entire motor supply of the diaphragm is from the right and left phrenic nerves (C3 – C5) which penetrate the diaphragm and innervate it from its abdominal surface.

Damage to the phrenic nerve will result in hemiparalysis of the diaphragm. Paralysis of the diaphragm produces a paradoxical movement. The affected side of the diaphragm moves upwards during inspiration (as it is pushed superiorly by the abdominal viscera that are being actively compressed by the other half), and downwards during expiration.

A unilateral diaphragmatic paralysis is usually asymptomatic, and is most often an incidental finding on x-ray. If both sides are paralysed, the patient may experience poor exercise tolerance, orthopnoea and fatigue. Lung function tests will show a restrictive deficit.

### Diaphragmatic herniation

Diaphragmatic hernias are defined as congenital or acquired defects in the diaphragm. There are two main types of congenital diaphragmatic hernias; Bochdalek hernias and Morgagni hernias.

Acquired diaphragmatic hernias include traumatic diaphragmatic rupture, hiatus hernia and iatrogenic diaphragmatic hernias. Depending on the location and size of the defect, retroperitoneal or intra-abdominal organs and tissues can prolapse into the thoracic cavity due to the negative intrathoracic pressure.

Diaphragmatic rupture usually results from blunt abdominal trauma, which is typically associated with motor-vehicle accidents; the most commonly herniated viscera are the stomach and colon on the left side, and the liver on the right side.

In hiatus hernia, the stomach herniates through the oesophageal opening of the diaphragm, typically resulting in symptoms of acid reflux.

< Previous | Next >

Something wrong?

## Question Navigator

1 Answered
2 Answered
3 Answered
4 Answered
5 Answered
6 Answered
7 Answered
8 Answered
9 Answered
10 Answered
11 Answered
12 Answered



©2014 - 2017 FRCEM Success | Website designed & hosted by Cyberfrog Design

# Anatomy: Thorax

Question 104 of 134

## Which of the following ribs are classed as 'true ribs':

a Ribs 1 – 4

b Ribs 1 – 7

c Ribs 2 – 10

d Ribs 1 – 10

e Ribs 1 – 8

< Previous | Next > | See Answer

Something wrong?

## Question Navigator

1 Answered
2 Answered
3 Answered
4 Answered
5 Answered
6 Answered
7 Answered
8 Answered
9 Answered
10 Answered
11 Answered
12 Answered



©2014 - 2017 FRCEM Success | Website designed & hosted by Cyberfrog Design

# Anatomy: Thorax

Question 104 of 134

Which of the following ribs are classed as 'true ribs':

**a)** Ribs 1 – 4
**b)** **Ribs 1 – 7** ✔
**c)** Ribs 2 – 10
**d)** Ribs 1 – 10
**e)** Ribs 1 – 8

## Answer

Ribs 1 – 7 are classed as true ribs because they attach directly to the sternum.

## Notes

There are twelve pairs of ribs, each terminating anteriorly in a costal cartilage.

**True and False ribs**

The ribs are divided into 'true' and 'false' ribs based on their anterior attachments:

- The true ribs (1 – 7) attach directly to the sternum anteriorly.
- The false ribs (8 – 12) can be further divided into those that attach to the costal cartilage of the rib above them (8 – 10) and the floating ribs (11 + 12) that do not have any anterior attachments.

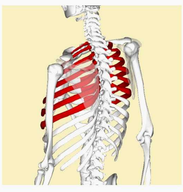

By Anatomography (en:Anatomography (setting page of this image)) [CC BY-SA 2.1 jp (http://creativecommons.org/licenses/by-sa/2.1/jp/deed.en)], via Wikimedia Commons

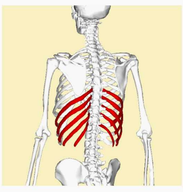

By Anatomography (en:Anatomography (setting page of this image)) [CC BY-SA 2.1 jp (http://creativecommons.org/licenses/by-sa/2.1/jp/deed.en)], via Wikimedia Commons

**Thoracic vertebrae**

Posteriorly, all of the ribs articulate with the thoracic vertebrae of the spine.

Each typical rib forms two joints posteriorly:

- the costotransverse joint (between the tubercle of the rib and the transverse process of the corresponding vertebra)
- the costovertebral joint (between the two facets on the head of the rib and the superior costal facet on the body of the corresponding vertebra, and the inferior costal facet on the body of the vertebra above).

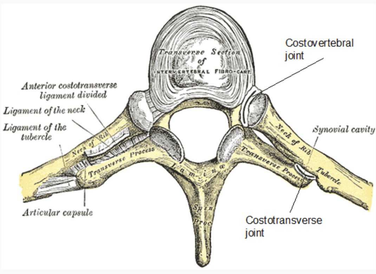


Modified by FRCEM Success. Original by Henry Vandyke Carter [Public domain], via Wikimedia Commons

**Typical ribs**

The typical rib consists of a head, a neck and a body:

- The head of the rib has two articular facets which articulate with the superior costal facet on the body of the corresponding vertebra, and the inferior costal facet on the body of the vertebra above.
- The neck of the rib connects the head to the body. Where the neck meets the body, there is a tubercle which articulates with the transverse process of the corresponding vertebra.
- The body of the rib is flat and curved.

The inferior margin of the internal surface of the body is marked by the costal groove which protects the neurovascular structures which run within it.

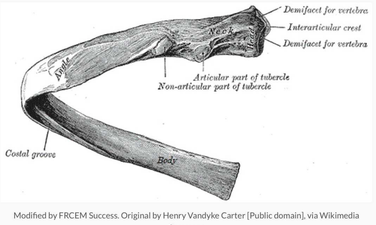


Modified by FRCEM Success. Original by Henry Vandyke Carter [Public domain], via Wikimedia Commons

**Atypical ribs**

The atypical ribs consist of ribs 1, 2, 10, 11 and 12.

| Atypical rib | Features |
|---|---|
| Rib 1 | Shorter and wider, single facet for articulation with T1, scalene tubercle |
| Rib 2 | Flat, roughened area for attachment of serratus anterior muscle |
| Rib 10 | Single facet for articulation with T10 |
| Rib 11 | No neck, single facet for articulation with T11 |
| Rib 12 | No neck, single facet for articulation with T12 |

- Rib 1 is shorter and wider than the other ribs. The head of rib 1 has only one facet for articulation with the body of its own vertebra (T1); it does NOT articulate with vertebra C7. The superior surface of rib 1 is characterised by the scalene tubercle about midway along the body, which separates two smooth grooves in the rib made by the subclavian vein anteriorly and the subclavian artery posteriorly.
- Like rib 1, rib 2 is flat but twice as long. It has a roughened area on its upper surface where the serratus anterior muscle attaches.
- The head of rib 10 only has a single facet for articulation with the body of its own vertebra (T10).
- Ribs 11 and 12 have no neck, and have only one facet for articulation with the bodies of their own vertebrae (T11 and T12).

< Previous | Next >

Something wrong?

## Question Navigator

1 Answered
2 Answered
3 Answered
4 Answered
5 Answered
6 Answered
7 Answered
8 Answered
9 Answered
10 Answered
11 Answered
12 Answered



©2014 - 2017 FRCEM Success | Website designed & hosted by Cyberfrog Design

# Anatomy: Thorax

Question 105 of 134

## Regarding the atypical ribs, which of the following statements is INCORRECT:

a Rib 1 is shorter and wider than the other ribs.

b The superior surface of rib 2 is characterised by the scalene tubercle.

c The head of rib 10 has only a single facet for articulation with the body of its own vertebra.

d Ribs 11 and 12 have no neck.

e Rib 1 has two grooves on its superior surface made by the subclavian vessels.

< Previous | Next > | See Answer

Something wrong?

Question Navigator

1 Answered
2 Answered
3 Answered
4 Answered
5 Answered
6 Answered
7 Answered
8 Answered
9 Answered
10 Answered
11 Answered
12 Answered



©2014 - 2017 FRCEM Success | Website designed & hosted by Cyberfrog Design

# Anatomy: Thorax

Question 105 of 134

Regarding the atypical ribs, which of the following statements is INCORRECT:

a) Rib 1 is shorter and wider than the other ribs.
b) **The superior surface of rib 2 is characterised by the scalene tubercle.** ✔
c) The head of rib 10 has only a single facet for articulation with the body of its own vertebra.
d) Ribs 11 and 12 have no neck.
e) Rib 1 has two grooves on its superior surface made by the subclavian vessels.

## Answer

The superior surface of rib 1 is characterised by the scalene tubercle about midway along the body, which separates two smooth grooves in the rib made by the subclavian vein anteriorly and the subclavian artery posteriorly. Rib 2has a roughened area on its upper surface where the serratus anterior muscle attaches.

## Notes

There are twelve pairs of ribs, each terminating anteriorly in a costal cartilage.

**True and False ribs**

The ribs are divided into 'true' and 'false' ribs based on their anterior attachments:

- The true ribs (1 – 7) attach directly to the sternum anteriorly.
- The false ribs (8 – 12) can be further divided into those that attach to the costal cartilage of the rib above them (8 – 10) and the floating ribs (11 + 12) that do not have any anterior attachments.

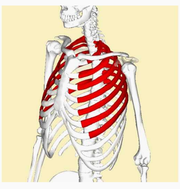

By Anatomography (en:Anatomography (setting page of this image)) [CC BY-SA 2.1 jp (http://creativecommons.org/licenses/by-sa/2.1/jp/deed.en)], via Wikimedia Commons

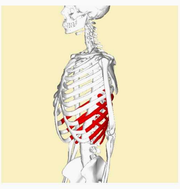

By Anatomography (en:Anatomography (setting page of this image)) [CC BY-SA 2.1 jp (http://creativecommons.org/licenses/by-sa/2.1/jp/deed.en)], via Wikimedia Commons

**Thoracic vertebrae**

Posteriorly, all of the ribs articulate with the thoracic vertebrae of the spine.

Each typical rib forms two joints posteriorly:

- the costotransverse joint (between the tubercle of the rib and the transverse process of the corresponding vertebra)
- the costovertebral joint (between the two facets on the head of the rib and the superior costal facet on the body of the corresponding vertebra, and the inferior costal facet on the body of the vertebra above).

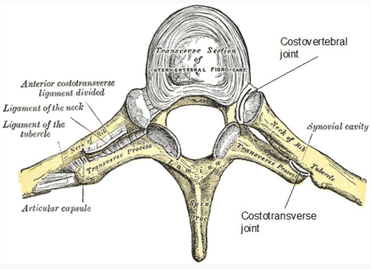


Modified by FRCEM Success. Original by Henry Vandyke Carter [Public domain], via Wikimedia Commons

**Typical ribs**

The typical rib consists of a head, a neck and a body:

- The head of the rib has two articular facets which articulate with the superior costal facet on the body of the corresponding vertebra, and the inferior costal facet on the body of the vertebra above.
- The neck of the rib connects the head to the body. Where the neck meets the body, there is a tubercle which articulates with the transverse process of the corresponding vertebra.
- The body of the rib is flat and curved.

The inferior margin of the internal surface of the body is marked by the costal groove which protects the neurovascular structures which run within it.

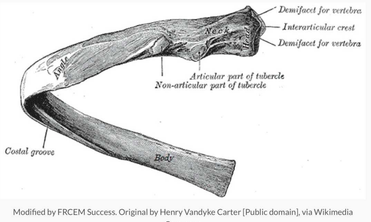


Modified by FRCEM Success. Original by Henry Vandyke Carter [Public domain], via Wikimedia Commons

**Atypical ribs**

The atypical ribs consist of ribs 1, 2, 10, 11 and 12.

| Atypical rib | Features |
|---|---|
| Rib 1 | Shorter and wider, single facet for articulation with T1, scalene tubercle |
| Rib 2 | Flat, roughened area for attachment of serratus anterior muscle |
| Rib 10 | Single facet for articulation with T10 |
| Rib 11 | No neck, single facet for articulation with T11 |
| Rib 12 | No neck, single facet for articulation with T12 |

- Rib 1 is shorter and wider than the other ribs. The head of rib 1 has only one facet for articulation with the body of its own vertebra (T1); it does NOT articulate with vertebra C7. The superior surface of rib 1 is characterised by the scalene tubercle about midway along the body, which separates two smooth grooves in the rib made by the subclavian vein anteriorly and the subclavian artery posteriorly.
- Like rib 1, rib 2 is flat but twice as long. It has a roughened area on its upper surface where the serratus anterior muscle attaches.
- The head of rib 10 only has a single facet for articulation with the body of its own vertebra (T10).
- Ribs 11 and 12 have no neck, and have only one facet for articulation with the bodies of their own vertebrae (T11 and T12).

< Previous | Next >

Something wrong?

## Question Navigator

1 Answered
2 Answered
3 Answered
4 Answered
5 Answered
6 Answered
7 Answered
8 Answered
9 Answered
10 Answered
11 Answered
12 Answered



©2014 - 2017 FRCEM Success | Website designed & hosted by Cyberfrog Design

# Anatomy: Thorax

Question 106 of 134

## Which of the following atypical ribs articulates with both its corresponding vertebra and the vertebra above:

a 1

b 2

c 10

d 11

e 12

< Previous | Next > | See Answer

Something wrong?

## Question Navigator

1 Answered
2 Answered
3 Answered
4 Answered
5 Answered
6 Answered
7 Answered
8 Answered
9 Answered
10 Answered
11 Answered
12 Answered



©2014 - 2017 FRCEM Success | Website designed & hosted by Cyberfrog Design

# Anatomy: Thorax

Question 106 of 134

Which of the following atypical ribs articulates with both its corresponding vertebra and the vertebra above:

a) 1
b) 2 ✔
c) 10
d) 11
e) 12

## Answer

The atypical ribs consist of ribs 1, 2, 10, 11 and 12. Ribs 1, 10, 11 and 12 have only a single articular facet for articulation with the bodies of their corresponding vertebrae.

## Notes

There are twelve pairs of ribs, each terminating anteriorly in a costal cartilage.

**True and False ribs**

The ribs are divided into 'true' and 'false' ribs based on their anterior attachments:

- The true ribs (1 – 7) attach directly to the sternum anteriorly.
- The false ribs (8 – 12) can be further divided into those that attach to the costal cartilage of the rib above them (8 – 10) and the floating ribs (11 + 12) that do not have any anterior attachments.

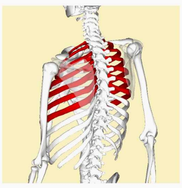

By Anatomography (en:Anatomography (setting page of this image)) [CC BY-SA 2.1 jp (http://creativecommons.org/licenses/by-sa/2.1/jp/deed.en)], via Wikimedia Commons

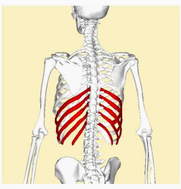

By Anatomography (en:Anatomography (setting page of this image)) [CC BY-SA 2.1 jp (http://creativecommons.org/licenses/by-sa/2.1/jp/deed.en)], via Wikimedia Commons

**Thoracic vertebrae**

Posteriorly, all of the ribs articulate with the thoracic vertebrae of the spine.

Each typical rib forms two joints posteriorly:

- the costotransverse joint (between the tubercle of the rib and the transverse process of the corresponding vertebra)
- the costovertebral joint (between the two facets on the head of the rib and the superior costal facet on the body of the corresponding vertebra, and the inferior costal facet on the body of the vertebra above).

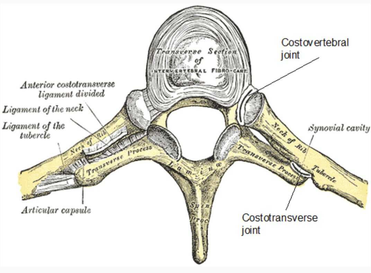


Modified by FRCEM Success. Original by Henry Vandyke Carter [Public domain], via Wikimedia Commons

**Typical ribs**

The typical rib consists of a head, a neck and a body:

- The head of the rib has two articular facets which articulate with the superior costal facet on the body of the corresponding vertebra, and the inferior costal facet on the body of the vertebra above.
- The neck of the rib connects the head to the body. Where the neck meets the body, there is a tubercle which articulates with the transverse process of the corresponding vertebra.
- The body of the rib is flat and curved.

The inferior margin of the internal surface of the body is marked by the costal groove which protects the neurovascular structures which run within it.

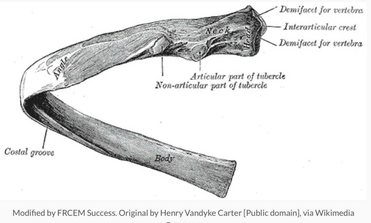


Modified by FRCEM Success. Original by Henry Vandyke Carter [Public domain], via Wikimedia Commons

**Atypical ribs**

The atypical ribs consist of ribs 1, 2, 10, 11 and 12.

| Atypical rib | Features |
|---|---|
| Rib 1 | Shorter and wider, single facet for articulation with T1, scalene tubercle |
| Rib 2 | Flat, roughened area for attachment of serratus anterior muscle |
| Rib 10 | Single facet for articulation with T10 |
| Rib 11 | No neck, single facet for articulation with T11 |
| Rib 12 | No neck, single facet for articulation with T12 |

- Rib 1 is shorter and wider than the other ribs. The head of rib 1 has only one facet for articulation with the body of its own vertebra (T1); it does NOT articulate with vertebra C7. The superior surface of rib 1 is characterised by the scalene tubercle about midway along the body, which separates two smooth grooves in the rib made by the subclavian vein anteriorly and the subclavian artery posteriorly.
- Like rib 1, rib 2 is flat but twice as long. It has a roughened area on its upper surface where the serratus anterior muscle attaches.
- The head of rib 10 only has a single facet for articulation with the body of its own vertebra (T10).
- Ribs 11 and 12 have no neck, and have only one facet for articulation with the bodies of their own vertebrae (T11 and T12).

< Previous | Next >

Something wrong?

## Question Navigator

1 Answered
2 Answered
3 Answered
4 Answered
5 Answered
6 Answered
7 Answered
8 Answered
9 Answered
10 Answered
11 Answered
12 Answered



©2014 - 2017 FRCEM Success | Website designed & hosted by Cyberfrog Design

# Anatomy: Thorax

Question 107 of 134

The T4 dermatome is best tested at which of the following landmarks:

a) At the level of the sternal angle
b) In the third intercostal space
c) **At the level of the nipples** ✔
d) At the level of the xiphoid process of the sternum
e) In the fifth intercostal space

## Answer

The T4 dermatome is best tested at the midclavicular line and the fourth intercostal space, located at the level of the nipples.

## Notes

| Dermatome | Landmark |
|---|---|
| T1 | Medial antecubital fossa |
| T2 | Apex of axilla |
| T3 | Third intercostal space |
| T4 | Level of nipples (fourth intercostal space) |
| T5 | Fifth intercostal space |
| T6 | Level of xiphisternum |
| T7 | One-quarter distance between xiphisternum and umbilicus |
| T8 | One-half distance between xiphisternum and umbilicus |
| T9 | Three-quarter distance between xiphisternum and umbilicus |
| T10 | Level of umbilicus |
| T11 | Midway between umbilicus and inguinal ligament |
| T12 | Midpoint of inguinal ligament |

**Dermatome assessment**

- The T1 dermatome is best tested on the medial (ulnar) side of the antecubital fossa, just proximal to the medial epicondyle of the humerus.
- The T2 dermatome is best tested at the apex of the axilla.
- The T3 dermatome is best tested at the midclavicular line and the third intercostal space.
- The T4 dermatome is best tested at the midclavicular line and the fourth intercostal space, located at the level of the nipples.
- The T5 dermatome is best tested at the midclavicular line and the fifth intercostal space, located midway between the level of the nipples and the level of the xiphisternum.
- The T6 dermatome is best tested at the midclavicular line, located at the level of the xiphisternum.
- The T7 dermatome is best tested at the midclavicular line, one quarter the distance between the level of the xiphisternum and the level of the umbilicus.
- The T8 dermatome is best tested at the midclavicular line, one half the distance between the level of the xiphisternum and the level of the umbilicus.
- The T9 dermatome is best tested at the midclavicular line, three quarters of the distance between the level of the xiphisternum and the level of the umbilicus.
- The T10 dermatome is best tested at the midclavicular line, located at the level of the umbilicus.
- The T11 dermatome is best tested at the midclavicular line, midway between the level of the umbilicus and the inguinal ligament.
- The T12 dermatome is best tested at the midclavicular line, over the midpoint of the inguinal ligament.

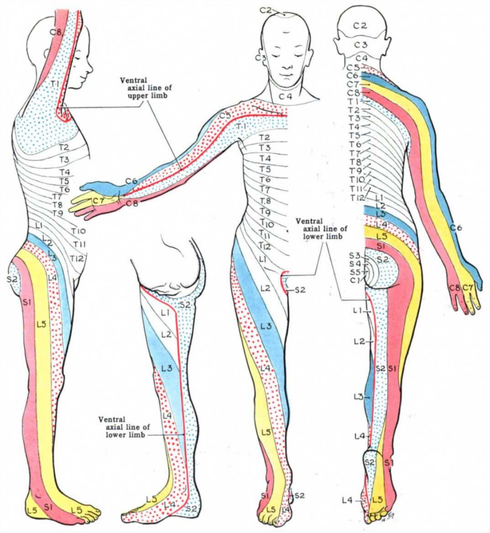


By Grant, John Charles Boileau (An atlas of anatomy. / by regions 1962) [Public domain], via Wikimedia Commons

< Previous | Next >

Something wrong?

## Question Navigator

1 Answered
2 Answered
3 Answered
4 Answered
5 Answered
6 Answered
7 Answered
8 Answered
9 Answered
10 Answered
11 Answered
12 Answered



©2014 - 2017 FRCEM Success | Website designed & hosted by Cyberfrog Design

# Anatomy: Thorax

Question 108 of 134

## The inferior border of the heart is formed predominantly by which of the following:

a Right atrium

b Left atrium

c Right ventricle

d Left ventricle

e Great vessels

< Previous | Next > | See Answer

Something wrong?

## Question Navigator

1 Answered
2 Answered
3 Answered
4 Answered
5 Answered
6 Answered
7 Answered
8 Answered
9 Answered
10 Answered
11 Answered
12 Answered



©2014 - 2017 FRCEM Success | Website designed & hosted by Cyberfrog Design

# Anatomy: Thorax

Question 108 of 134

The inferior border of the heart is formed predominantly by which of the following:

**a)** Right atrium
**b)** Left atrium
**c)** **Right ventricle** ✔
**d)** Left ventricle
**e)** Great vessels

## Answer

The inferior border is formed mostly by the right ventricle and a small portion of the left ventricle near the apex.

## Notes

| Border/Surface | Main structure (contributing structures) |
|---|---|
| Apex | Left ventricle |
| Base | Left atrium (right atrium, proximal great veins) |
| Anterior surface | Right ventricle (right atrium, left ventricle) |
| Inferior surface | Left and right ventricle |
| Left pulmonary surface | Left ventricle (left atrium) |
| Right pulmonary surface | Right atrium |
| Inferior border | Right ventricle (left ventricle) |
| Left border | Left ventricle (left auricle) |
| Right border | Right atrium |
| Superior border | Both atria, roots of great vessels |

The general shape and orientation of the heart are that of a pyramid that has fallen over and is resting on one of its sides.

- The apex of this pyramid projects forwards, downwards and to the left. The apex is formed by the inferolateral part of the left ventricle and is positioned deep to the left fifth intercostal space in the midclavicular line.
- The base is facing posteriorly. The base is formed mostly by the left atrium with a small portion of the right atrium and the proximal part of the great veins, and is fixed posteriorly to the pericardial wall, opposite the bodies of the T5 – T8 vertebrae (T6 – T9 when standing). The oesophagus lies immediately posterior to the base.

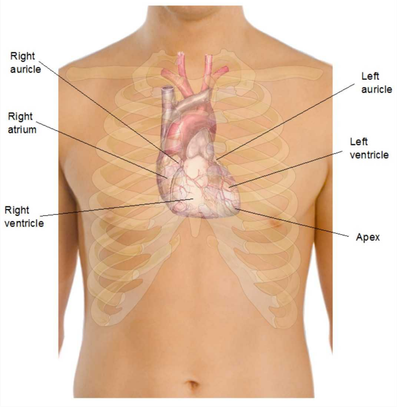


Modified by FRCEM Success. Original by Mikael Häggström (See above. All used images are in public domain.) [Public domain], via Wikimedia Commons

**Surfaces**

There are four surfaces to the upturned pyramid:

- The anterior (sternocostal) surface consists mostly of the right ventricle with some of the right atrium and some of the left ventricle.
- The inferior (diaphragmatic) surface consists of the left ventricle with a small portion of the right ventricle separated by the posterior interventricular groove.
- The left pulmonary surface consists mainly of the left ventricle and a portion of the left atrium.
- The right pulmonary surface consists of the right atrium.

**Borders**

There are four main borders separating the surfaces of the heart:

- The inferior border is formed mostly by the right ventricle and a small portion of the left ventricle near the apex.
- The left border is formed mostly by the left ventricle with a small portion of the left auricle.
- The right border is formed by the right atrium.
- The superior border is formed by both atria and the roots of the great vessels.

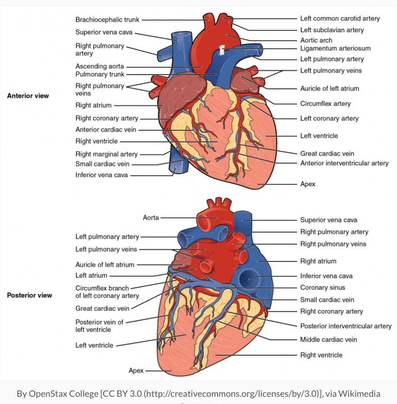


By OpenStax College [CC BY 3.0 (http://creativecommons.org/licenses/by/3.0)], via Wikimedia Commons

< Previous | Next >

Something wrong?

## Question Navigator

1 Answered
2 Answered
3 Answered
4 Answered
5 Answered
6 Answered
7 Answered
8 Answered
9 Answered
10 Answered
11 Answered
12 Answered



©2014 - 2017 FRCEM Success | Website designed & hosted by Cyberfrog Design

# Anatomy: Thorax

Question 109 of 134

## At rest the right dome of the diaphragm normally reaches as high as which of the following:

a Third rib

b Fourth rib

c Fourth intercostal space

d Fifth intercostal space

e Fifth rib

< Previous | Next > | See Answer

Something wrong?

Question Navigator

1 Answered
2 Answered
3 Answered
4 Answered
5 Answered
6 Answered
7 Answered
8 Answered
9 Answered
10 Answered
11 Answered
12 Answered



©2014 - 2017 FRCEM Success | Website designed & hosted by Cyberfrog Design

# Anatomy: Thorax

Question 109 of 134

At rest the right dome of the diaphragm normally reaches as high as which of the following:

**a)** Third rib
**b)** Fourth rib
**c)** Fourth intercostal space
**d)** Fifth intercostal space
**e)** **Fifth rib** ✔

## Answer

At rest the right dome of the diaphragm lies slightly higher than the left; this is thought to be due to the position of the liver. In normal expiration, the normal upper limits of the superior margins are the fifth rib for the right dome, the fifth intercostal space for the left dome and the xiphoid process for the central tendon.

## Notes

The diaphragm is a musculotendinous structure that separates the thoracic cavity from the abdominal cavity.

| Structure | Diaphragm |
|---|---|
| Primary function | Respiration – contraction of diaphragm flattens diaphragm increasing vertical dimension of thorax (inspiration), relaxation of diaphragm elevates diaphragm decreasing vertical dimension of thorax (expiration) |
| Secondary functions | Assists in straining movements by increasing intra-abdominal pressure, acts as functional sphincter on oesophagus preventing acid reflux |
| Peripheral attachments | Xiphoid process of sternum, costal cartilages ribs 7 – 10, ends of ribs 11 and 12, arcuate ligaments and lumbar vertebrae |
| Central attachment | Fuses with fibrous pericardium superiorly |
| Surface markings | Attachments: vertebrae T8/T9 anteriorly, vertebra T12 posteriorly, Domes: right dome 5th rib, left dome 5th intercostal space |
| Openings | Oesophageal opening at T10 (oesophagus, vagus nerve), aortic opening at T12 (aorta, thoracic duct and azygos vein), caval opening at T8 (inferior vena cava and right phrenic nerve) |
| Innervation | Phrenic nerve (C3 – C5) |

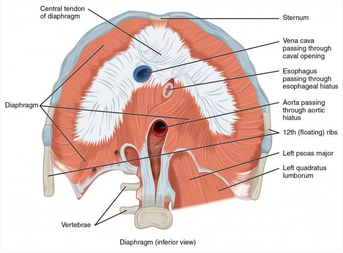


By OpenStax [CC BY 4.0 (http://creativecommons.org/licenses/by/4.0)], via Wikimedia Commons

**Function**

The diaphragm performs an important function in respiration; contraction of the domes of the diaphragm in inspiration flattens the diaphragm, increasing the vertical dimension of the thorax and vice versa in expiration, with relaxation and elevation of the diaphragm reducing the vertical dimension of the thorax.

The diaphragm is also involved in non-respiratory functions; helping to expel vomit, faeces, and urine from the body by increasing intraabdominal pressure, and preventing acid reflux by exerting pressure on the oesophagus as it passes through the oesophageal opening.

**Attachments**

The diaphragm is attached peripherally to:

- the xiphoid process of the sternum and the costal cartilages of ribs 7 – 10 (the costal margin) anteriorly
- the ends of ribs 11 and 12 laterally
- the arcuate ligaments and vertebrae posteriorly.

From these peripheral attachments, muscle fibres converge to form the central tendon which fuses with the fibrous pericardium superiorly.

**Surface markings**

In the medial sagittal plane, the diaphragm slopes inferiorly from its anterior attachment to the xiphoid at approximately vertebral level T8/T9 to its posterior attachment to the median arcuate ligament at approximately vertebral level T12.

At rest the right dome of the diaphragm lies slightly higher than the left; this is thought to be due to the position of the liver. In normal expiration, the normal upper limits of the superior margins are the fifth rib for the right dome, the fifth intercostal space for the left dome and the xiphoid process for the central tendon.

**Diaphragmatic openings**

Structures travelling between the thorax and abdomen must pass through the diaphragm via three main openings.

The oesophageal opening at vertebral level T10 transmits:

- the oesophagus
- the anterior and posterior vagal trunks
- oesophageal branches of the left gastric vessels
- a few lymphatics.

The aortic opening at vertebral level T12 transmits:

- the aorta
- the thoracic duct
- the azygos vein and sometimes the hemiazygos vein.

The caval opening at vertebral level T8 transmits:

- the inferior vena cava
- the right phrenic nerve.

**Innervation**

The entire motor supply of the diaphragm is from the right and left phrenic nerves (C3 – C5) which penetrate the diaphragm and innervate it from its abdominal surface.

Damage to the phrenic nerve will result in hemiparalysis of the diaphragm. Paralysis of the diaphragm produces a paradoxical movement. The affected side of the diaphragm moves upwards during inspiration (as it is pushed superiorly by the abdominal viscera that are being actively compressed by the other half), and downwards during expiration.

A unilateral diaphragmatic paralysis is usually asymptomatic, and is most often an incidental finding on x-ray. If both sides are paralysed, the patient may experience poor exercise tolerance, orthopnoea and fatigue. Lung function tests will show a restrictive deficit.

**Diaphragmatic herniation**

Diaphragmatic hernias are defined as congenital or acquired defects in the diaphragm. There are two main types of congenital diaphragmatic hernias; Bochdalek hernias and Morgagni hernias.

Acquired diaphragmatic hernias include traumatic diaphragmatic rupture, hiatus hernia and iatrogenic diaphragmatic hernias. Depending on the location and size of the defect, retroperitoneal or intra-abdominal organs and tissues can prolapse into the thoracic cavity due to the negative intrathoracic pressure.

Diaphragmatic rupture usually results from blunt abdominal trauma, which is typically associated with motor-vehicle accidents; the most commonly herniated viscera are the stomach and colon on the left side, and the liver on the right side.

In hiatus hernia, the stomach herniates through the oesophageal opening of the diaphragm, typically resulting in symptoms of acid reflux.

< Previous | Next >

Something wrong?

Question Navigator

1 Answered
2 Answered
3 Answered
4 Answered
5 Answered
6 Answered
7 Answered
8 Answered
9 Answered
10 Answered
11 Answered
12 Answered



©2014 - 2017 FRCEM Success | Website designed & hosted by Cyberfrog Design

# Anatomy: Thorax

Question 110 of 134

## The sinoatrial node is located at which of the following sites:

a Interatrial septum

b Atrioventricular septum

c Inferior right atrium

d Junction of the superior vena cava and the right atrium

e Wall of left atrium

< Previous | Next > | See Answer

Something wrong?

## Question Navigator

1 Answered
2 Answered
3 Answered
4 Answered
5 Answered
6 Answered
7 Answered
8 Answered
9 Answered
10 Answered
11 Answered
12 Answered



©2014 - 2017 FRCEM Success | Website designed & hosted by Cyberfrog Design

# Anatomy: Thorax

Question 110 of 134

The sinoatrial node is located at which of the following sites:

a) Interatrial septum
b) Atrioventricular septum
c) Inferior right atrium
d) **Junction of the superior vena cava and the right atrium** ✔
e) Wall of left atrium

## Answer

The sinoatrial node, the cardiac pacemaker, is located at the superior end of the crista terminalis at the junction of the superior vena cava and the right atrium.

## Notes

The cardiac conduction system initiates and coordinates contraction of the heart.

The sinoatrial node, the cardiac pacemaker, is located at the superior end of the crista terminalis at the junction of the superior vena cava and the right atrium.

Impulses generated by the sinoatrial node are propagated by the atrial myocardium to the atrioventricular node located near the opening of the coronary sinus, close to the attachment of the septal cusp of the tricuspid valve and within the atrioventricular septum. Here the impulse is briefly delayed before being spread to the ventricles.

The atrioventricular bundle (bundle of His) is a direct continuation of the atrioventricular node and continues along the lower margin of the membranous part of the interventricular septum before dividing into the right and left bundles which continue themselves as Purkinje fibres, the final component of the conducting system.

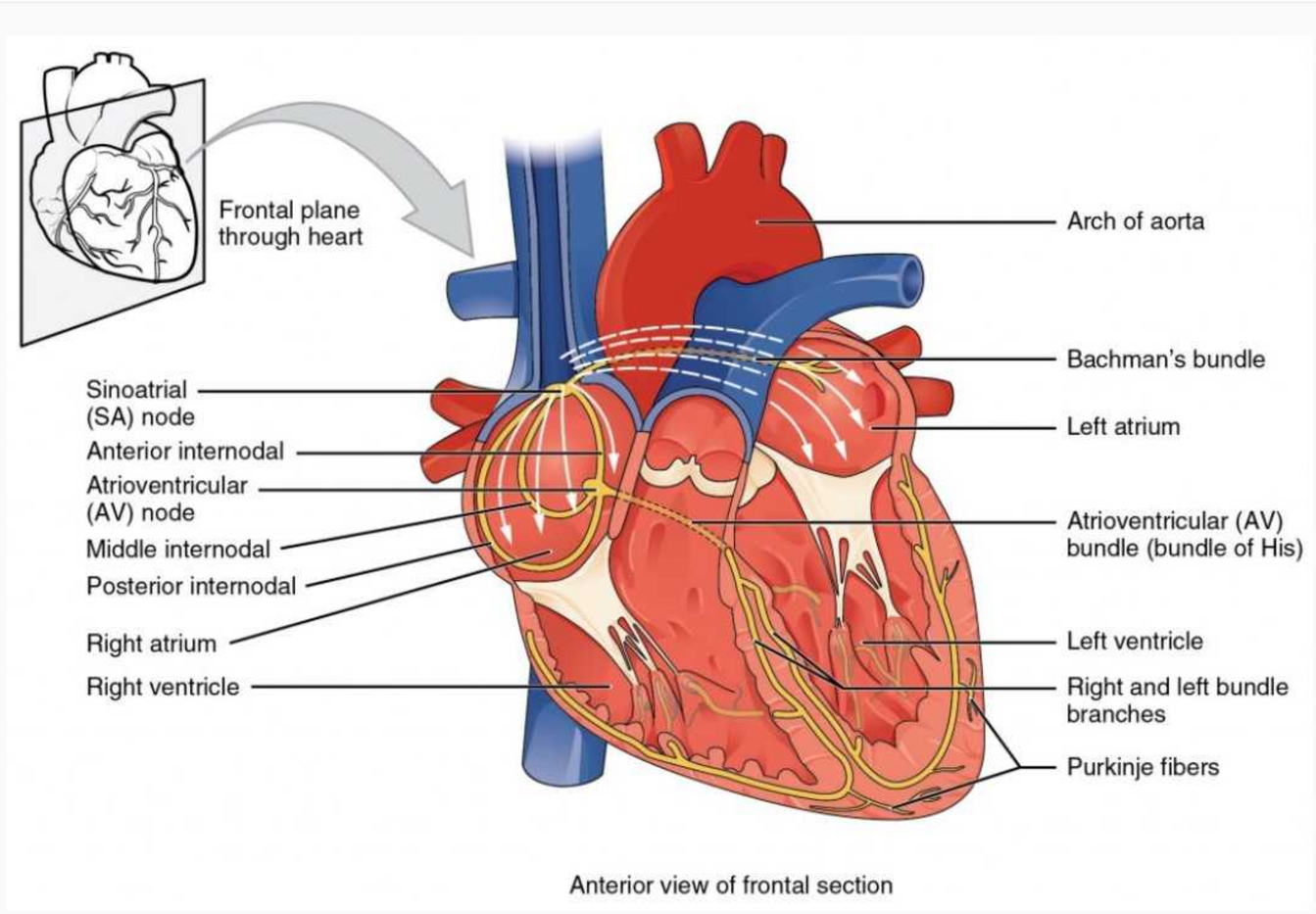


By OpenStax College [CC BY 3.0 (http://creativecommons.org/licenses/by/3.0)], via Wikimedia Commons

< Previous | Next >

Something wrong?

## Question Navigator

1 Answered
2 Answered
3 Answered
4 Answered
5 Answered
6 Answered
7 Answered
8 Answered
9 Answered
10 Answered
11 Answered
12 Answered



©2014 - 2017 FRCEM Success | Website designed & hosted by Cyberfrog Design

# Anatomy: Thorax

Question 111 of 134

## A 45 year old patient presents to ED complaining of left sided chest pain and breathlessness. Imaging shows a large left sided pleural effusion. When he sits up for you to examine him, where would the fluid tend to accumulate:

a Middle mediastinum

b Costomediastinal recess

c Costodiaphragmatic recess

d Between the lungs and the visceral pleura

e Cardiac notch

< Previous | Next > | See Answer

Something wrong?

Question Navigator

1 Answered
2 Answered
3 Answered
4 Answered
5 Answered
6 Answered
7 Answered
8 Answered
9 Answered
10 Answered
11 Answered
12 Answered



©2014 - 2017 FRCEM Success | Website designed & hosted by Cyberfrog Design

# Anatomy: Thorax

Question 111 of 134

A 45 year old patient presents to ED complaining of left sided chest pain and breathlessness. Imaging shows a large left sided pleural effusion. When he sits up for you to examine him, where would the fluid tend to accumulate:

**a)** Middle mediastinum
**b)** Costomediastinal recess
**c)** **Costodiaphragmatic recess** ✔
**d)** Between the lungs and the visceral pleura
**e)** Cardiac notch

## Answer

The costodiaphragmatic recess is the lowest extent of the pleural cavity, below the inferior margin of the lung. Fluid in the pleural cavity will accumulate here when a patient sits/stands up and thus it is useful space in which to perform pleural aspiration.

## Notes

Each lung is surrounded by a pleura. The pleura consists of two parts, the parietal pleura (which lines the thoracic cavity) and the visceral pleura (which lines the lungs). The two parts of the pleura are continuous with each other at the hilum of each lung. The potential space between these two parts of the pleura is called the pleural cavity.

**Pleural cavity**

The pleural cavity normally contains a small amount of lubricating fluid to allow the visceral pleura attached to the lungs to smoothly slide over the parietal pleura attached to the thoracic wall during respiration. The serous fluid also produces a surface tension, pulling the parietal and visceral pleura together. This ensures that when the thorax expands, the lung also expands, filling with air.

**Innervation**

The parietal pleura is innervated by somatic afferent fibres. The costal pleura (pleura related to the ribs and intercostal spaces) is innervated by branches of the intercostal nerves, and pain is felt in relation to the thoracic wall. The diaphragmatic pleura (covering the diaphragm) and the mediastinal pleura (covering the mediastinum) are innervated mainly by the phrenic nerves (C3 – C5), and pain is referred the the C3 – C5 dermatomes (lateral neck and supraclavicular region of shoulder).

Although the visceral pleura is innervated by visceral afferent fibres, pain is not generally elicited from this tissue.

**Surface markings**

Superiorly the pleural cavity projects as much as 3 – 4 cm above the first costal cartilage but does not extend above the neck of rib 1.

Anteriorly the pleurae approach each other posterior to the upper part of the sternum. At the lower part of the sternum the left pleura does not come as close to the midline as the right pleura because the middle mediastinum bulges to the left.

Inferiorly the pleura reflects onto the diaphragm above the costal margin. The inferior margin of the pleural cavity is a line that runs between rib 8 in the midclavicular line, rib 10 in the midaxillary line and vertebra T12 posteriorly.

The inferior margin of the lung in quiet respiration is a line that runs between rib 6 in the midclavicular line, rib 8 in the midaxillary line and vertebra T10 posteriorly.

The lungs therefore do not completely fill the pleural cavities, producing two pleural recesses, the costomediastinal and costodiaphragmatic recesses, in which fluids can collect.

The costomediastinal recess occurs on each side where the the costal pleura is opposed to mediastinal pleura, particularly on the left side in the region overlying the heart.

The costodiaphragmatic recess occurs between the costal and diaphragmatic pleura. It is the region between the inferior margin of the lung and the inferior margin of the pleural cavity and is clinically important for pleural aspiration.

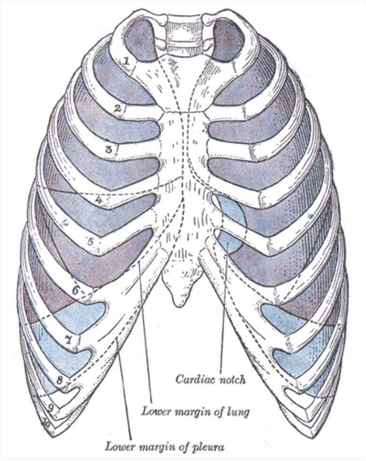


By Henry Vandyke Carter [Public domain], via Wikimedia Commons

< Previous | Next >

Something wrong?

## Question Navigator

1 Answered
2 Answered
3 Answered
4 Answered
5 Answered
6 Answered
7 Answered
8 Answered
9 Answered
10 Answered
11 Answered
12 Answered



©2014 - 2017 FRCEM Success | Website designed & hosted by Cyberfrog Design

# Anatomy: Thorax

Question 112 of 134

## The lower limit of the heart on the right side of the sternum is the:

a Third costal cartilage

b Fourth costal cartilage

c Fifth costal cartilage

d Sixth costal cartilage

e Seventh costal cartilage

< Previous | Next > | See Answer

Something wrong?

## Question Navigator

1 Answered
2 Answered
3 Answered
4 Answered
5 Answered
6 Answered
7 Answered
8 Answered
9 Answered
10 Answered
11 Answered
12 Answered



©2014 - 2017 FRCEM Success | Website designed & hosted by Cyberfrog Design

# Anatomy: Thorax

Question 112 of 134

The lower limit of the heart on the right side of the sternum is the:

a) Third costal cartilage
b) Fourth costal cartilage
c) Fifth costal cartilage
d) **Sixth costal cartilage** ✔
e) Seventh costal cartilage

## Answer

The lower limit of the heart extends from the sternal end of the right sixth costal cartilage to the apex in the fifth intercostal space near the midclavicular line.

## Notes

Surface markings

| Heart | Surface marking |
|---|---|
| Right upper limit | Third costal cartilage |
| Left upper limit | Second intercostal space |
| Right lower limit | Sixth costal cartilage |
| Left lower limit | Fifth intercostal space |

The upper limit of the heart reaches as high as the third costal cartilage on the right side of the sternum and the second intercostal space on the left side of the sternum.

The lower limit of the heart extends from the sternal end of the right sixth costal cartilage to the apex in the fifth intercostal space near the midclavicular line.

The right margin of the heart therefore extends from the right third costal cartilage to near the right sixth costal cartilage and the left margin of the heart extends from the left second intercostal space to the apex located near the midclavicular line in the fifth intercostal space.

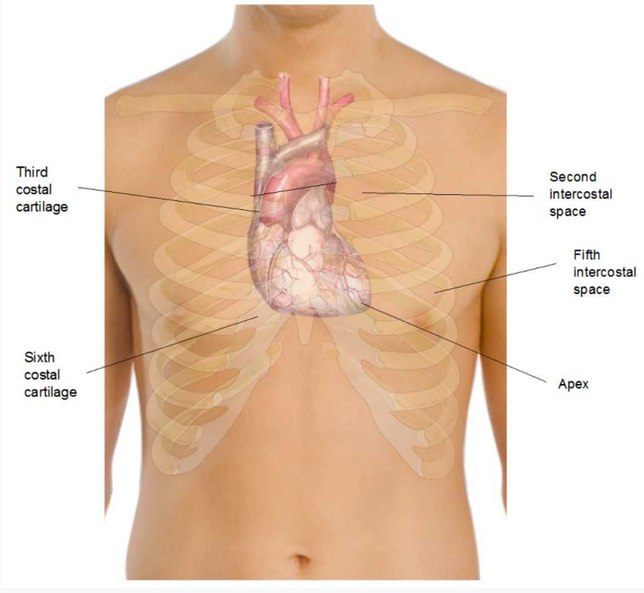


Modified by FRCEM Success. Original by Mikael Häggström[Public domain], via Wikimedia Commons

< Previous | Next >

Something wrong?

## Question Navigator

1 Answered
2 Answered
3 Answered
4 Answered
5 Answered
6 Answered
7 Answered
8 Answered
9 Answered
10 Answered
11 Answered
12 Answered



©2014 - 2017 FRCEM Success | Website designed & hosted by Cyberfrog Design

# Anatomy: Thorax

Question 113 of 134

## The upper limit of the heart on the left side of the sternum is the:

a First intercostal space

b Second intercostal space

c Third intercostal space

d Fourth intercostal space

e Fifth intercostal space

< Previous | Next > | See Answer

Something wrong?

## Question Navigator

1 Answered
2 Answered
3 Answered
4 Answered
5 Answered
6 Answered
7 Answered
8 Answered
9 Answered
10 Answered
11 Answered
12 Answered



©2014 - 2017 FRCEM Success | Website designed & hosted by Cyberfrog Design

# Anatomy: Thorax

Question 113 of 134

The upper limit of the heart on the left side of the sternum is the:

a) First intercostal space
b) **Second intercostal space** ✔
c) Third intercostal space
d) Fourth intercostal space
e) Fifth intercostal space

## Answer

The upper limit of the heart reaches as high as the third costal cartilage on the right side of the sternum and the second intercostal space on the left side of the sternum.

## Notes

Surface markings

| Heart | Surface marking |
|---|---|
| Right upper limit | Third costal cartilage |
| Left upper limit | Second intercostal space |
| Right lower limit | Sixth costal cartilage |
| Left lower limit | Fifth intercostal space |

The upper limit of the heart reaches as high as the third costal cartilage on the right side of the sternum and the second intercostal space on the left side of the sternum.

The lower limit of the heart extends from the sternal end of the right sixth costal cartilage to the apex in the fifth intercostal space near the midclavicular line.

The right margin of the heart therefore extends from the right third costal cartilage to near the right sixth costal cartilage and the left margin of the heart extends from the left second intercostal space to the apex located near the midclavicular line in the fifth intercostal space.

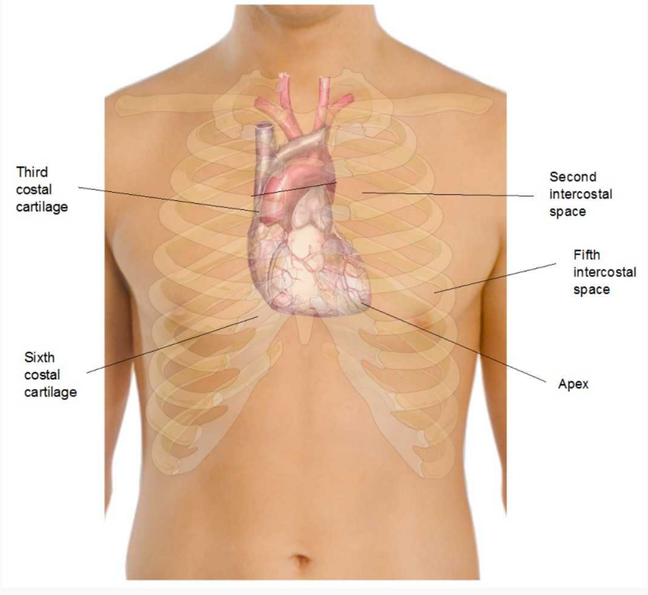


Modified by FRCEM Success. Original by Mikael Häggström[Public domain], via Wikimedia Commons

< Previous | Next >

Something wrong?

## Question Navigator

1 Answered
2 Answered
3 Answered
4 Answered
5 Answered
6 Answered
7 Answered
8 Answered
9 Answered
10 Answered
11 Answered
12 Answered



©2014 - 2017 FRCEM Success | Website designed & hosted by Cyberfrog Design

# Anatomy: Thorax

Question 114 of 134

## The base of the heart is formed predominantly by which of the following:

a Right atrium and right ventricle

b Left atrium and proximal great veins

c Left atrium and left ventricle

d Right and left ventricle

e Left ventricle

< Previous | Next > | See Answer

Something wrong?

## Question Navigator

1 Answered
2 Answered
3 Answered
4 Answered
5 Answered
6 Answered
7 Answered
8 Answered
9 Answered
10 Answered
11 Answered
12 Answered



©2014 - 2017 FRCEM Success | Website designed & hosted by Cyberfrog Design

# Anatomy: Thorax

Question 114 of 134

The base of the heart is formed predominantly by which of the following:

a) Right atrium and right ventricle
b) Left atrium and proximal great veins ✔
c) Left atrium and left ventricle
d) **Right and left ventricle** ✖
e) Left ventricle

## Answer

The base is formed mostly by the left atrium with a small portion of the right atrium and the proximal part of the great veins, and is fixed posteriorly to the pericardial wall, opposite the bodies of the T5 – T8 vertebrae (T6 – T9 when standing).

## Notes

| Border/Surface | Main structure (contributing structures) |
|---|---|
| Apex | Left ventricle |
| Base | Left atrium (right atrium, proximal great veins) |
| Anterior surface | Right ventricle (right atrium, left ventricle) |
| Inferior surface | Left and right ventricle |
| Left pulmonary surface | Left ventricle (left atrium) |
| Right pulmonary surface | Right atrium |
| Inferior border | Right ventricle (left ventricle) |
| Left border | Left ventricle (left auricle) |
| Right border | Right atrium |
| Superior border | Both atria, roots of great vessels |

The general shape and orientation of the heart are that of a pyramid that has fallen over and is resting on one of its sides.

- The apex of this pyramid projects forwards, downwards and to the left. The apex is formed by the inferolateral part of the left ventricle and is positioned deep to the left fifth intercostal space in the midclavicular line.
- The base is facing posteriorly. The base is formed mostly by the left atrium with a small portion of the right atrium and the proximal part of the great veins, and is fixed posteriorly to the pericardial wall, opposite the bodies of the T5 – T8 vertebrae (T6 – T9 when standing). The oesophagus lies immediately posterior to the base.

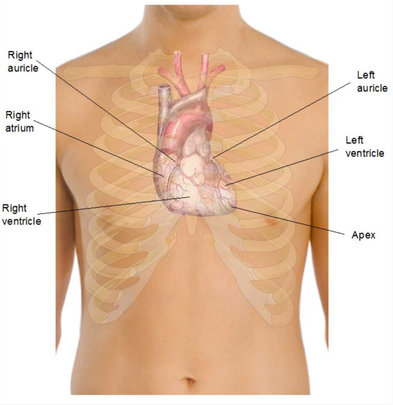


Modified by FRCEM Success. Original by Mikael Häggström (See above. All used images are in public domain.) [Public domain], via Wikimedia Commons

**Surfaces**

There are four surfaces to the upturned pyramid:

- The anterior (sternocostal) surface consists mostly of the right ventricle with some of the right atrium and some of the left ventricle.
- The inferior (diaphragmatic) surface consists of the left ventricle with a small portion of the right ventricle separated by the posterior interventricular groove.
- The left pulmonary surface consists mainly of the left ventricle and a portion of the left atrium.
- The right pulmonary surface consists of the right atrium.

**Borders**

There are four main borders separating the surfaces of the heart:

- The inferior border is formed mostly by the right ventricle and a small portion of the left ventricle near the apex.
- The left border is formed mostly by the left ventricle with a small portion of the left auricle.
- The right border is formed by the right atrium.
- The superior border is formed by both atria and the roots of the great vessels.

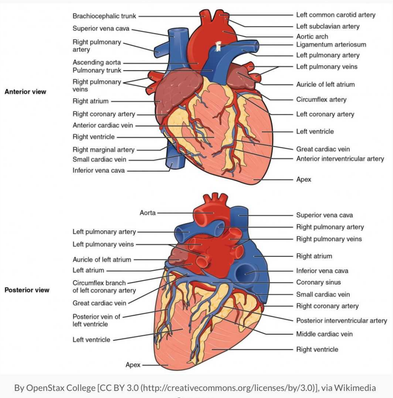


By OpenStax College [CC BY 3.0 (http://creativecommons.org/licenses/by/3.0)], via Wikimedia Commons

## Question Navigator

1 Answered
2 Answered
3 Answered
4 Answered
5 Answered
6 Answered
7 Answered
8 Answered
9 Answered
10 Answered
11 Answered
12 Answered

< Previous | Next >

Something wrong?



©2014 - 2017 FRCEM Success | Website designed & hosted by Cyberfrog Design

# Anatomy: Thorax

Question 115 of 134

## Which of the following best describes the relationship of the ascending aorta and the pulmonary trunk as they emerge from their orifices:

a The pulmonary trunk lies posterior to and then to the left of the ascending aorta.

b The pulmonary trunk lies anterior to and then to the right of the ascending aorta.

c The pulmonary trunk lies posterior to and then to the right of the ascending aorta.

d The pulmonary trunk lies anterior to and then to the left of the ascending aorta.

e The ascending aorta lies to the left of the pulmonary trunk.

< Previous | Next > | See Answer

Something wrong?

Question Navigator

1 Answered
2 Answered
3 Answered
4 Answered
5 Answered
6 Answered
7 Answered
8 Answered
9 Answered
10 Answered
11 Answered
12 Answered



©2014 - 2017 FRCEM Success | Website designed & hosted by Cyberfrog Design

# Anatomy: Thorax

Question 115 of 134

Which of the following best describes the relationship of the ascending aorta and the pulmonary trunk as they emerge from their orifices:

a) The pulmonary trunk lies posterior to and then to the left of the ascending aorta.
b) The pulmonary trunk lies anterior to and then to the right of the ascending aorta.
c) The pulmonary trunk lies posterior to and then to the right of the ascending aorta.
d) **The pulmonary trunk lies anterior to and then to the left of the ascending aorta.** ✔
e) The ascending aorta lies to the left of the pulmonary trunk.

## Answer

The pulmonary trunk ascends, moving posteriorly and to the left, lying initially anterior and then to the left of the ascending aorta, before bifurcating into the right and left pulmonary arteries posterior to the left second intercostal space.

## Notes

The ascending aorta arises from the aortic orifice at the base of the left ventricle, at the level of the lower edge of the third left costal cartilage, posterior to the left half of the sternum. The ascending aorta ascends, moving slightly forwards and to the right, before continuing as the arch of the aorta posterior to the second right costal cartilage.

The pulmonary trunk arises from the conus arteriosus of the right ventricle slightly anterior to the aortic orifice, posterior to the left third costal cartilage. The pulmonary trunk ascends, moving posteriorly and to the left, lying initially anterior and then to the left of the ascending aorta, before bifurcating into the right and left pulmonary arteries posterior to the left second intercostal space.

The pulmonary trunk and the ascending aorta are contained within the pericardial sac, lined by serous pericardium and within a common sheath.

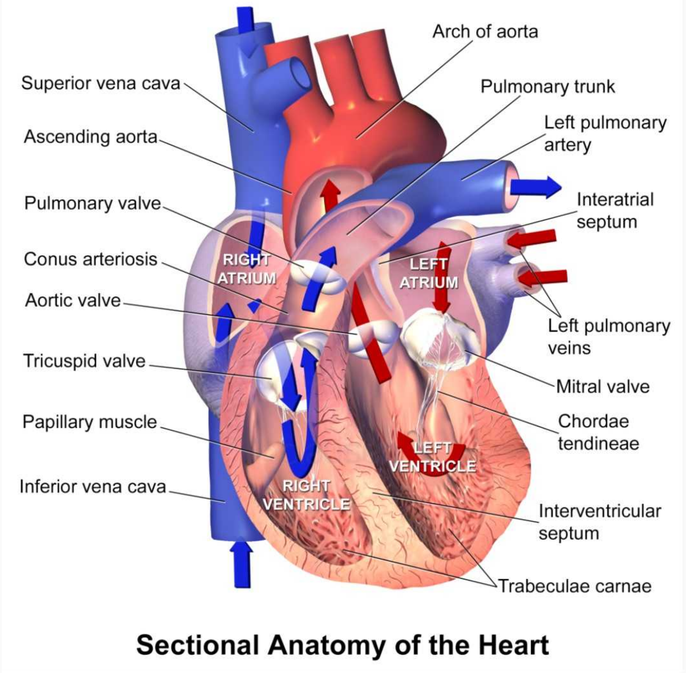


**Sectional Anatomy of the Heart**

By Blausen Medical Communications, Inc. [CC BY 3.0 (http://creativecommons.org/licenses/by/3.0)], via Wikimedia Commons

< Previous | Next >

Something wrong?

## Question Navigator

1 Answered
2 Answered
3 Answered
4 Answered
5 Answered
6 Answered
7 Answered
8 Answered
9 Answered
10 Answered
11 Answered
12 Answered



©2014 - 2017 FRCEM Success | Website designed & hosted by Cyberfrog Design

# Anatomy: Thorax

Question 116 of 134

## The motor supply of the diaphragm is from which of the following nerves:

a Right and left phrenic nerves

b Right phrenic nerve and vagus nerve

c Vagus nerve

d Left phrenic nerve and vagus nerve

e Right and left vagus nerve

< Previous | Next > | See Answer

Something wrong?

Question Navigator

1 Answered
2 Answered
3 Answered
4 Answered
5 Answered
6 Answered
7 Answered
8 Answered
9 Answered
10 Answered
11 Answered
12 Answered



©2014 - 2017 FRCEM Success | Website designed & hosted by Cyberfrog Design

# Anatomy: Thorax

Question 116 of 134

The motor supply of the diaphragm is from which of the following nerves:

**a) Right and left phrenic nerves** ✔
**b)** Right phrenic nerve and vagus nerve
**c)** Vagus nerve
**d)** Left phrenic nerve and vagus nerve
**e)** Right and left vagus nerve

## Answer

The entire motor supply of the diaphragm is from the right and left phrenic nerves (C3 – C5) which penetrate the diaphragm and innervate it from its abdominal surface.

## Notes

The diaphragm is a musculotendinous structure that separates the thoracic cavity from the abdominal cavity.

| Structure | Diaphragm |
|---|---|
| Primary function | Respiration – contraction of diaphragm flattens diaphragm increasing vertical dimension of thorax (inspiration), relaxation of diaphragm elevates diaphragm decreasing vertical dimension of thorax (expiration) |
| Secondary functions | Assists in straining movements by increasing intra-abdominal pressure, acts as functional sphincter on oesophagus preventing acid reflux |
| Peripheral attachments | Xiphoid process of sternum, costal cartilages ribs 7 – 10, ends of ribs 11 and 12, arcuate ligaments and lumbar vertebrae |
| Central attachment | Fuses with fibrous pericardium superiorly |
| Surface markings | Attachments: vertebrae T8/T9 anteriorly, vertebra T12 posteriorly, Domes: right dome 5th rib, left dome 5th intercostal space |
| Openings | Oesophageal opening at T10 (oesophagus, vagus nerve), aortic opening at T12 (aorta, thoracic duct and azygos vein), caval opening at T8 (inferior vena cava and right phrenic nerve) |
| Innervation | Phrenic nerve (C3 – C5) |

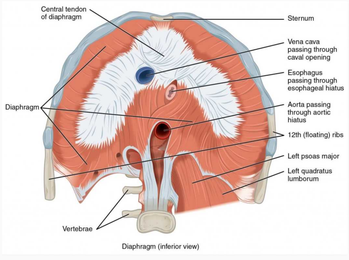


By OpenStax [CC BY 4.0 (http://creativecommons.org/licenses/by/4.0)], via Wikimedia Commons

### Function

The diaphragm performs an important function in respiration; contraction of the domes of the diaphragm in inspiration flattens the diaphragm, increasing the vertical dimension of the thorax and vice versa in expiration, with relaxation and elevation of the diaphragm reducing the vertical dimension of the thorax.

The diaphragm is also involved in non-respiratory functions; helping to expel vomit, faeces, and urine from the body by increasing intraabdominal pressure, and preventing acid reflux by exerting pressure on the oesophagus as it passes through the oesophageal opening.

### Attachments

The diaphragm is attached peripherally to:

- the xiphoid process of the sternum and the costal cartilages of ribs 7 – 10 (the costal margin) anteriorly
- the ends of ribs 11 and 12 laterally
- the arcuate ligaments and vertebrae posteriorly.

From these peripheral attachments, muscle fibres converge to form the central tendon which fuses with the fibrous pericardium superiorly.

### Surface markings

In the medial sagittal plane, the diaphragm slopes inferiorly from its anterior attachment to the xiphoid at approximately vertebral level T8/T9 to its posterior attachment to the median arcuate ligament at approximately vertebral level T12.

At rest the right dome of the diaphragm lies slightly higher than the left; this is thought to be due to the position of the liver. In normal expiration, the normal upper limits of the superior margins are the fifth rib for the right dome, the fifth intercostal space for the left dome and the xiphoid process for the central tendon.

### Diaphragmatic openings

Structures travelling between the thorax and abdomen must pass through the diaphragm via three main openings.

The oesophageal opening at vertebral level T10 transmits:

- the oesophagus
- the anterior and posterior vagal trunks
- oesophageal branches of the left gastric vessels
- a few lymphatics.

The aortic opening at vertebral level T12 transmits:

- the aorta
- the thoracic duct
- the azygos vein and sometimes the hemiazygos vein.

The caval opening at vertebral level T8 transmits:

- the inferior vena cava
- the right phrenic nerve.

### Innervation

The entire motor supply of the diaphragm is from the right and left phrenic nerves (C3 – C5) which penetrate the diaphragm and innervate it from its abdominal surface.

Damage to the phrenic nerve will result in hemiparalysis of the diaphragm. Paralysis of the diaphragm produces a paradoxical movement. The affected side of the diaphragm moves upwards during inspiration (as it is pushed superiorly by the abdominal viscera that are being actively compressed by the other half), and downwards during expiration.

A unilateral diaphragmatic paralysis is usually asymptomatic, and is most often an incidental finding on x-ray. If both sides are paralysed, the patient may experience poor exercise tolerance, orthopnoea and fatigue. Lung function tests will show a restrictive deficit.

### Diaphragmatic herniation

Diaphragmatic hernias are defined as congenital or acquired defects in the diaphragm. There are two main types of congenital diaphragmatic hernias; Bochdalek hernias and Morgagni hernias.

Acquired diaphragmatic hernias include traumatic diaphragmatic rupture, hiatus hernia and iatrogenic diaphragmatic hernias. Depending on the location and size of the defect, retroperitoneal or intra-abdominal organs and tissues can prolapse into the thoracic cavity due to the negative intrathoracic pressure.

Diaphragmatic rupture usually results from blunt abdominal trauma, which is typically associated with motor-vehicle accidents; the most commonly herniated viscera are the stomach and colon on the left side, and the liver on the right side.

In hiatus hernia, the stomach herniates through the oesophageal opening of the diaphragm, typically resulting in symptoms of acid reflux.

< Previous | Next >

Something wrong?

## Question Navigator

1 Answered
2 Answered
3 Answered
4 Answered
5 Answered
6 Answered
7 Answered
8 Answered
9 Answered
10 Answered
11 Answered
12 Answered



©2014 - 2017 FRCEM Success | Website designed & hosted by Cyberfrog Design

# Anatomy: Thorax

Question 117 of 134

## In quiet respiration, the position of the left oblique fissure can be marked by a line on the thoracic wall that:

a Begins between the spinous processes of T3 and T4, crosses the fifth intercostal space laterally and follows the contour of rib 6 anteriorly.

b Begins at the spinous process of T3, crosses the fourth intercostal space laterally and follows the contour of rib 5 anteriorly.

c Begins between the spinous processes of T4 and T5, crosses the fifth intercostal space laterally and follows the contour of rib 5 anteriorly.

d Begins at the spinous process of T4, crosses the fourth intercostal space laterally and follows the contour of rib 5 anteriorly.

e Begins between the spinous processes of T5 and T6, crosses the fifth intercostal space laterally and follows the contour of rib 7 anteriorly.

< Previous | Next > | See Answer

Something wrong?

### Question Navigator

- 1 Answered
- 2 Answered
- 3 Answered
- 4 Answered
- 5 Answered
- 6 Answered
- 7 Answered
- 8 Answered
- 9 Answered
- 10 Answered
- 11 Answered
- 12 Answered



©2014 - 2017 FRCEM Success | Website designed & hosted by Cyberfrog Design

# Anatomy: Thorax

Question 117 of 134

In quiet respiration, the position of the left oblique fissure can be marked by a line on the thoracic wall that:

**a)**
**Begins between the spinous processes of T3 and T4, crosses the fifth intercostal space laterally and follows the contour of rib 6 anteriorly.**

**b)**
Begins at the spinous process of T3, crosses the fourth intercostal space laterally and follows the contour of rib 5 anteriorly.

**c)**
Begins between the spinous processes of T4 and T5, crosses the fifth intercostal space laterally and follows the contour of rib 5 anteriorly.

**d)**
Begins at the spinous process of T4, crosses the fourth intercostal space laterally and follows the contour of rib 5 anteriorly.

**e)**
Begins between the spinous processes of T5 and T6, crosses the fifth intercostal space laterally and follows the contour of rib 7 anteriorly.

## Answer

The oblique fissure in the left lung is slightly more oblique than the corresponding fissure in the right lung. In quiet respiration, the approximate position of the oblique fissure can be marked by a line on the thoracic wall that begins between the spinous processes of vertebrae T3 and T4, crosses the fifth intercostal space laterally and then follows the contour of rib 6 anteriorly.

## Notes

The lungs lie on either side of the mediastinum, each surrounded by a pleural cavity. The right lung is normally a little larger than the left lung because the middle mediastinum, containing the heart, bulges more to the left than to the right.

**Lobes and fissures**

The right lung has three lobes and two fissures; the oblique fissure separates the inferior lobe from the superior and middle lobe whilst the horizontal fissure separates the superior lobe from the middle lobe.

The left lung has two lobes separated by the oblique fissure.

The oblique fissure may be an evolutionary development to permit greater transmission of diaphragmatic excursions to the superior lobe. In this way the upper lobe can expand to a relatively greater extent for a given increase in the superoinferior diameter of the pleural cavity.

**Surface marking**

The inferior margin of the lung in quiet respiration is a line that runs between rib 6 in the midclavicular line, rib 8 in the midaxillary line and vertebra T10 posteriorly.

In quiet respiration, the approximate position of the right oblique fissure can be marked by a line on the thoracic wall that begins at the spinous process of vertebra T4, crosses the fifth intercostal space laterally and then follows the contour of rib 6 anteriorly. The horizontal fissure follows the fourth intercostal space from the sternum until it meets the oblique fissure as it crosses rib 5.

The oblique fissure in the left lung is slightly more oblique than the corresponding fissure in the right lung. In quiet respiration, the approximate position of the oblique fissure can be marked by a line on the thoracic wall that begins between the spinous processes of vertebrae T3 and T4, crosses the fifth intercostal space laterally and then follows the contour of rib 6 anteriorly.

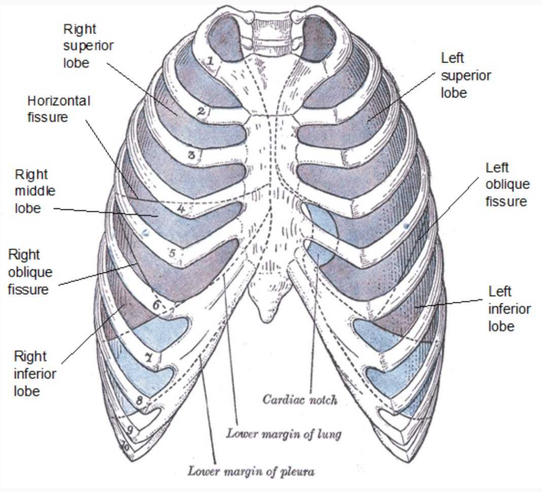


Modified by FRCEM Success. Original by Henry Vandyke Carter [Public domain], via Wikimedia Commons

< Previous | Next >

Something wrong?

## Question Navigator

1 Answered
2 Answered
3 Answered
4 Answered
5 Answered
6 Answered
7 Answered
8 Answered
9 Answered
10 Answered
11 Answered
12 Answered



©2014 - 2017 FRCEM Success | Website designed & hosted by Cyberfrog Design

# Anatomy: Thorax

Question 118 of 134

## Which of the following muscles are primarily involved in passive inspiration:

a Diaphragm and internal intercostal muscles

b External and internal intercostal muscles

c Diaphragm and external intercostal muscles

d Internal and innermost intercostal muscles

e Diaphragm and transversus thoracis

< Previous | Next > | See Answer

Something wrong?

## Question Navigator

1 Answered
2 Answered
3 Answered
4 Answered
5 Answered
6 Answered
7 Answered
8 Answered
9 Answered
10 Answered
11 Answered
12 Answered



©2014 - 2017 FRCEM Success | Website designed & hosted by Cyberfrog Design

# Anatomy: Thorax

Question 118 of 134

Which of the following muscles are primarily involved in passive inspiration:

a) Diaphragm and internal intercostal muscles
b) External and internal intercostal muscles
c) **Diaphragm and external intercostal muscles** ✔
d) Internal and innermost intercostal muscles
e) Diaphragm and transversus thoracis

## Answer

Passive inspiration is produced by contraction of the diaphragm (depressing the diaphragm) and the external intercostal muscles (elevating the ribs).

## Notes

**Thoracic wall movements**

Movement of the ribs at the costovertebral joints in respiration results in the 'pump handle' and 'bucket handle' movements:

- Because the anterior ends of the ribs are inferior to the posterior ends, when the ribs are elevated, the anterior end moves upwards and forwards, moving the sternum upwards and forwards in turn. This 'pump handle' upwards and forwards movement changes the anteroposterior (AP) dimension of the thorax.
- Because the shafts of the ribs are lower than either the anterior or posterior end, elevation of the ribs also moves the shafts laterally. This 'bucket handle' upwards and lateral movement increases the lateral dimensions of the thorax.

Reversal of these movements i.e. depression of the ribs, will reduce the anteroposterior and transverse dimensions of the thorax.

**Inspiration**

In inspiration, elevation of the sternal ends of the ribs ('pump handle' movement), elevation of the lateral shafts of the ribs ('bucket handle' movement) and depression of the diaphragm result in expansion of the thorax in an anteroposterior, transverse and vertical direction respectively. This results in an increased intrathoracic volume and decreased intrathoracic pressure and thus air is drawn into the lungs.

Passive inspiration is produced by contraction of the diaphragm (depressing the diaphragm) and the external intercostal muscles (elevating the ribs).

The accessory respiratory muscles (including the sternocleidomastoid, the scalene muscles and the serratus anterior amongst others) aid in forceful inspiration.

**Expiration**

In expiration, depression of the ribs and elevation of the diaphragm result in a reduction of the thorax in an anteroposterior, transverse and vertical direction. This results in a decreased intrathoracic volume and increased intrathoracic pressure and thus air is forced out of the lungs.

Passive expiration is produced primarily by relaxation of the inspiratory muscles (diaphragm and external intercostal muscles) and the elastic recoil of the lungs.

Forceful expiration is primarily produced by the deeper thoracic muscles (internal and innermost intercostal muscles, subcostals and transversus thoracis) aided by contraction of the abdominal wall muscles which increase intra-abdominal pressure thus further reducing the volume of the thorax.

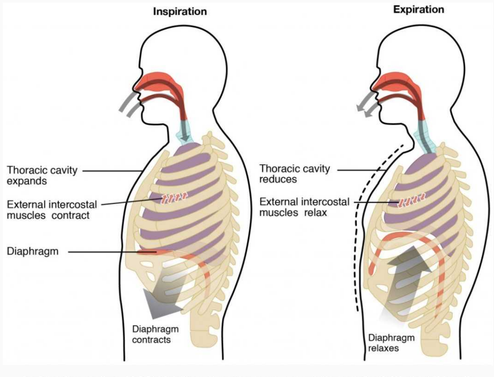


By OpenStax College [CC BY 3.0 (http://creativecommons.org/licenses/by/3.0)], via Wikimedia Commons

**Paradoxical respiration**

Normally as the diaphragm moves downwards in respiration, the abdominal wall moves outwards (together with the chest wall), and the reverse occurs in expiration.

In complete airway obstruction, the diaphragm will move down and the abdominal wall out but as inspiratory effort continues against a closed airway, increasing intrathoracic pressure will draw the chest wall paradoxically inwards (against the opposing action of the intercostal muscles). To the observer, in inspiration there is abdominal expansion with chest collapse and during expiration the reverse is seen. As inspiratory effort increases and expiration becomes active, the see-sawing pattern becomes more pronounced.

Flail chest is a loss of stability of the thoracic cage that occurs when a segment of the anterior or lateral thoracic wall moves freely because of multiple rib fractures, allowing the loose segment to move paradoxically inward on inspiration and outward on expiration. If a large enough segment of the chest is affected, ventilation is impaired.

< Previous | Next >

Something wrong?

## Question Navigator

1 Answered
2 Answered
3 Answered
4 Answered
5 Answered
6 Answered
7 Answered
8 Answered
9 Answered
10 Answered
11 Answered
12 Answered



©2014 - 2017 FRCEM Success | Website designed & hosted by Cyberfrog Design

# Anatomy: Thorax

Question 119 of 134

## A 21 year old horse rider, falls off her horse during a show-jumping condition and fractures her right third rib and structures with which it articulated. Which of the following structures is most likely affected:

a Body of fourth thoracic vertebra

b Body of second thoracic vertebra

c Transverse process of second thoracic vertebra

d Spinous process of third thoracic vertebra

e Manubrium of sternum

< Previous | Next > | See Answer

Something wrong?

## Question Navigator

1 Answered
2 Answered
3 Answered
4 Answered
5 Answered
6 Answered
7 Answered
8 Answered
9 Answered
10 Answered
11 Answered
12 Answered



©2014 - 2017 FRCEM Success | Website designed & hosted by Cyberfrog Design

# Anatomy: Thorax

Question 119 of 134

A 21 year old horse rider, falls off her horse during a show-jumping condition and fractures her right third rib and structures with which it articulated. Which of the following structures is most likely affected:

a) Body of fourth thoracic vertebra
b) **Body of second thoracic vertebra** ✔
c) Transverse process of second thoracic vertebra
d) Spinous process of third thoracic vertebra
e) Manubrium of sternum

## Answer

The third rib articulates anteriorly with the body of the sternum and posteriorly with the bodies of the second and third vertebrae and the transverse process of the third vertebra.

## Notes

There are twelve pairs of ribs, each terminating anteriorly in a costal cartilage.

**True and False ribs**

The ribs are divided into 'true' and 'false' ribs based on their anterior attachments:

- The true ribs (1 – 7) attach directly to the sternum anteriorly.
- The false ribs (8 – 12) can be further divided into those that attach to the costal cartilage of the rib above them (8 – 10) and the floating ribs (11 + 12) that do not have any anterior attachments.

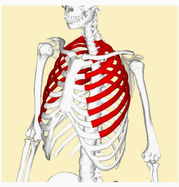

By Anatomography (en:Anatomography (setting page of this image)) [CC BY-SA 2.1 jp (http://creativecommons.org/licenses/by-sa/2.1/jp/deed.en)], via Wikimedia Commons

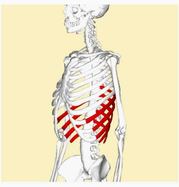

By Anatomography (en:Anatomography (setting page of this image)) [CC BY-SA 2.1 jp (http://creativecommons.org/licenses/by-sa/2.1/jp/deed.en)], via Wikimedia Commons

**Thoracic vertebrae**

Posteriorly, all of the ribs articulate with the thoracic vertebrae of the spine.

Each typical rib forms two joints posteriorly:

- the costotransverse joint (between the tubercle of the rib and the transverse process of the corresponding vertebra)
- the costovertebral joint (between the two facets on the head of the rib and the superior costal facet on the body of the corresponding vertebra, and the inferior costal facet on the body of the vertebra above).

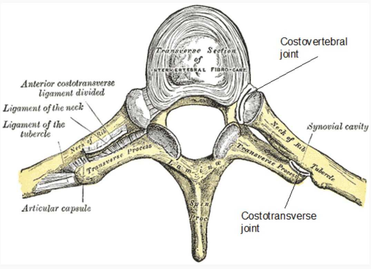


Modified by FRCEM Success. Original by Henry Vandyke Carter [Public domain], via Wikimedia Commons

**Typical ribs**

The typical rib consists of a head, a neck and a body:

- The head of the rib has two articular facets which articulate with the superior costal facet on the body of the corresponding vertebra, and the inferior costal facet on the body of the vertebra above.
- The neck of the rib connects the head to the body. Where the neck meets the body, there is a tubercle which articulates with the transverse process of the corresponding vertebra.
- The body of the rib is flat and curved.

The inferior margin of the internal surface of the body is marked by the costal groove which protects the neurovascular structures which run within it.

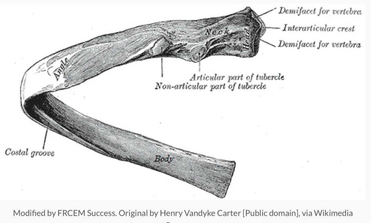


Modified by FRCEM Success. Original by Henry Vandyke Carter [Public domain], via Wikimedia Commons

**Atypical ribs**

The atypical ribs consist of ribs 1, 2, 10, 11 and 12.

| Atypical rib | Features |
|---|---|
| Rib 1 | Shorter and wider, single facet for articulation with T1, scalene tubercle |
| Rib 2 | Flat, roughened area for attachment of serratus anterior muscle |
| Rib 10 | Single facet for articulation with T10 |
| Rib 11 | No neck, single facet for articulation with T11 |
| Rib 12 | No neck, single facet for articulation with T12 |

- Rib 1 is shorter and wider than the other ribs. The head of rib 1 has only one facet for articulation with the body of its own vertebra (T1); it does NOT articulate with vertebra C7. The superior surface of rib 1 is characterised by the scalene tubercle about midway along the body, which separates two smooth grooves in the rib made by the subclavian vein anteriorly and the subclavian artery posteriorly.
- Like rib 1, rib 2 is flat but twice as long. It has a roughened area on its upper surface where the serratus anterior muscle attaches.
- The head of rib 10 only has a single facet for articulation with the body of its own vertebra (T10).
- Ribs 11 and 12 have no neck, and have only one facet for articulation with the bodies of their own vertebrae (T11 and T12).

< Previous | Next >

Something wrong?

## Question Navigator

1 Answered
2 Answered
3 Answered
4 Answered
5 Answered
6 Answered
7 Answered
8 Answered
9 Answered
10 Answered
11 Answered
12 Answered



©2014 - 2017 FRCEM Success | Website designed & hosted by Cyberfrog Design

# Anatomy: Thorax

Question 120 of 134

## Which of the following best describes the territory of supply of the posterior interventricular artery:

a Posterior right atrium and ventricle

b Posterior right and left ventricles and posterior interventricular septum

c Posterior interventricular septum and atrioventricular node

d Posterior left atrium and ventricle

e Posterior right and left atrium

< Previous | Next > | See Answer

Something wrong?

Question Navigator

1 Answered
2 Answered
3 Answered
4 Answered
5 Answered
6 Answered
7 Answered
8 Answered
9 Answered
10 Answered
11 Answered
12 Answered



©2014 - 2017 FRCEM Success | Website designed & hosted by Cyberfrog Design

# Anatomy: Thorax

Question 120 of 134

Which of the following best describes the territory of supply of the posterior interventricular artery:

a) Posterior right atrium and ventricle
b) **Posterior right and left ventricles and posterior interventricular septum** ✔
c) Posterior interventricular septum and atrioventricular node
d) Posterior left atrium and ventricle
e) Posterior right and left atrium

## Answer

The posterior interventricular artery supplies the posterior aspect of the right and left ventricles and the posterior one-third of the interventricular septum.

## Notes

The right and left coronary arteries arise from the right and left aortic sinuses in the initial portion of the ascending aorta and supply the muscle and other tissues of the heart.

| Artery | Territory of supply |
|---|---|
| Right coronary artery | Right atrium and ventricle, sinoatrial node, atrioventricular node |
| Right marginal branch | Inferior aspect of right ventricle |
| Posterior interventricular branch | Posterior aspect of right and left ventricles, posterior one-third of interventricular septum |
| Left coronary artery | Via main branches below |
| Anterior interventricular branch | Right and left ventricles, anterior two-thirds of interventricular septum |
| Left circumflex branch | Left atrium and left ventricle |

**Territories of supply**

Although there is variation, in most people the territories of supply are as follows:

The right coronary artery supplies:

- the right atrium
- most of the right ventricle
- the sinoatrial and atrioventricular nodes
- the interatrial septum
- a portion of the left atrium
- the posteroinferior one-third of the interventricular septum
- a portion of the posterior part of the left ventricle

The left coronary artery supplies:

- most of the left atrium
- most of the left ventricle
- a portion of the right ventricle
- most of the interventricular septum (including the atrioventricular bundle and branches)

**Branches**

The right coronary artery supplies the right atrium, the sinoatrial node and the atrioventricular node (via the SA and AV nodal branches) and gives rise to two principal branches:

- the right marginal branch (supplying the inferior margin of the right ventricle and the apex)
- the posterior interventricular branch (supplying the posterior aspect of the right and left ventricles and the posterior one-third of the interventricular septum).

The left coronary artery gives rise to two principal branches:

- the anterior interventricular branch (supplying the right and left ventricles, the apex and the anterior two-thirds of the interventricular septum)
- the circumflex branch (supplying the left atrium and left ventricle).

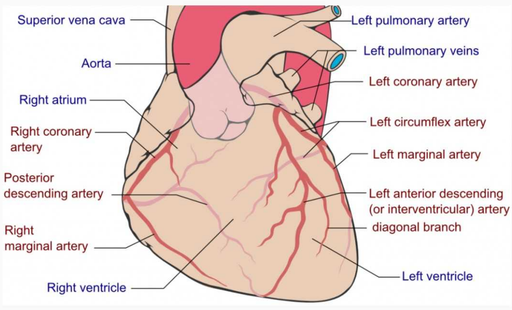


By Coronary.pdf: Patrick J. Lynch, medical illustrator derivative work: Fred the Oyster (talk) adaption and further labeling: Mikael Häggström (Coronary.pdf) [CC BY-SA 3.0 (http://creativecommons.org/licenses/by-sa/3.0)], via Wikimedia Commons

< Previous | Next >

Something wrong?

## Question Navigator

1 Answered
2 Answered
3 Answered
4 Answered
5 Answered
6 Answered
7 Answered
8 Answered
9 Answered
10 Answered
11 Answered
12 Answered



©2014 - 2017 FRCEM Success | Website designed & hosted by Cyberfrog Design

# Anatomy: Thorax

Question 121 of 134

## Which of the following dermatomes is located at the level of the nipples:

a T2

b T3

c T4

d T5

e T6

< Previous | Next > | See Answer

Something wrong?

Question Navigator

1 Answered
2 Answered
3 Answered
4 Answered
5 Answered
6 Answered
7 Answered
8 Answered
9 Answered
10 Answered
11 Answered
12 Answered



©2014 - 2017 FRCEM Success | Website designed & hosted by Cyberfrog Design

# Anatomy: Thorax

Question 121 of 134

Which of the following dermatomes is located at the level of the nipples:

a) T2
b) T3
c) **T4** ✔
d) T5
e) T6

## Answer

The T4 dermatome is located at the level of the nipples.

## Notes

| Dermatome | Landmark |
|---|---|
| T1 | Medial antecubital fossa |
| T2 | Apex of axilla |
| T3 | Third intercostal space |
| T4 | Level of nipples (fourth intercostal space) |
| T5 | Fifth intercostal space |
| T6 | Level of xiphisternum |
| T7 | One-quarter distance between xiphisternum and umbilicus |
| T8 | One-half distance between xiphisternum and umbilicus |
| T9 | Three-quarter distance between xiphisternum and umbilicus |
| T10 | Level of umbilicus |
| T11 | Midway between umbilicus and inguinal ligament |
| T12 | Midpoint of inguinal ligament |

**Dermatome assessment**

- The T1 dermatome is best tested on the medial (ulnar) side of the antecubital fossa, just proximal to the medial epicondyle of the humerus.
- The T2 dermatome is best tested at the apex of the axilla.
- The T3 dermatome is best tested at the midclavicular line and the third intercostal space.
- The T4 dermatome is best tested at the midclavicular line and the fourth intercostal space, located at the level of the nipples.
- The T5 dermatome is best tested at the midclavicular line and the fifth intercostal space, located midway between the level of the nipples and the level of the xiphisternum.
- The T6 dermatome is best tested at the midclavicular line, located at the level of the xiphisternum.
- The T7 dermatome is best tested at the midclavicular line, one quarter the distance between the level of the xiphisternum and the level of the umbilicus.
- The T8 dermatome is best tested at the midclavicular line, one half the distance between the level of the xiphisternum and the level of the umbilicus.
- The T9 dermatome is best tested at the midclavicular line, three quarters of the distance between the level of the xiphisternum and the level of the umbilicus.
- The T10 dermatome is best tested at the midclavicular line, located at the level of the umbilicus.
- The T11 dermatome is best tested at the midclavicular line, midway between the level of the umbilicus and the inguinal ligament.
- The T12 dermatome is best tested at the midclavicular line, over the midpoint of the inguinal ligament.

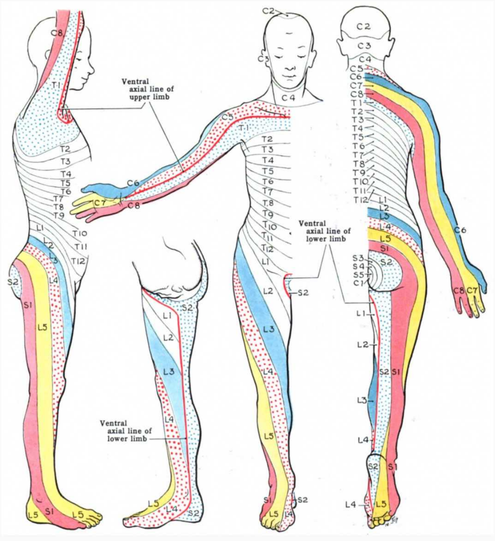


By Grant, John Charles Boileau (An atlas of anatomy, / by regions 1962) [Public domain], via Wikimedia Commons

< Previous | Next >

Something wrong?

## Question Navigator

1 Answered
2 Answered
3 Answered
4 Answered
5 Answered
6 Answered
7 Answered
8 Answered
9 Answered
10 Answered
11 Answered
12 Answered



©2014 - 2017 FRCEM Success | Website designed & hosted by Cyberfrog Design

# Anatomy: Thorax

Question 122 of 134

## The left atrium is primarily supplied by which of the following coronary vessels:

a Right coronary artery

b Right marginal branch

c Posterior interventricular branch

d Anterior interventricular branch

e Left circumflex branch

< Previous | Next > | See Answer

Something wrong?

Question Navigator

1 Answered
2 Answered
3 Answered
4 Answered
5 Answered
6 Answered
7 Answered
8 Answered
9 Answered
10 Answered
11 Answered
12 Answered



©2014 - 2017 FRCEM Success | Website designed & hosted by Cyberfrog Design

# Anatomy: Thorax

Question 122 of 134

The left atrium is primarily supplied by which of the following coronary vessels:

a) Right coronary artery
b) Right marginal branch
c) Posterior interventricular branch
d) Anterior interventricular branch
e) **Left circumflex branch** ✔

## Answer

The left atrium is primarily supplied by the left circumflex branch of the left coronary artery.

## Notes

The right and left coronary arteries arise from the right and left aortic sinuses in the initial portion of the ascending aorta and supply the muscle and other tissues of the heart.

| Artery | Territory of supply |
|---|---|
| Right coronary artery | Right atrium and ventricle, sinoatrial node, atrioventricular node |
| Right marginal branch | Inferior aspect of right ventricle |
| Posterior interventricular branch | Posterior aspect of right and left ventricles, posterior one-third of interventricular septum |
| Left coronary artery | Via main branches below |
| Anterior interventricular branch | Right and left ventricles, anterior two-thirds of interventricular septum |
| Left circumflex branch | Left atrium and left ventricle |

**Territories of supply**

Although there is variation, in most people the territories of supply are as follows:

The right coronary artery supplies:

- the right atrium
- most of the right ventricle
- the sinoatrial and atrioventricular nodes
- the interatrial septum
- a portion of the left atrium
- the posteroinferior one-third of the interventricular septum
- a portion of the posterior part of the left ventricle

The left coronary artery supplies:

- most of the left atrium
- most of the left ventricle
- a portion of the right ventricle
- most of the interventricular septum (including the atrioventricular bundle and branches)

**Branches**

The right coronary artery supplies the right atrium, the sinoatrial node and the atrioventricular node (via the SA and AV nodal branches) and gives rise to two principal branches:

- the right marginal branch (supplying the inferior margin of the right ventricle and the apex)
- the posterior interventricular branch (supplying the posterior aspect of the right and left ventricles and the posterior one-third of the interventricular septum).

The left coronary artery gives rise to two principal branches:

- the anterior interventricular branch (supplying the right and left ventricles, the apex and the anterior two-thirds of the interventricular septum)
- the circumflex branch (supplying the left atrium and left ventricle).

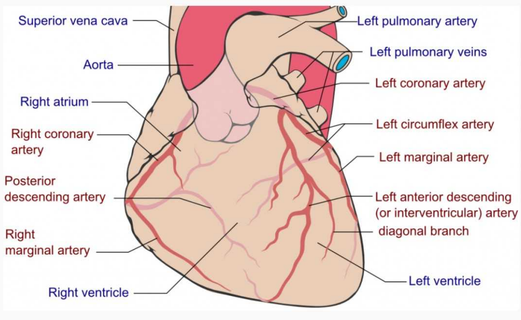


By Coronary.pdf: Patrick J. Lynch, medical illustrator derivative work: Fred the Oyster (talk) adaption and further labeling: Mikael Häggström (Coronary.pdf) [CC BY-SA 3.0 (http://creativecommons.org/licenses/by-sa/3.0)], via Wikimedia Commons

< Previous | Next >

Something wrong?

## Question Navigator

1 Answered
2 Answered
3 Answered
4 Answered
5 Answered
6 Answered
7 Answered
8 Answered
9 Answered
10 Answered
11 Answered
12 Answered



©2014 - 2017 FRCEM Success | Website designed & hosted by Cyberfrog Design

FRCEMSuccess

MENU

# Anatomy: Thorax

Question 123 of 134

## Which of the following is not true of a typical rib:

a The head of the rib has two articular facets

b The tubercle of the rib articulates with the spinous process of the corresponding vertebra

c The inferior margin of the internal surface of the body of the rib is marked by the costal groove

d Posteriorly, the rib articulates with the body of its corresponding vertebra and the vertebra above

e The rib consists of a head, a neck and a body

< Previous | Next > | See Answer

Something wrong?

## Question Navigator

1 Answered
2 Answered
3 Answered
4 Answered
5 Answered
6 Answered
7 Answered
8 Answered
9 Answered
10 Answered
11 Answered
12 Answered



©2014 - 2017 FRCEM Success | Website designed & hosted by Cyberfrog Design

# Anatomy: Thorax

Question 123 of 134

Which of the following is not true of a typical rib:

a) The head of the rib has two articular facets

b) ✔

**The tubercle of the rib articulates with the spinous process of the corresponding vertebra**

c) The inferior margin of the internal surface of the body of the rib is marked by the costal groove

d) Posteriorly, the rib articulates with the body of its corresponding vertebra and the vertebra above

e) The rib consists of a head, a neck and a body

## Answer

Where the neck meets the body of the rib, there is a tubercle which articulates with the transverse process of the corresponding vertebra.

## Notes

There are twelve pairs of ribs, each terminating anteriorly in a costal cartilage.

**True and False ribs**

The ribs are divided into 'true' and 'false' ribs based on their anterior attachments:

- The true ribs (1 – 7) attach directly to the sternum anteriorly.
- The false ribs (8 – 12) can be further divided into those that attach to the costal cartilage of the rib above them (8 – 10) and the floating ribs (11 + 12) that do not have any anterior attachments.

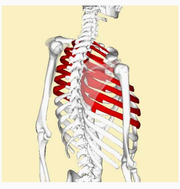

By Anatomography (en:Anatomography (setting page of this image)) [CC BY-SA 2.1 jp (http://creativecommons.org/licenses/by-sa/2.1/jp/deed.en)], via Wikimedia Commons

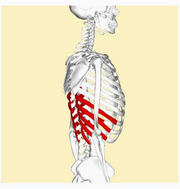

By Anatomography (en:Anatomography (setting page of this image)) [CC BY-SA 2.1 jp (http://creativecommons.org/licenses/by-sa/2.1/jp/deed.en)], via Wikimedia Commons

**Thoracic vertebrae**

Posteriorly, all of the ribs articulate with the thoracic vertebrae of the spine.

Each typical rib forms two joints posteriorly:

- the costotransverse joint (between the tubercle of the rib and the transverse process of the corresponding vertebra)
- the costovertebral joint (between the two facets on the head of the rib and the superior costal facet on the body of the corresponding vertebra, and the inferior costal facet on the body of the vertebra above).

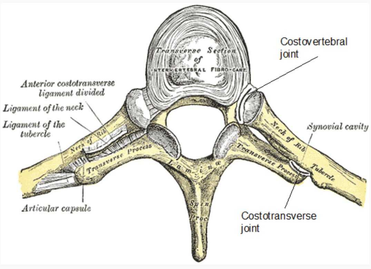


Modified by FRCEM Success. Original by Henry Vandyke Carter [Public domain], via Wikimedia Commons

**Typical ribs**

The typical rib consists of a head, a neck and a body:

- The head of the rib has two articular facets which articulate with the superior costal facet on the body of the corresponding vertebra, and the inferior costal facet on the body of the vertebra above.
- The neck of the rib connects the head to the body. Where the neck meets the body, there is a tubercle which articulates with the transverse process of the corresponding vertebra.
- The body of the rib is flat and curved.

The inferior margin of the internal surface of the body is marked by the costal groove which protects the neurovascular structures which run within it.

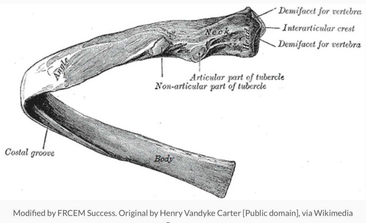


Modified by FRCEM Success. Original by Henry Vandyke Carter [Public domain], via Wikimedia Commons

**Atypical ribs**

The atypical ribs consist of ribs 1, 2, 10, 11 and 12.

| Atypical rib | Features |
|---|---|
| Rib 1 | Shorter and wider, single facet for articulation with T1, scalene tubercle |
| Rib 2 | Flat, roughened area for attachment of serratus anterior muscle |
| Rib 10 | Single facet for articulation with T10 |
| Rib 11 | No neck, single facet for articulation with T11 |
| Rib 12 | No neck, single facet for articulation with T12 |

- Rib 1 is shorter and wider than the other ribs. The head of rib 1 has only one facet for articulation with the body of its own vertebra (T1); it does NOT articulate with vertebra C7. The superior surface of rib 1 is characterised by the scalene tubercle about midway along the body, which separates two smooth grooves in the rib made by the subclavian vein anteriorly and the subclavian artery posteriorly.
- Like rib 1, rib 2 is flat but twice as long. It has a roughened area on its upper surface where the serratus anterior muscle attaches.
- The head of rib 10 only has a single facet for articulation with the body of its own vertebra (T10).
- Ribs 11 and 12 have no neck, and have only one facet for articulation with the bodies of their own vertebrae (T11 and T12).

< Previous | Next >

Something wrong?

## Question Navigator

1 Answered
2 Answered
3 Answered
4 Answered
5 Answered
6 Answered
7 Answered
8 Answered
9 Answered
10 Answered
11 Answered
12 Answered



©2014 - 2017 FRCEM Success | Website designed & hosted by Cyberfrog Design

# Anatomy: Thorax

Question 124 of 134

## Regarding the pleurae, which of the following statements is CORRECT:

a The pleura consists of a fibrous and serous layer.

b The two layers of the pleura are continuous with each other at the hilum of each lung.

c The pleural cavity does not contain any fluid under normal circumstances.

d The visceral pleura is innervated by the phrenic nerve.

e The parietal pleura is only sensitive to stretch.

< Previous | Next > | See Answer

Something wrong?

## Question Navigator

1 Answered
2 Answered
3 Answered
4 Answered
5 Answered
6 Answered
7 Answered
8 Answered
9 Answered
10 Answered
11 Answered
12 Answered



©2014 - 2017 FRCEM Success | Website designed & hosted by Cyberfrog Design

# Anatomy: Thorax

Question 124 of 134

Regarding the pleurae, which of the following statements is CORRECT:

**a)** The pleura consists of a fibrous and serous layer.

**b)** ✔

**The two layers of the pleura are continuous with each other at the hilum of each lung.**

**c)** The pleural cavity does not contain any fluid under normal circumstances.

**d)** The visceral pleura is innervated by the phrenic nerve.

**e)** The parietal pleura is only sensitive to stretch.

## Answer

The pleura consists of the parietal pleura and the visceral pleura. The two parts of the pleura are continuous with each other at the hilum of each lung, and between the pleura is the pleural cavity, which normally contains a small amount (< 50 mL) of serous fluid. The parietal pleura is innervated by the phrenic and the intercostal nerves, and is sensitive to pain.

## Notes

Each lung is surrounded by a pleura. The pleura consists of two parts, the parietal pleura (which lines the thoracic cavity) and the visceral pleura (which lines the lungs). The two parts of the pleura are continuous with each other at the hilum of each lung. The potential space between these two parts of the pleura is called the pleural cavity.

**Pleural cavity**

The pleural cavity normally contains a small amount of lubricating fluid to allow the visceral pleura attached to the lungs to smoothly slide over the parietal pleura attached to the thoracic wall during respiration. The serous fluid also produces a surface tension, pulling the parietal and visceral pleura together. This ensures that when the thorax expands, the lung also expands, filling with air.

**Innervation**

The parietal pleura is innervated by somatic afferent fibres. The costal pleura (pleura related to the ribs and intercostal spaces) is innervated by branches of the intercostal nerves, and pain is felt in relation to the thoracic wall. The diaphragmatic pleura (covering the diaphragm) and the mediastinal pleura (covering the mediastinum) are innervated mainly by the phrenic nerves (C3 – C5), and pain is referred the the C3 – C5 dermatomes (lateral neck and supraclavicular region of shoulder).

Although the visceral pleura is innervated by visceral afferent fibres, pain is not generally elicited from this tissue.

**Surface markings**

Superiorly the pleural cavity projects as much as 3 – 4 cm above the first costal cartilage but does not extend above the neck of rib 1.

Anteriorly the pleurae approach each other posterior to the upper part of the sternum. At the lower part of the sternum the left pleura does not come as close to the midline as the right pleura because the middle mediastinum bulges to the left.

Inferiorly the pleura reflects onto the diaphragm above the costal margin. The inferior margin of the pleural cavity is a line that runs between rib 8 in the midclavicular line, rib 10 in the midaxillary line and vertebra T12 posteriorly.

The inferior margin of the lung in quiet respiration is a line that runs between rib 6 in the midclavicular line, rib 8 in the midaxillary line and vertebra T10 posteriorly.

The lungs therefore do not completely fill the pleural cavities, producing two pleural recesses, the costomediastinal and costodiaphragmatic recesses, in which fluids can collect.

The costomediastinal recess occurs on each side where the the costal pleura is opposed to mediastinal pleura, particularly on the left side in the region overlying the heart.

The costodiaphragmatic recess occurs between the costal and diaphragmatic pleura. It is the region between the inferior margin of the lung and the inferior margin of the pleural cavity and is clinically important for pleural aspiration.

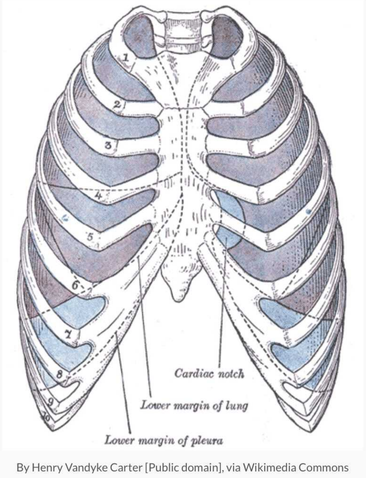


By Henry Vandyke Carter [Public domain], via Wikimedia Commons

< Previous | Next >

Something wrong?

## Question Navigator

1 Answered
2 Answered
3 Answered
4 Answered
5 Answered
6 Answered
7 Answered
8 Answered
9 Answered
10 Answered
11 Answered
12 Answered



©2014 - 2017 FRCEM Success | Website designed & hosted by Cyberfrog Design

# Anatomy: Thorax

Question 125 of 134

## A 19 year old known asthmatic presents to ED with acute severe asthma. Which of the following nerves is responsible for constriction of the bronchial smooth muscle:

a Phrenic nerve

b Vagus nerve

c Intercostal nerves

d Greater thoracic splanchnic nerves

e Lesser thoracic splanchnic nerves

< Previous | Next > | See Answer

Something wrong?

Question Navigator

1 Answered
2 Answered
3 Answered
4 Answered
5 Answered
6 Answered
7 Answered
8 Answered
9 Answered
10 Answered
11 Answered
12 Answered



©2014 - 2017 FRCEM Success | Website designed & hosted by Cyberfrog Design

# Anatomy: Thorax

Question 125 of 134

A 19 year old known asthmatic presents to ED with acute severe asthma. Which of the following nerves is responsible for constriction of the bronchial smooth muscle:

**a)** Phrenic nerve
**b)** **Vagus nerve** ✔
**c)** Intercostal nerves
**d)** Greater thoracic splanchnic nerves
**e)** Lesser thoracic splanchnic nerves

## Answer

The parasympathetic nerve supply, carried by the vagus nerve, stimulates secretion from the bronchial glands, contraction of bronchial smooth muscle, and vasodilation of the pulmonary vessels. The vagus nerve also carries afferent fibres of pain, cough reflex and stretch of the lung (during inspiration).

## Notes

The lungs lie on either side of the mediastinum, each surrounded by a pleural cavity. They are suspended from the mediastinum by the root of the lung, a short tubular collection of structures.

**Lung root**

The root is lined by a layer of mediastinal pleura that reflects onto the surface of the lungs as visceral pleura. The region outlined by this pleural reflection on the medial surface of the lung is the hilum, where structures enter and leave.

The hila are located at the level of the 3rd – 4th costal cartilage anteriorly, and the T5 – T7 vertebrae posteriorly.

Each lung root contains:

- a pulmonary artery
- two pulmonary veins
- a main bronchus
- bronchial vessels,
- nerves and
- lymphatics.

Generally the pulmonary artery is superior in the lung root, the pulmonary veins are inferior and the bronchi are somewhat posterior in position.

In the mediastinum, the vagus nerves pass immediately posteriorly to the lung roots, while the phrenic nerves pass immediately anterior to them.

On the right side, the lobar bronchus to the superior lobe branches from the main bronchus in the root, whereas on the left, it branches within the lung itself.

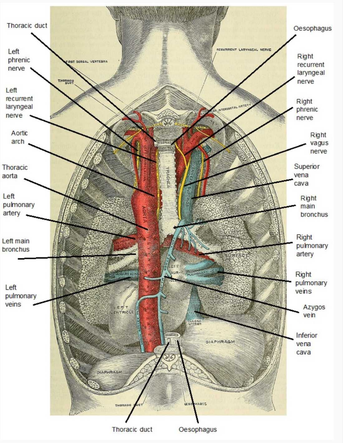


Modified by FRCEM Success. Original by Gray, Henry, 1825-1861; Carter, H. V. (Henry Vandyke), 1831-1897; Pick, T. Pickering (Thomas Pickering), 1841-1919 [No restrictions], via Wikimedia Commons

**Relations**

The medial surface of the right lung lies adjacent to:

- the heart
- the inferior vena cava
- the superior vena cava
- the azygos vein
- the oesophagus

The medial surface of the left lung lies adjacent to:

- the heart
- the aortic arch
- the thoracic aorta
- the oesophagus.

The right and left subclavian arteries and veins arch over and are related to the superior lobe of the right and left lung as they pass over the dome of the cervical pleura and into the axilla.

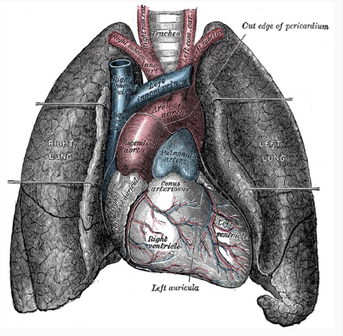


By Henry Vandyke Carter [Public domain], via Wikimedia Commons

**Blood supply**

The right and left pulmonary arteries originate from the pulmonary trunk (at the vertebral level T4/T5) and carry deoxygenated blood to the lungs.

On each side a superior and inferior pulmonary vein carries oxygenated blood from the lungs back to the heart.

The bronchi (down to the terminal bronchioles), lung roots, visceral pleura and supporting lung tissues receive their nutrient blood supply from the bronchial arteries, which arise from the descending aorta.

**Lymphatics**

Lymph from the lungs drains via hilar, tracheobronchial and mediastinal lymph nodes.

**Innervation**

The nerve supply to the lungs is from the anterior and posterior pulmonary plexus (networks of nerves derived from the sympathetic trunk and vagus nerve).

The parasympathetic nerve supply, carried by the vagus nerve, stimulates secretion from the bronchial glands, contraction of bronchial smooth muscle, and vasodilation of the pulmonary vessels. The vagus nerve also carries afferent fibres of pain, cough reflex and stretch of the lung (during inspiration).

The sympathetic nerve supply stimulates relaxation of bronchial smooth muscle, and vasoconstriction of the pulmonary vessels.

< Previous | Next >

Something wrong?

## Question Navigator

1 Answered
2 Answered
3 Answered
4 Answered
5 Answered
6 Answered
7 Answered
8 Answered
9 Answered
10 Answered
11 Answered
12 Answered



©2014 - 2017 FRCEM Success | Website designed & hosted by Cyberfrog Design

# Anatomy: Thorax

Question 126 of 134

A 21 year old woman presents to ED following a road traffic accident. The right side of her chest is hyperresonant with reduced expansion and breath sounds. Her trachea is deviated to the left. You diagnose tension pneumothorax and proceed to perform emergency thoracocentesis. Which of the following is the most appropriate site to insert the needle:

a Second intercostal space midclavicular line

b Third intercostal space midclavicular line

c Fifth intercostal space midaxillary line

d Second intercostal space midaxillary line

e Fifth intercostal space midclavicular line

< Previous | Next > | See Answer

Something wrong?

## Question Navigator

1 Answered
2 Answered
3 Answered
4 Answered
5 Answered
6 Answered
7 Answered
8 Answered
9 Answered
10 Answered
11 Answered
12 Answered



©2014 - 2017 FRCEM Success | Website designed & hosted by Cyberfrog Design

# Anatomy: Thorax

Question 126 of 134

A 21 year old woman presents to ED following a road traffic accident. The right side of her chest is hyperresonant with reduced expansion and breath sounds. Her trachea is deviated to the left. You diagnose tension pneumothorax and proceed to perform emergency thoracocentesis. Which of the following is the most appropriate site to insert the needle:

**a) Second intercostal space midclavicular line** ✔
b) Third intercostal space midclavicular line
c) Fifth intercostal space midaxillary line
d) Second intercostal space midaxillary line
e) Fifth intercostal space midclavicular line

## Answer

The needle should be placed just superior to the third rib, in the second intercostal space, in the midclavicular line on the affected side.

## Notes

The intercostal space lies between adjacent ribs and mostly contains intercostal muscles. Since there are 12 ribs on each side, there are 11 intercostal spaces, each numbered for the rib superior to it.

Intercostal nerves and major associated arteries and veins lie in the costal groove along the inferior margin of the rib, lying in a plane between the internal and innermost intercostal muscles.

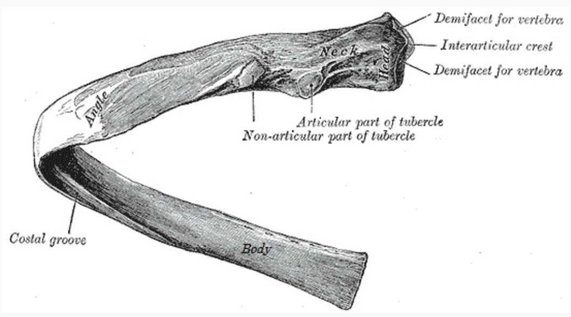


Modified by FRCEM Success. Original by Henry Vandyke Carter [Public domain], via Wikimedia Commons

In each space, the vein is the most superior structure and is therefore highest in the costal groove. The artery is inferior to the vein and the nerve inferior to the artery and often not protected by the groove. Therefore the nerve is the most vulnerable structure in a penetrating injury to the upper aspect of the intercostal space. Small collateral branches of the major intercostal nerves and vessels are often present superior to the inferior rib below.

Any needle or tube (e.g. in needle thoracocentesis, pleural aspiration or chest drain insertion) being inserted in the intercostal space should be placed immediately above the superior margin of a rib to avoid injury to the intercostal neurovascular bundle.

**Needle thoracocentesis**

Needle thoracocentesis is indicated in patients in critical condition with rapid deterioration who have a life-threatening tension pneumothorax where urgent chest drain insertion is not possible.

The needle should be placed just superior to the third rib, in the second intercostal space, in the midclavicular line on the affected side.

Complications of needle thoracocentesis include local haematoma, pneumothorax and lung laceration.

**Chest drain insertion**

Chest drain insertion is the definitive treatment for tension pneumothorax. Chest drain insertion normally occurs at the fifth intercostal space in the midaxillary line on the affected side.

Complications of chest drain insertion include:

- laceration or puncture of intrathoracic or intraabdominal organs
- introduction of pleural infection
- damage to the intercostal nerve (resulting in intercostal neuralgia)
- damage to the intercostal artery or vein (resulting in haemopneumothorax)
- chest drain kinking, clogging or dislodgement or disconnection from underwater seal
- persistent pneumothorax
- subcutaneous emphysema
- recurrence of pneumothorax upon removal of chest drain.

< Previous | Next >

Something wrong?

## Question Navigator

1 Answered
2 Answered
3 Answered
4 Answered
5 Answered
6 Answered
7 Answered
8 Answered
9 Answered
10 Answered
11 Answered
12 Answered



©2014 - 2017 FRCEM Success | Website designed & hosted by Cyberfrog Design

# Anatomy: Thorax

Question 127 of 134

## Which of the following best describes the surface marking of the mitral valve:

a Posterior to the right half of the sternum at the level of the fourth intercostal space

b Posterior to the left half of the sternum at the level of the fourth costal cartilage

c Posterior to the third left chondrosternal joint

d Posterior to the left half of the sternum at the level of the third intercostal space

e Posterior to the right half of the sternum at the level of the third costal cartilage

< Previous | Next > | See Answer

Something wrong?

## Question Navigator

1 Answered
2 Answered
3 Answered
4 Answered
5 Answered
6 Answered
7 Answered
8 Answered
9 Answered
10 Answered
11 Answered
12 Answered



©2014 - 2017 FRCEM Success | Website designed & hosted by Cyberfrog Design

# Anatomy: Thorax

Question 127 of 134

Which of the following best describes the surface marking of the mitral valve:

a) Posterior to the right half of the sternum at the level of the fourth intercostal space
b) **Posterior to the left half of the sternum at the level of the fourth costal cartilage** ✔
c) Posterior to the third left chondrosternal joint
d) Posterior to the left half of the sternum at the level of the third intercostal space
e) Posterior to the right half of the sternum at the level of the third costal cartilage

## Answer

The mitral valve is located posterior to the left half of the sternum at the level of the fourth costal cartilage.

## Notes

| Heart valve | Surface marking | Auscultation position |
|---|---|---|
| Tricuspid valve | Posterior to right half of sternum at level of 4th ICS | Left of sternum near 5th ICS |
| Mitral valve | Posterior to left half of sternum at level of 4th costal cartilage | Left 5th ICS in midclavicular line |
| Pulmonary valve | Posterior to third left chondrosternal joint | Medial end of left 2nd ICS |
| Aortic valve | Posterior to left half of sternum at level of 3rd ICS | Medial end of right 2nd ICS |

**Surface marking of heart valves**

- The tricuspid valve is located posterior to the right half of the sternum at the level of the fourth intercostal space.
- The mitral valve is located posterior to the left half of the sternum at the level of the fourth costal cartilage.
- The pulmonary valve is located posterior to the third left chondrosternal joint.
- The aortic valve is located posterior to the left half of the sternum at the level of the third intercostal space.

**Auscultation positions of heart valves**

Heart valves should be auscultated by positioning the stethoscope downstream from the flow of blood through the valves.

- The tricuspid valve is heard just to the left of the lower part of the sternum near the fifth intercostal space.
- The mitral valve is heard over the apex of the heart in the left fifth intercostal space at the midclavicular line.
- The pulmonary valve is heard over the medial end of the left second intercostal space.
- The aortic valve is heard over the medial end of the right second intercostal space.

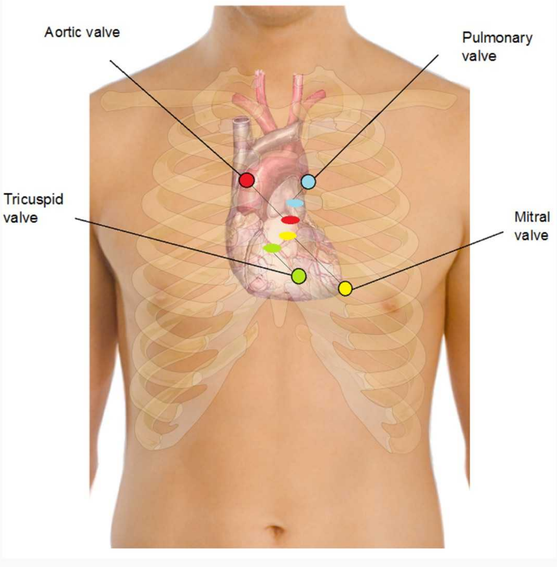


Modified by FRCEM Success. Original by Mikael Häggström [Public domain], via Wikimedia Commons

< Previous | Next >

Something wrong?

## Question Navigator

1 Answered
2 Answered
3 Answered
4 Answered
5 Answered
6 Answered
7 Answered
8 Answered
9 Answered
10 Answered
11 Answered
12 Answered



©2014 - 2017 FRCEM Success | Website designed & hosted by Cyberfrog Design

# Anatomy: Thorax

Question 128 of 134

## The central tendon of the diaphragm is attached superiorly to:

a The manubrium of the sternum

b The fibrous pericardium

c Ribs 11 and 12

d The arcuate ligaments

e The body of the sternum

< Previous | Next > | See Answer

Something wrong?

Question Navigator

1 Answered
2 Answered
3 Answered
4 Answered
5 Answered
6 Answered
7 Answered
8 Answered
9 Answered
10 Answered
11 Answered
12 Answered



©2014 - 2017 FRCEM Success | Website designed & hosted by Cyberfrog Design

# Anatomy: Thorax

Question 128 of 134

The central tendon of the diaphragm is attached superiorly to:

**a)** The manubrium of the sternum
**b)** **The fibrous pericardium** ✔
**c)** Ribs 11 and 12
**d)** The arcuate ligaments
**e)** The body of the sternum

## Answer

The central tendon arises from the convergence of peripheral muscle fibres and fuses superiorly with the fibrous pericardium.

## Notes

The diaphragm is a musculotendinous structure that separates the thoracic cavity from the abdominal cavity.

| Structure | Diaphragm |
|---|---|
| Primary function | Respiration – contraction of diaphragm flattens diaphragm increasing vertical dimension of thorax (inspiration), relaxation of diaphragm elevates diaphragm decreasing vertical dimension of thorax (expiration) |
| Secondary functions | Assists in straining movements by increasing intra-abdominal pressure, acts as functional sphincter on oesophagus preventing acid reflux |
| Peripheral attachments | Xiphoid process of sternum, costal cartilages ribs 7 – 10, ends of ribs 11 and 12, arcuate ligaments and lumbar vertebrae |
| Central attachment | Fuses with fibrous pericardium superiorly |
| Surface markings | Attachments: vertebrae T8/T9 anteriorly, vertebra T12 posteriorly, Domes: right dome 5th rib, left dome 5th intercostal space |
| Openings | Oesophageal opening at T10 (oesophagus, vagus nerve), aortic opening at T12 (aorta, thoracic duct and azygos vein), caval opening at T8 (inferior vena cava and right phrenic nerve) |
| Innervation | Phrenic nerve (C3 – C5) |

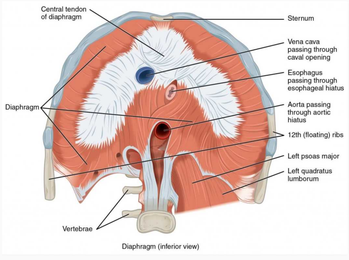


By OpenStax [CC BY 4.0 (http://creativecommons.org/licenses/by/4.0)], via Wikimedia Commons

### Function

The diaphragm performs an important function in respiration; contraction of the domes of the diaphragm in inspiration flattens the diaphragm, increasing the vertical dimension of the thorax and vice versa in expiration, with relaxation and elevation of the diaphragm reducing the vertical dimension of the thorax.

The diaphragm is also involved in non-respiratory functions; helping to expel vomit, faeces, and urine from the body by increasing intraabdominal pressure, and preventing acid reflux by exerting pressure on the oesophagus as it passes through the oesophageal opening.

### Attachments

The diaphragm is attached peripherally to:

- the xiphoid process of the sternum and the costal cartilages of ribs 7 – 10 (the costal margin) anteriorly
- the ends of ribs 11 and 12 laterally
- the arcuate ligaments and vertebrae posteriorly.

From these peripheral attachments, muscle fibres converge to form the central tendon which fuses with the fibrous pericardium superiorly.

### Surface markings

In the medial sagittal plane, the diaphragm slopes inferiorly from its anterior attachment to the xiphoid at approximately vertebral level T8/T9 to its posterior attachment to the median arcuate ligament at approximately vertebral level T12.

At rest the right dome of the diaphragm lies slightly higher than the left; this is thought to be due to the position of the liver. In normal expiration, the normal upper limits of the superior margins are the fifth rib for the right dome, the fifth intercostal space for the left dome and the xiphoid process for the central tendon.

### Diaphragmatic openings

Structures travelling between the thorax and abdomen must pass through the diaphragm via three main openings.

The oesophageal opening at vertebral level T10 transmits:

- the oesophagus
- the anterior and posterior vagal trunks
- oesophageal branches of the left gastric vessels
- a few lymphatics.

The aortic opening at vertebral level T12 transmits:

- the aorta
- the thoracic duct
- the azygos vein and sometimes the hemiazygos vein.

The caval opening at vertebral level T8 transmits:

- the inferior vena cava
- the right phrenic nerve.

### Innervation

The entire motor supply of the diaphragm is from the right and left phrenic nerves (C3 – C5) which penetrate the diaphragm and innervate it from its abdominal surface.

Damage to the phrenic nerve will result in hemiparalysis of the diaphragm. Paralysis of the diaphragm produces a paradoxical movement. The affected side of the diaphragm moves upwards during inspiration (as it is pushed superiorly by the abdominal viscera that are being actively compressed by the other half), and downwards during expiration.

A unilateral diaphragmatic paralysis is usually asymptomatic, and is most often an incidental finding on x-ray. If both sides are paralysed, the patient may experience poor exercise tolerance, orthopnoea and fatigue. Lung function tests will show a restrictive deficit.

### Diaphragmatic herniation

Diaphragmatic hernias are defined as congenital or acquired defects in the diaphragm. There are two main types of congenital diaphragmatic hernias; Bochdalek hernias and Morgagni hernias.

Acquired diaphragmatic hernias include traumatic diaphragmatic rupture, hiatus hernia and iatrogenic diaphragmatic hernias. Depending on the location and size of the defect, retroperitoneal or intra-abdominal organs and tissues can prolapse into the thoracic cavity due to the negative intrathoracic pressure.

Diaphragmatic rupture usually results from blunt abdominal trauma, which is typically associated with motor-vehicle accidents; the most commonly herniated viscera are the stomach and colon on the left side, and the liver on the right side.

In hiatus hernia, the stomach herniates through the oesophageal opening of the diaphragm, typically resulting in symptoms of acid reflux.

< Previous | Next > | Something wrong?

## Question Navigator

1 Answered
2 Answered
3 Answered
4 Answered
5 Answered
6 Answered
7 Answered
8 Answered
9 Answered
10 Answered
11 Answered
12 Answered



©2014 - 2017 FRCEM Success | Website designed & hosted by Cyberfrog Design

# Anatomy: Thorax

Question 129 of 134

## Regarding the lung roots, which of the following statements is CORRECT:

a The vagus nerves pass immediately anterior to the lung roots.

b The phrenic nerves pass immediately posterior to the lung roots.

c Each lung root contains two pulmonary arteries and a pulmonary vein.

d Generally the bronchi lie anterior to the vessels in the lung root.

e Generally the pulmonary arteries lie superior to the pulmonary veins in the lung root.

< Previous | Next > | See Answer

Something wrong?

### Question Navigator

1 Answered
2 Answered
3 Answered
4 Answered
5 Answered
6 Answered
7 Answered
8 Answered
9 Answered
10 Answered
11 Answered
12 Answered



©2014 - 2017 FRCEM Success | Website designed & hosted by Cyberfrog Design

# Anatomy: Thorax

Question 129 of 134

Regarding the lung roots, which of the following statements is CORRECT:

**a)** The vagus nerves pass immediately anterior to the lung roots.
**b)** The phrenic nerves pass immediately posterior to the lung roots.
**c)** Each lung root contains two pulmonary arteries and a pulmonary vein.
**d)** Generally the bronchi lie anterior to the vessels in the lung root.
**e)**
**Generally the pulmonary arteries lie superior to the pulmonary veins in the lung root.**

## Answer

Each lung root contains a pulmonary artery, two pulmonary veins, a main bronchus, bronchial vessels, nerves and lymphatics. Generally the pulmonary artery is superior in the lung root, the pulmonary veins are inferior and the bronchi are somewhat posterior in position. The vagus nerves pass posterior to the lung roots while the phrenic nerves pass anterior to them.

## Notes

The lungs lie on either side of the mediastinum, each surrounded by a pleural cavity. They are suspended from the mediastinum by the root of the lung, a short tubular collection of structures.

**Lung root**

The root is lined by a layer of mediastinal pleura that reflects onto the surface of the lungs as visceral pleura. The region outlined by this pleural reflection on the medial surface of the lung is the hilum, where structures enter and leave.

The hila are located at the level of the 3rd – 4th costal cartilage anteriorly, and the T5 – T7 vertebrae posteriorly.

Each lung root contains:

- a pulmonary artery
- two pulmonary veins
- a main bronchus
- bronchial vessels,
- nerves and
- lymphatics.

Generally the pulmonary artery is superior in the lung root, the pulmonary veins are inferior and the bronchi are somewhat posterior in position.

In the mediastinum, the vagus nerves pass immediately posteriorly to the lung roots, while the phrenic nerves pass immediately anterior to them.

On the right side, the lobar bronchus to the superior lobe branches from the main bronchus in the root, whereas on the left, it branches within the lung itself.

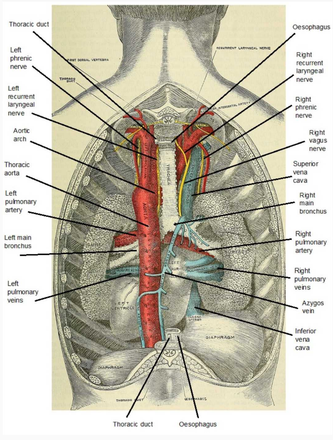


Modified by FRCEM Success. Original by Gray, Henry, 1825-1861; Carter, H. V. (Henry Vandyke), 1831-1897; Pick, T. Pickering (Thomas Pickering), 1841-1919 [No restrictions], via Wikimedia Commons

**Relations**

The medial surface of the right lung lies adjacent to:

- the heart
- the inferior vena cava
- the superior vena cava
- the azygos vein
- the oesophagus

The medial surface of the left lung lies adjacent to:

- the heart
- the aortic arch
- the thoracic aorta
- the oesophagus.

The right and left subclavian arteries and veins arch over and are related to the superior lobe of the right and left lung as they pass over the dome of the cervical pleura and into the axilla.

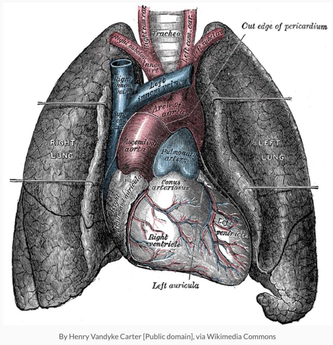


By Henry Vandyke Carter [Public domain], via Wikimedia Commons

**Blood supply**

The right and left pulmonary arteries originate from the pulmonary trunk (at the vertebral level T4/T5) and carry deoxygenated blood to the lungs.

On each side a superior and inferior pulmonary vein carries oxygenated blood from the lungs back to the heart.

The bronchi (down to the terminal bronchioles), lung roots, visceral pleura and supporting lung tissues receive their nutrient blood supply from the bronchial arteries, which arise from the descending aorta.

**Lymphatics**

Lymph from the lungs drains via hilar, tracheobronchial and mediastinal lymph nodes.

**Innervation**

The nerve supply to the lungs is from the anterior and posterior pulmonary plexus (networks of nerves derived from the sympathetic trunk and vagus nerve).

The parasympathetic nerve supply, carried by the vagus nerve, stimulates secretion from the bronchial glands, contraction of bronchial smooth muscle, and vasodilation of the pulmonary vessels. The vagus nerve also carries afferent fibres of pain, cough reflex and stretch of the lung (during inspiration).

The sympathetic nerve supply stimulates relaxation of bronchial smooth muscle, and vasoconstriction of the pulmonary vessels.

< Previous | Next >

Something wrong?

## Question Navigator

1 Answered
2 Answered
3 Answered
4 Answered
5 Answered
6 Answered
7 Answered
8 Answered
9 Answered
10 Answered
11 Answered
12 Answered



©2014 - 2017 FRCEM Success | Website designed & hosted by Cyberfrog Design

# Anatomy: Thorax

Question 130 of 134

## A 21 year old patient presents to ED with a primary spontaneous pneumothorax. You are asked by your consultant to perform a pleural aspiration. When inserting the needle, it should be placed:

a Immediately above the margin of a rib

b Immediately below the margin of a rib

c Between the external and internal intercostal muscles

d Between the internal and innermost intercostal muscles

e In the middle of the intercostal space

< Previous | Next > | See Answer

Something wrong?

Question Navigator

1 Answered
2 Answered
3 Answered
4 Answered
5 Answered
6 Answered
7 Answered
8 Answered
9 Answered
10 Answered
11 Answered
12 Answered



©2014 - 2017 FRCEM Success | Website designed & hosted by Cyberfrog Design

# Anatomy: Thorax

Question 130 of 134

A 21 year old patient presents to ED with a primary spontaneous pneumothorax. You are asked by your consultant to perform a pleural aspiration. When inserting the needle, it should be placed:

**a)** **Immediately above the margin of a rib** ✔
**b)** Immediately below the margin of a rib
**c)** Between the external and internal intercostal muscles
**d)** Between the internal and innermost intercostal muscles
**e)** In the middle of the intercostal space

## Answer

The needle should be inserted just superior to the upper border of a rib to avoid damaging the neurovascular bundle which runs in the costal groove along the inferior margin of the rib.

## Notes

The intercostal space lies between adjacent ribs and mostly contains intercostal muscles. Since there are 12 ribs on each side, there are 11 intercostal spaces, each numbered for the rib superior to it.

Intercostal nerves and major associated arteries and veins lie in the costal groove along the inferior margin of the rib, lying in a plane between the internal and innermost intercostal muscles.

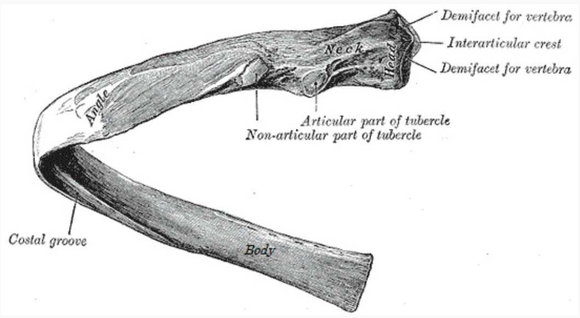


Modified by FRCEM Success. Original by Henry Vandyke Carter [Public domain], via Wikimedia Commons

In each space, the vein is the most superior structure and is therefore highest in the costal groove. The artery is inferior to the vein and the nerve inferior to the artery and often not protected by the groove. Therefore the nerve is the most vulnerable structure in a penetrating injury to the upper aspect of the intercostal space. Small collateral branches of the major intercostal nerves and vessels are often present superior to the inferior rib below.

Any needle or tube (e.g. in needle thoracocentesis, pleural aspiration or chest drain insertion) being inserted in the intercostal space should be placed immediately above the superior margin of a rib to avoid injury to the intercostal neurovascular bundle.

**Needle thoracocentesis**

Needle thoracocentesis is indicated in patients in critical condition with rapid deterioration who have a life-threatening tension pneumothorax where urgent chest drain insertion is not possible.

The needle should be placed just superior to the third rib, in the second intercostal space, in the midclavicular line on the affected side.

Complications of needle thoracocentesis include local haematoma, pneumothorax and lung laceration.

**Chest drain insertion**

Chest drain insertion is the definitive treatment for tension pneumothorax. Chest drain insertion normally occurs at the fifth intercostal space in the midaxillary line on the affected side.

Complications of chest drain insertion include:

- laceration or puncture of intrathoracic or intraabdominal organs
- introduction of pleural infection
- damage to the intercostal nerve (resulting in intercostal neuralgia)
- damage to the intercostal artery or vein (resulting in haemopneumothorax)
- chest drain kinking, clogging or dislodgement or disconnection from underwater seal
- persistent pneumothorax
- subcutaneous emphysema
- recurrence of pneumothorax upon removal of chest drain.

< Previous | Next >

Something wrong?

## Question Navigator

1 Answered
2 Answered
3 Answered
4 Answered
5 Answered
6 Answered
7 Answered
8 Answered
9 Answered
10 Answered
11 Answered
12 Answered



©2014 - 2017 FRCEM Success | Website designed & hosted by Cyberfrog Design

# Anatomy: Thorax

Question 131 of 134

## In quiet respiration anteriorly the horizontal fissure lies at the level of which of the following:

a The third intercostal space

b The fifth rib

c The fourth intercostal space

d The sixth rib

e The fifth intercostal space

< Previous | Next > | See Answer

Something wrong?

## Question Navigator

1 Answered
2 Answered
3 Answered
4 Answered
5 Answered
6 Answered
7 Answered
8 Answered
9 Answered
10 Answered
11 Answered
12 Answered



©2014 - 2017 FRCEM Success | Website designed & hosted by Cyberfrog Design

# Anatomy: Thorax

Question 131 of 134

In quiet respiration anteriorly the horizontal fissure lies at the level of which of the following:

a) The third intercostal space
b) The fifth rib
c) The fourth intercostal space ✔
d) The sixth rib
e) **The fifth intercostal space** ✖

## Answer

The horizontal fissure follows the fourth intercostal space from the sternum until it meets the oblique fissure as it crosses rib 5.

## Notes

The lungs lie on either side of the mediastinum, each surrounded by a pleural cavity. The right lung is normally a little larger than the left lung because the middle mediastinum, containing the heart, bulges more to the left than to the right.

Lobes and fissures

The right lung has three lobes and two fissures; the oblique fissure separates the inferior lobe from the superior and middle lobe whilst the horizontal fissure separates the superior lobe from the middle lobe.

The left lung has two lobes separated by the oblique fissure.

The oblique fissure may be an evolutionary development to permit greater transmission of diaphragmatic excursions to the superior lobe. In this way the upper lobe can expand to a relatively greater extent for a given increase in the superoinferior diameter of the pleural cavity.

Surface marking

The inferior margin of the lung in quiet respiration is a line that runs between rib 6 in the midclavicular line, rib 8 in the midaxillary line and vertebra T10 posteriorly.

In quiet respiration, the approximate position of the right oblique fissure can be marked by a line on the thoracic wall that begins at the spinous process of vertebra T4, crosses the fifth intercostal space laterally and then follows the contour of rib 6 anteriorly. The horizontal fissure follows the fourth intercostal space from the sternum until it meets the oblique fissure as it crosses rib 5.

The oblique fissure in the left lung is slightly more oblique than the corresponding fissure in the right lung. In quiet respiration, the approximate position of the oblique fissure can be marked by a line on the thoracic wall that begins between the spinous processes of vertebrae T3 and T4, crosses the fifth intercostal space laterally and then follows the contour of rib 6 anteriorly.

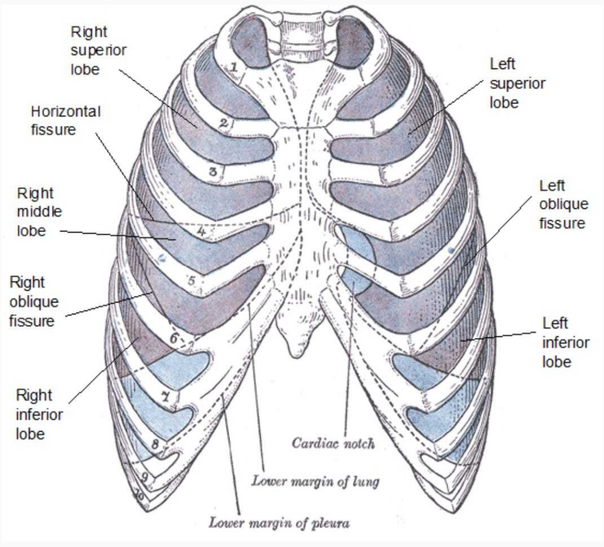


Modified by FRCEM Success. Original by Henry Vandyke Carter [Public domain], via Wikimedia Commons

## Question Navigator

1 Answered
2 Answered
3 Answered
4 Answered
5 Answered
6 Answered
7 Answered
8 Answered
9 Answered
10 Answered
11 Answered
12 Answered

< Previous | Next > | Something wrong?



©2014 - 2017 FRCEM Success | Website designed & hosted by Cyberfrog Design

# Anatomy: Thorax

Question 132 of 134

A 19 year old woman is brought to the ED having been stabbed in the chest. She has sustained a penetrating wound in the left fourth intercostal space, just lateral to the sternal border. Which of the following thoracic structures is most likely to have been injured:

a Left atrium

b Left ventricle

c Right atrium

d Right ventricle

e Apex

< Previous | Next > | See Answer

Something wrong?

## Question Navigator

1 Answered
2 Answered
3 Answered
4 Answered
5 Answered
6 Answered
7 Answered
8 Answered
9 Answered
10 Answered
11 Answered
12 Answered



©2014 - 2017 FRCEM Success | Website designed & hosted by Cyberfrog Design

# Anatomy: Thorax

Question 132 of 134

A 19 year old woman is brought to the ED having been stabbed in the chest. She has sustained a penetrating wound in the left fourth intercostal space, just lateral to the sternal border. Which of the following thoracic structures is most likely to have been injured:

**a)** Left atrium
**b)** Left ventricle
**c)** Right atrium
**d)** **Right ventricle** ✔
**e)** Apex

## Answer

The right ventricle forms most of the anterior surface of the heart. The left atrium forms the posterior surface of the heart (the only portion of the left atrium seen on the anterior surface of the heart is the left auricle). The left ventricle forms most of the left border and the diaphragmatic surface of the heart. The right atrium forms the right border of the heart.

## Notes

| Border/Surface | Main structure (contributing structures) |
|---|---|
| Apex | Left ventricle |
| Base | Left atrium (right atrium, proximal great veins) |
| Anterior surface | Right ventricle (right atrium, left ventricle) |
| Inferior surface | Left and right ventricle |
| Left pulmonary surface | Left ventricle (left atrium) |
| Right pulmonary surface | Right atrium |
| Inferior border | Right ventricle (left ventricle) |
| Left border | Left ventricle (left auricle) |
| Right border | Right atrium |
| Superior border | Both atria, roots of great vessels |

The general shape and orientation of the heart are that of a pyramid that has fallen over and is resting on one of its sides.

- The apex of this pyramid projects forwards, downwards and to the left. The apex is formed by the inferolateral part of the left ventricle and is positioned deep to the left fifth intercostal space in the midclavicular line.
- The base is facing posteriorly. The base is formed mostly by the left atrium with a small portion of the right atrium and the proximal part of the great veins, and is fixed posteriorly to the pericardial wall, opposite the bodies of the T5 – T8 vertebrae (T6 – T9 when standing). The oesophagus lies immediately posterior to the base.

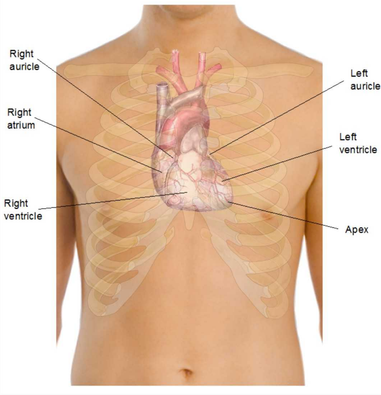


Modified by FRCEM Success. Original by Mikael Häggström (See above. All used images are in public domain.) [Public domain], via Wikimedia Commons

Surfaces

There are four surfaces to the upturned pyramid:

- The anterior (sternocostal) surface consists mostly of the right ventricle with some of the right atrium and some of the left ventricle.
- The inferior (diaphragmatic) surface consists of the left ventricle with a small portion of the right ventricle separated by the posterior interventricular groove.
- The left pulmonary surface consists mainly of the left ventricle and a portion of the left atrium.
- The right pulmonary surface consists of the right atrium.

Borders

There are four main borders separating the surfaces of the heart:

- The inferior border is formed mostly by the right ventricle and a small portion of the left ventricle near the apex.
- The left border is formed mostly by the left ventricle with a small portion of the left auricle.
- The right border is formed by the right atrium.
- The superior border is formed by both atria and the roots of the great vessels.

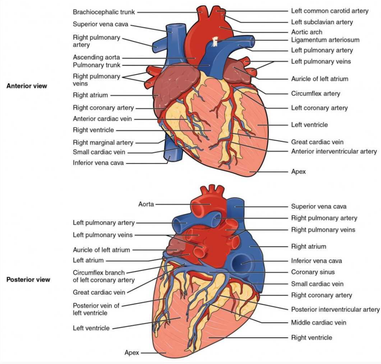


By OpenStax College [CC BY 3.0 (http://creativecommons.org/licenses/by/3.0)], via Wikimedia Commons

< Previous | Next >

Something wrong?

## Question Navigator

1 Answered
2 Answered
3 Answered
4 Answered
5 Answered
6 Answered
7 Answered
8 Answered
9 Answered
10 Answered
11 Answered
12 Answered



©2014 - 2017 FRCEM Success | Website designed & hosted by Cyberfrog Design

# Anatomy: Thorax

Question 133 of 134

## Which of the following best describes the territory of supply of the right marginal artery:

a Right ventricle and atrioventricular node

b Right atrium and sinoatrial node

c Right atrium and ventricle

d Inferior aspect of right ventricle

e Right and left atrium

< Previous | Next > | See Answer

Something wrong?

## Question Navigator

1 Answered
2 Answered
3 Answered
4 Answered
5 Answered
6 Answered
7 Answered
8 Answered
9 Answered
10 Answered
11 Answered
12 Answered



©2014 - 2017 FRCEM Success | Website designed & hosted by Cyberfrog Design

# Anatomy: Thorax

Question 133 of 134

Which of the following best describes the territory of supply of the right marginal artery:

**a)** Right ventricle and atrioventricular node
**b)** Right atrium and sinoatrial node
**c)** Right atrium and ventricle
**d)** **Inferior aspect of right ventricle** ✔
**e)** Right and left atrium

## Answer

The right marginal artery supplies the inferior margin of the right ventricle.

## Notes

The right and left coronary arteries arise from the right and left aortic sinuses in the initial portion of the ascending aorta and supply the muscle and other tissues of the heart.

| Artery | Territory of supply |
|---|---|
| Right coronary artery | Right atrium and ventricle, sinoatrial node, atrioventricular node |
| Right marginal branch | Inferior aspect of right ventricle |
| Posterior interventricular branch | Posterior aspect of right and left ventricles, posterior one-third of interventricular septum |
| Left coronary artery | Via main branches below |
| Anterior interventricular branch | Right and left ventricles, anterior two-thirds of interventricular septum |
| Left circumflex branch | Left atrium and left ventricle |

**Territories of supply**

Although there is variation, in most people the territories of supply are as follows:

The right coronary artery supplies:

- the right atrium
- most of the right ventricle
- the sinoatrial and atrioventricular nodes
- the interatrial septum
- a portion of the left atrium
- the posteroinferior one-third of the interventricular septum
- a portion of the posterior part of the left ventricle

The left coronary artery supplies:

- most of the left atrium
- most of the left ventricle
- a portion of the right ventricle
- most of the interventricular septum (including the atrioventricular bundle and branches)

**Branches**

The right coronary artery supplies the right atrium, the sinoatrial node and the atrioventricular node (via the SA and AV nodal branches) and gives rise to two principal branches:

- the right marginal branch (supplying the inferior margin of the right ventricle and the apex)
- the posterior interventricular branch (supplying the posterior aspect of the right and left ventricles and the posterior one-third of the interventricular septum).

The left coronary artery gives rise to two principal branches:

- the anterior interventricular branch (supplying the right and left ventricles, the apex and the anterior two-thirds of the interventricular septum)
- the circumflex branch (supplying the left atrium and left ventricle).

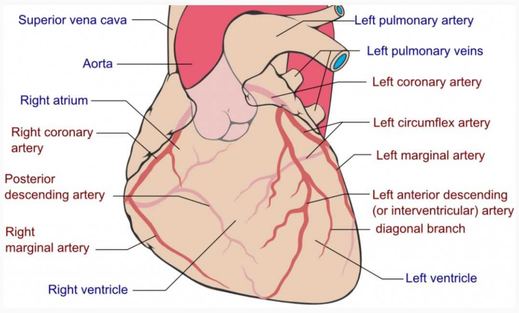


By Coronary.pdf: Patrick J. Lynch, medical illustrator derivative work: Fred the Oyster (talk) adaption and further labeling: Mikael Häggström (Coronary.pdf) [CC BY-SA 3.0 (http://creativecommons.org/licenses/by-sa/3.0)], via Wikimedia Commons

< Previous | Next > | Something wrong?

## Question Navigator

1 Answered
2 Answered
3 Answered
4 Answered
5 Answered
6 Answered
7 Answered
8 Answered
9 Answered
10 Answered
11 Answered
12 Answered



©2014 - 2017 FRCEM Success | Website designed & hosted by Cyberfrog Design

# Anatomy: Thorax

Question 134 of 134

## Regarding the intercostal space, which of the following statements is CORRECT:

a The neurovascular bundle lies in the costal groove along the superior margin of the rib.

b The neurovascular bundle lies between the external and internal intercostal muscles.

c Within the neurovascular bundle, the artery lies superior to the intercostal nerve.

d The intercostal vein is the structure most vulnerable to damage in the neurovascular bundle.

e There are 12 intercostal spaces, each numbered for the rib superior to it.

< Previous | See Answer | Submit | Something wrong?

## Question Navigator

1 Answered
2 Answered
3 Answered
4 Answered
5 Answered
6 Answered
7 Answered
8 Answered
9 Answered
10 Answered
11 Answered
12 Answered



©2014 - 2017 FRCEM Success | Website designed & hosted by Cyberfrog Design

# You have scored 83%

## You answered 111 correct out of 134 questions.

**Your answers are shown below:**

- A 5 year old girl is brought in having inhaled a small plastic object. Where in the tracheobronchial tree is the object most likely to lodge:
- Which of the following best describes the surface marking of the tricuspid valve:
- A 29 year old male presents to ED having sustained a penetrating injury to the neck. On further exploration, it is found that he has transected the left phrenic nerve. Which of the following clinical features would you most expect to see:
- A 54 year old man presents to ED with central crushing chest pain. Later coronary angiograms show thrombosis in the circumflex branch of the left coronary artery. Which of the following conditions is most likely to result from obstruction to flow:
- Which of the following structures lies immediately posterior to the base of the heart:
- The inferior margin of the lung in quiet respiration is a line that runs anterolaterally between which of the following surface landmarks:
- A 54 year old man complains of tingling and a blistering rash that has erupted over his left back and left chest at the level of the nipple. You diagnose shingles. Which of the following spinal nerve roots is most likely affected:
- The 'pump handle' movement of the thoracic wall results from which of the following movements:
- A 21 year old man is brought to ED having been involved in a road traffic accident. He is hypotensive with muffled heart sounds and distended neck veins. Your consultant suspects cardiac tamponade and proceeds to perform emergency pericardiocentesis. Which of the following sites is the needle best placed to relieve the tamponade:
- The hila of the lungs are located at the level of which of the following costal cartilages:
- The anterior surface of the heart is formed predominantly by which of the following:
- The trachea is lined with which type of epithelium:
- The oesophagus ends at which of the following vertebral levels:
- A 28 year old man is brought to ED with a penetrating chest wall injury in the area of the fourth costal cartilage. Which of the following pulmonary structures is present at this site:
- Which of the following structures pass through the aortic opening in the diaphragm:
- The aortic opening in the diaphragm is found at which thoracic level:
- The ascending aorta arises from the aortic orifice at the base of the left ventricle at which of the following locations:
- The caval opening in the diaphragm is found at which thoracic level:
- The pulmonary trunk bifurcates into the right and left pulmonary arteries posterior to the:
- Posteriorly the inferior margin of the lung in quiet respiration is at which of the following vertebral levels:
- Regarding the oesophagus, which of the following statements is CORRECT:
- The trachea arises at the lower border of the cricoid cartilage in the neck at which vertebral level:
- The superior border of the heart is formed predominantly by which of the following:
- The oesophageal opening in the diaphragm is found at which thoracic level:

- [ ] True ribs are defined by which of the following features:
- [ ] Normal quiet expiration is achieved by contraction of which of the following structures:
- [ ] A 64 year old man presents to ED complaining of right sided chest pain that is worse on coughing. Which of the following nerves is most likely responsible for the sensation of pain:
- [ ] A 59 year old woman presents to ED complaining of sudden onset central crushing chest pain radiating down her left arm. ECG is suggestive of posterior myocardial infarction. Which of the following nerves is responsible for the radiating arm pain:
- [ ] The following structures all lie posterior to the oesophagus except for the:
- [ ] Regarding the lungs, which of the following statements is CORRECT:
- [ ] Regarding the ribs, which of the following statements is INCORRECT:
- [ ] The 'bucket handle' movement of the thoracic wall results from which of the following movements:
- [ ] Regarding the thoracic inlet, which of the following statements is CORRECT:
- [ ] Which of the following ribs are classed as 'false ribs':
- [ ] The left pulmonary surface of the heart is formed predominantly by which of the following:
- [ ] The T6 dermatome is best tested at which of the following landmarks:
- [ ] The arch of the aorta continues from the ascending aorta posterior to which of the following:
- [ ] Which of the following does not typically occur at the thoracic plane:
- [ ] The inferior surface of the heart is formed predominantly by which of the following:
- [ ] Regarding the pericardium, which of the following statements is CORRECT:
- [ ] Which of the following actions does not typically occur as part of normal passive expiration:
- [ ] Regarding the thymus gland, which of the following statements is INCORRECT:
- [ ] The interventricular septum is primarily supplied by which of the following coronary vessels:
- [ ] Which of the following structures pass through the caval opening in the diaphragm:
- [ ] Regarding the trachea, which of the following statements is CORRECT:
- [ ] The apex of the heart lies deep to which of the following landmarks:
- [ ] A 50 year old man presents to ED complaining of a hoarse voice. Imaging shows an aneurysm of the aortic arch. Which of the following structures is likely being compressed:
- [ ] The left border of the heart is formed predominantly by which of the following:
- [ ] Contraction of the diaphragm results in which of the following effects:
- [ ] Which of the following best describes the territory of supply of the circumflex artery:
- [ ] Regarding the muscles of the thoracic wall, which of the following statements is INCORRECT:
- [ ] Which of the following structures is the most uppermost in the lung root:
- [ ] A 68 year old man presents to ED with sudden onset severe chest pain and is found to suffered a myocardial infarction in the area of the apex of the heart. Occlusion of which of the following blood vessels is most likely responsible:
- [ ] Which of the following best describes the territory of supply of the anterior interventricular artery:
- [ ] Which of the following muscles is least likely to be involved in forceful expiration:
- [ ] In most people, the atrioventricular node is supplied by which of the following coronary vessels:
- [ ] Posteriorly the inferior margin of the pleural cavity is at which of the following vertebral levels:
- [ ] The oesophagus begins at which vertebral level:
- [ ] In quiet respiration, the position of the right oblique fissure can be marked by a line on the thoracic wall that:
- [ ] The pulmonary trunk arises from the conus arteriosus of the right ventricle at which of the following locations:
- [ ] Which one of the following ribs is not classed as 'atypical':

A 21 year old is brought to ED following a head-on collision with a tree in which he received severe blunt trauma to his sternum from the steering wheel. Which part of the heart would most likely be injured by the impact:

Which of the following occurs primarily to produce passive expiration:

A 61 year old patient presents to ED with sudden onset central crushing chest pain. ECG demonstrates ischaemic changes and bradycardia with a heart rate of 45 bpm. Which of the following vessels is most likely occluded:

Regarding the bronchial tree, which of the following statements is CORRECT:

Which of the following actions does not typically occur as part of normal inspiration:

The right border of the heart is formed predominantly by which of the following:

A 35 year old woman is brought to ED having been involved in a road traffic accident. She has sustained a chest injury on impact with the steering wheel and fractured the sternum at the manubriosternal joint. Which of the following ribs would most likely also be involved in this injury:

The upper limit of the heart on the right side of the sternum is the:

Which of the following structures pass through the oesophageal opening in the diaphragm:

The mitral valve is best auscultated at which of the following sites:

The inferior margin of the pleural cavity is a line that runs anterolaterally between which of the following surface markings:

Regarding the muscles of the thoracic wall, which of the following statements is CORRECT:

The medial surface of the left lung lies adjacent to all of the following structures except for the:

Which of the following best describes the surface marking of the aortic valve:

The right pulmonary surface of the heart is formed predominantly by which of the following:

The medial surface of the right lung lies adjacent to all of the following structures except for the:

Regarding the oesophagus, which of the following statements is CORRECT:

Somatic sensation from the parietal pericardium is carried in which of the following nerves:

The trachea bifurcates into the right and left main bronchi at which vertebral level:

The apex of the heart is formed predominantly by which of the following:

The hila of the lungs are located at which of the following vertebral levels:

False ribs are defined by which of the following features:

The tricuspid valve is best auscultated at which of the following sites:

A 45 year old man presents to ED complaining of severe retrosternal pain that is worse on coughing, and relieved by sitting forwards. The pain radiates to his left shoulder. On examination a pericardial rub is heard, and acute pericarditis is diagnosed. Which of the following nerves is responsible for the radiating pain to the shoulder:

A 72 year old man complains of dysphagia. Imaging and barium swallow investigations show significant cardiac hypertrophy with compression of the oesophagus directly posterior to the heart. Which of the following is the most likely cause of the patient's symptoms:

A 45 year old lifelong smoker presents to ED complaining of shortness of breath and chest pain. Imaging shows a tumour invading the lung surface anterior to the hilum. Which of the following structures is most likely affected:

The coronary arteries arise from which of the following:

The pulmonary valve is best auscultated at which of the following sites:

Regarding the pleurae, which of the following statements is CORRECT:

A 65 year old, lifelong smoker, presents to ED complaining of sudden onset chest pain and shortness of breath. X-ray demonstrates left sided pneumothorax and your consultant has agreed to observe you insert a chest drain. Which of the following sites is the most appropriate to place the chest drain:

The aortic valve is best auscultated at which of the following sites:

Which of the following best describes the surface marking of the pulmonary valve:

At rest, the left dome of the diaphragm normally reaches as high as which of the following:

- [ ] A 49 year old patient presents to ED with vomiting and abdominal distension. X-ray shows small bowel obstruction. A nasogastric tube is inserted. Which of the following is least likely to be a site at which resistance would be expected as the tube passes from the nose to the stomach:
- [ ] The following structures all lies anterior to the oesophagus except for the:
- [ ] The horizontal fissure of the lung separates which of the following:
- [ ] In most people, the sinoatrial node is supplied by which of the following coronary vessels:
- [ ] The lower limit of the heart on the left side of the sternum is the:
- [ ] The right atrium is primarily supplied by which of the following coronary vessels:
- [ ] A patient is brought to ED having been involved in a road traffic accident. Imaging shows a fracture of the T3 vertebral body with compression of the T3 spinal nerve root. The T3 dermatome is best tested at which of the following landmarks:
- [ ] The T5 dermatome is best tested at which of the following landmarks:
- [x] The peripheral diaphragm is attached anterolaterally to which of the following structures:
- [ ] Which of the following ribs are classed as 'true ribs':
- [ ] Regarding the atypical ribs, which of the following statements is INCORRECT:
- [ ] Which of the following atypical ribs articulates with both its corresponding vertebra and the vertebra above:
- [ ] The T4 dermatome is best tested at which of the following landmarks:
- [ ] The inferior border of the heart is formed predominantly by which of the following:
- [ ] At rest the right dome of the diaphragm normally reaches as high as which of the following:
- [ ] The sinoatrial node is located at which of the following sites:
- [ ] A 45 year old patient presents to ED complaining of left sided chest pain and breathlessness. Imaging shows a large left sided pleural effusion. When he sits up for you to examine him, where would the fluid tend to accumulate:
- [ ] The lower limit of the heart on the right side of the sternum is the:
- [ ] The upper limit of the heart on the left side of the sternum is the:
- [x] The base of the heart is formed predominantly by which of the following:
- [ ] Which of the following best describes the relationship of the ascending aorta and the pulmonary trunk as they emerge from their orifices:
- [ ] The motor supply of the diaphragm is from which of the following nerves:
- [ ] In quiet respiration, the position of the left oblique fissure can be marked by a line on the thoracic wall that:
- [ ] Which of the following muscles are primarily involved in passive inspiration:
- [ ] A 21 year old horse rider, falls off her horse during a show-jumping condition and fractures her right third rib and structures with which it articulated. Which of the following structures is most likely affected:
- [ ] Which of the following best describes the territory of supply of the posterior interventricular artery:
- [ ] Which of the following dermatomes is located at the level of the nipples:
- [ ] The left atrium is primarily supplied by which of the following coronary vessels:
- [ ] Which of the following is not true of a typical rib:
- [ ] Regarding the pleurae, which of the following statements is CORRECT:
- [ ] A 19 year old known asthmatic presents to ED with acute severe asthma. Which of the following nerves is responsible for constriction of the bronchial smooth muscle:
- [ ] A 21 year old woman presents to ED following a road traffic accident. The right side of her chest is hyperresonant with reduced expansion and breath sounds. Her trachea is deviated to the left. You diagnose tension pneumothorax and proceed to perform emergency thoracocentesis. Which of the following is the most appropriate site to insert the needle:
- [ ] Which of the following best describes the surface marking of the mitral valve:
- [ ] The central tendon of the diaphragm is attached superiorly to:

Regarding the lung roots, which of the following statements is CORRECT:

A 21 year old patient presents to ED with a primary spontaneous pneumothorax. You are asked by your consultant to perform a pleural aspiration. When inserting the needle, it should be placed:

In quiet respiration anteriorly the horizontal fissure lies at the level of which of the following:

A 19 year old woman is brought to the ED having been stabbed in the chest. She has sustained a penetrating wound in the left fourth intercostal space, just lateral to the sternal border. Which of the following thoracic structures is most likely to have been injured:

Which of the following best describes the territory of supply of the right marginal artery:

Regarding the intercostal space, which of the following statements is CORRECT:

©2014 - 2017 FRCEM Success | Website designed & hosted by Cyberfrog Design

# You have scored 83%

## You answered 111 correct out of 134 questions.

**Your answers are shown below:**

- A 5 year old girl is brought in having inhaled a small plastic object. Where in the tracheobronchial tree is the object most likely to lodge:
- Which of the following best describes the surface marking of the tricuspid valve:
- A 29 year old male presents to ED having sustained a penetrating injury to the neck. On further exploration, it is found that he has transected the left phrenic nerve. Which of the following clinical features would you most expect to see:
- A 54 year old man presents to ED with central crushing chest pain. Later coronary angiograms show thrombosis in the circumflex branch of the left coronary artery. Which of the following conditions is most likely to result from obstruction to flow:
- Which of the following structures lies immediately posterior to the base of the heart:
- The inferior margin of the lung in quiet respiration is a line that runs anterolaterally between which of the following surface landmarks:
- A 54 year old man complains of tingling and a blistering rash that has erupted over his left back and left chest at the level of the nipple. You diagnose shingles. Which of the following spinal nerve roots is most likely affected:
- The 'pump handle' movement of the thoracic wall results from which of the following movements:
- A 21 year old man is brought to ED having been involved in a road traffic accident. He is hypotensive with muffled heart sounds and distended neck veins. Your consultant suspects cardiac tamponade and proceeds to perform emergency pericardiocentesis. Which of the following sites is the needle best placed to relieve the tamponade:
- The hila of the lungs are located at the level of which of the following costal cartilages:
- The anterior surface of the heart is formed predominantly by which of the following:
- The trachea is lined with which type of epithelium:
- The oesophagus ends at which of the following vertebral levels:
- A 28 year old man is brought to ED with a penetrating chest wall injury in the area of the fourth costal cartilage. Which of the following pulmonary structures is present at this site:
- Which of the following structures pass through the aortic opening in the diaphragm:
- The aortic opening in the diaphragm is found at which thoracic level:
- The ascending aorta arises from the aortic orifice at the base of the left ventricle at which of the following locations:
- The caval opening in the diaphragm is found at which thoracic level:
- The pulmonary trunk bifurcates into the right and left pulmonary arteries posterior to the:
- Posteriorly the inferior margin of the lung in quiet respiration is at which of the following vertebral levels:
- Regarding the oesophagus, which of the following statements is CORRECT:
- The trachea arises at the lower border of the cricoid cartilage in the neck at which vertebral level:
- The superior border of the heart is formed predominantly by which of the following:
- The oesophageal opening in the diaphragm is found at which thoracic level:

- [ ] True ribs are defined by which of the following features:
- [ ] Normal quiet expiration is achieved by contraction of which of the following structures:
- [ ] A 64 year old man presents to ED complaining of right sided chest pain that is worse on coughing. Which of the following nerves is most likely responsible for the sensation of pain:
- [ ] A 59 year old woman presents to ED complaining of sudden onset central crushing chest pain radiating down her left arm. ECG is suggestive of posterior myocardial infarction. Which of the following nerves is responsible for the radiating arm pain:
- [ ] The following structures all lie posterior to the oesophagus except for the:
- [ ] Regarding the lungs, which of the following statements is CORRECT:
- [ ] Regarding the ribs, which of the following statements is INCORRECT:
- [ ] The 'bucket handle' movement of the thoracic wall results from which of the following movements:
- [ ] Regarding the thoracic inlet, which of the following statements is CORRECT:
- [ ] Which of the following ribs are classed as 'false ribs':
- [ ] The left pulmonary surface of the heart is formed predominantly by which of the following:
- [ ] The T6 dermatome is best tested at which of the following landmarks:
- [ ] The arch of the aorta continues from the ascending aorta posterior to which of the following:
- [ ] Which of the following does not typically occur at the thoracic plane:
- [ ] The inferior surface of the heart is formed predominantly by which of the following:
- [ ] Regarding the pericardium, which of the following statements is CORRECT:
- [ ] Which of the following actions does not typically occur as part of normal passive expiration:
- [ ] Regarding the thymus gland, which of the following statements is INCORRECT:
- [ ] The interventricular septum is primarily supplied by which of the following coronary vessels:
- [ ] Which of the following structures pass through the caval opening in the diaphragm:
- [ ] Regarding the trachea, which of the following statements is CORRECT:
- [ ] The apex of the heart lies deep to which of the following landmarks:
- [ ] A 50 year old man presents to ED complaining of a hoarse voice. Imaging shows an aneurysm of the aortic arch. Which of the following structures is likely being compressed:
- [ ] The left border of the heart is formed predominantly by which of the following:
- [ ] Contraction of the diaphragm results in which of the following effects:
- [ ] Which of the following best describes the territory of supply of the circumflex artery:
- [ ] Regarding the muscles of the thoracic wall, which of the following statements is INCORRECT:
- [ ] Which of the following structures is the most uppermost in the lung root:
- [ ] A 68 year old man presents to ED with sudden onset severe chest pain and is found to suffered a myocardial infarction in the area of the apex of the heart. Occlusion of which of the following blood vessels is most likely responsible:
- [ ] Which of the following best describes the territory of supply of the anterior interventricular artery:
- [ ] Which of the following muscles is least likely to be involved in forceful expiration:
- [ ] In most people, the atrioventricular node is supplied by which of the following coronary vessels:
- [ ] Posteriorly the inferior margin of the pleural cavity is at which of the following vertebral levels:
- [ ] The oesophagus begins at which vertebral level:
- [ ] In quiet respiration, the position of the right oblique fissure can be marked by a line on the thoracic wall that:
- [ ] The pulmonary trunk arises from the conus arteriosus of the right ventricle at which of the following locations:
- [ ] Which one of the following ribs is not classed as 'atypical':

A 21 year old is brought to ED following a head-on collision with a tree in which he received severe blunt trauma to his sternum from the steering wheel. Which part of the heart would most likely be injured by the impact:

Which of the following occurs primarily to produce passive expiration:

A 61 year old patient presents to ED with sudden onset central crushing chest pain. ECG demonstrates ischaemic changes and bradycardia with a heart rate of 45 bpm. Which of the following vessels is most likely occluded:

Regarding the bronchial tree, which of the following statements is CORRECT:

Which of the following actions does not typically occur as part of normal inspiration:

The right border of the heart is formed predominantly by which of the following:

A 35 year old woman is brought to ED having been involved in a road traffic accident. She has sustained a chest injury on impact with the steering wheel and fractured the sternum at the manubriosternal joint. Which of the following ribs would most likely also be involved in this injury:

The upper limit of the heart on the right side of the sternum is the:

Which of the following structures pass through the oesophageal opening in the diaphragm:

The mitral valve is best auscultated at which of the following sites:

The inferior margin of the pleural cavity is a line that runs anterolaterally between which of the following surface markings:

Regarding the muscles of the thoracic wall, which of the following statements is CORRECT:

The medial surface of the left lung lies adjacent to all of the following structures except for the:

Which of the following best describes the surface marking of the aortic valve:

The right pulmonary surface of the heart is formed predominantly by which of the following:

The medial surface of the right lung lies adjacent to all of the following structures except for the:

Regarding the oesophagus, which of the following statements is CORRECT:

Somatic sensation from the parietal pericardium is carried in which of the following nerves:

The trachea bifurcates into the right and left main bronchi at which vertebral level:

The apex of the heart is formed predominantly by which of the following:

The hila of the lungs are located at which of the following vertebral levels:

False ribs are defined by which of the following features:

The tricuspid valve is best auscultated at which of the following sites:

A 45 year old man presents to ED complaining of severe retrosternal pain that is worse on coughing, and relieved by sitting forwards. The pain radiates to his left shoulder. On examination a pericardial rub is heard, and acute pericarditis is diagnosed. Which of the following nerves is responsible for the radiating pain to the shoulder:

A 72 year old man complains of dysphagia. Imaging and barium swallow investigations show significant cardiac hypertrophy with compression of the oesophagus directly posterior to the heart. Which of the following is the most likely cause of the patient's symptoms:

A 45 year old lifelong smoker presents to ED complaining of shortness of breath and chest pain. Imaging shows a tumour invading the lung surface anterior to the hilum. Which of the following structures is most likely affected:

The coronary arteries arise from which of the following:

The pulmonary valve is best auscultated at which of the following sites:

Regarding the pleurae, which of the following statements is CORRECT:

A 65 year old, lifelong smoker, presents to ED complaining of sudden onset chest pain and shortness of breath. X-ray demonstrates left sided pneumothorax and your consultant has agreed to observe you insert a chest drain. Which of the following sites is the most appropriate to place the chest drain:

The aortic valve is best auscultated at which of the following sites:

Which of the following best describes the surface marking of the pulmonary valve:

At rest, the left dome of the diaphragm normally reaches as high as which of the following:

A 49 year old patient presents to ED with vomiting and abdominal distension. X-ray shows small bowel obstruction. A nasogastric tube is inserted. Which of the following is least likely to be a site at which resistance would be expected as the tube passes from the nose to the stomach:

The following structures all lies anterior to the oesophagus except for the:

The horizontal fissure of the lung separates which of the following:

In most people, the sinoatrial node is supplied by which of the following coronary vessels:

The lower limit of the heart on the left side of the sternum is the:

The right atrium is primarily supplied by which of the following coronary vessels:

A patient is brought to ED having been involved in a road traffic accident. Imaging shows a fracture of the T3 vertebral body with compression of the T3 spinal nerve root. The T3 dermatome is best tested at which of the following landmarks:

The T5 dermatome is best tested at which of the following landmarks:

The peripheral diaphragm is attached anterolaterally to which of the following structures:

Which of the following ribs are classed as 'true ribs':

Regarding the atypical ribs, which of the following statements is INCORRECT:

Which of the following atypical ribs articulates with both its corresponding vertebra and the vertebra above:

The T4 dermatome is best tested at which of the following landmarks:

The inferior border of the heart is formed predominantly by which of the following:

At rest the right dome of the diaphragm normally reaches as high as which of the following:

The sinoatrial node is located at which of the following sites:

A 45 year old patient presents to ED complaining of left sided chest pain and breathlessness. Imaging shows a large left sided pleural effusion. When he sits up for you to examine him, where would the fluid tend to accumulate:

The lower limit of the heart on the right side of the sternum is the:

The upper limit of the heart on the left side of the sternum is the:

The base of the heart is formed predominantly by which of the following:

Which of the following best describes the relationship of the ascending aorta and the pulmonary trunk as they emerge from their orifices:

The motor supply of the diaphragm is from which of the following nerves:

In quiet respiration, the position of the left oblique fissure can be marked by a line on the thoracic wall that:

Which of the following muscles are primarily involved in passive inspiration:

A 21 year old horse rider, falls off her horse during a show-jumping condition and fractures her right third rib and structures with which it articulated. Which of the following structures is most likely affected:

Which of the following best describes the territory of supply of the posterior interventricular artery:

Which of the following dermatomes is located at the level of the nipples:

The left atrium is primarily supplied by which of the following coronary vessels:

Which of the following is not true of a typical rib:

Regarding the pleurae, which of the following statements is CORRECT:

A 19 year old known asthmatic presents to ED with acute severe asthma. Which of the following nerves is responsible for constriction of the bronchial smooth muscle:

A 21 year old woman presents to ED following a road traffic accident. The right side of her chest is hyperresonant with reduced expansion and breath sounds. Her trachea is deviated to the left. You diagnose tension pneumothorax and proceed to perform emergency thoracocentesis. Which of the following is the most appropriate site to insert the needle:

Which of the following best describes the surface marking of the mitral valve:

The central tendon of the diaphragm is attached superiorly to:

Regarding the lung roots, which of the following statements is CORRECT:

A 21 year old patient presents to ED with a primary spontaneous pneumothorax. You are asked by your consultant to perform a pleural aspiration. When inserting the needle, it should be placed:

In quiet respiration anteriorly the horizontal fissure lies at the level of which of the following:

A 19 year old woman is brought to the ED having been stabbed in the chest. She has sustained a penetrating wound in the left fourth intercostal space, just lateral to the sternal border. Which of the following thoracic structures is most likely to have been injured:

Which of the following best describes the territory of supply of the right marginal artery:

Regarding the intercostal space, which of the following statements is CORRECT:

**a)** The neurovascular bundle lies in the costal groove along the superior margin of the rib.
**b)** The neurovascular bundle lies between the external and internal intercostal muscles.
**c)** **Within the neurovascular bundle, the artery lies superior to the intercostal nerve.** ✔
**d)** The intercostal vein is the structure most vulnerable to damage in the neurovascular bundle.
**e)** There are 12 intercostal spaces, each numbered for the rib superior to it.

Something wrong?

## Answer

Within the neurovascular bundle, the intercostal vein is the most superior, followed by the intercostal artery and then the intercostal nerve.

## Notes

The intercostal space lies between adjacent ribs and mostly contains intercostal muscles. Since there are 12 ribs on each side, there are 11 intercostal spaces, each numbered for the rib superior to it.

Intercostal nerves and major associated arteries and veins lie in the costal groove along the inferior margin of the rib, lying in a plane between the internal and innermost intercostal muscles.

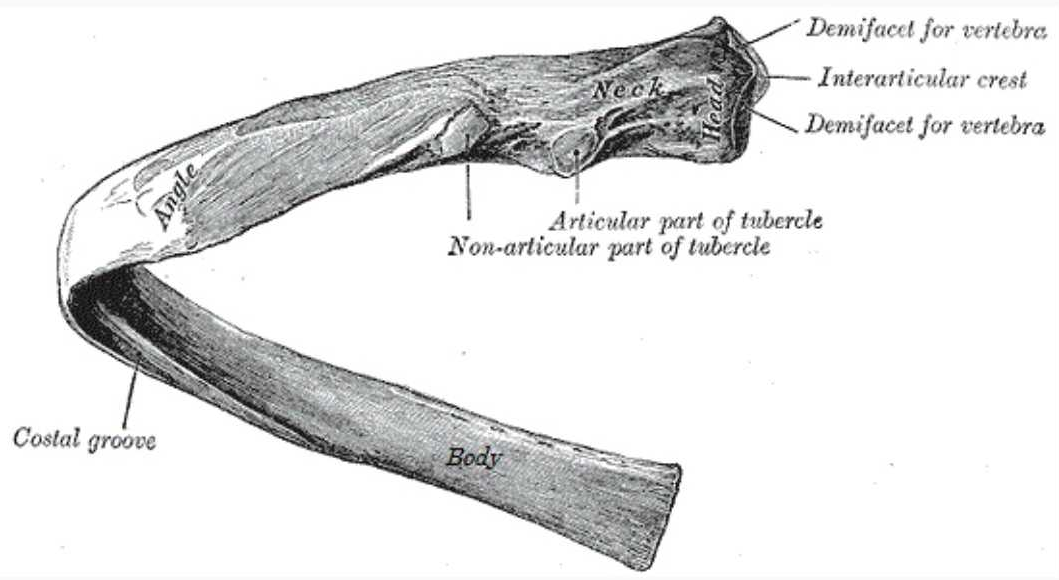


Modified by FRCEM Success. Original by Henry Vandyke Carter [Public domain], via Wikimedia Commons

In each space, the vein is the most superior structure and is therefore highest in the costal groove. The artery is inferior to the vein and the nerve inferior to the artery and often not protected by the groove. Therefore the nerve is the most vulnerable structure in a penetrating injury to the upper aspect of the intercostal space. Small collateral branches of the major intercostal nerves and vessels are often present superior to the inferior rib below.

Any needle or tube (e.g. in needle thoracocentesis, pleural aspiration or chest drain insertion) being inserted in the intercostal space should be placed immediately above the superior margin of a rib to avoid injury to the intercostal neurovascular bundle.

**Needle thoracocentesis**

Needle thoracocentesis is indicated in patients in critical condition with rapid deterioration who have a life-threatening tension pneumothorax where urgent chest drain insertion is not possible.

The needle should be placed just superior to the third rib, in the second intercostal space, in the midclavicular line on the affected side.

Complications of needle thoracocentesis include local haematoma, pneumothorax and lung laceration.

## Chest drain insertion

Chest drain insertion is the definitive treatment for tension pneumothorax. Chest drain insertion normally occurs at the fifth intercostal space in the midaxillary line on the affected side.

Complications of chest drain insertion include:

- laceration or puncture of intrathoracic or intraabdominal organs
- introduction of pleural infection
- damage to the intercostal nerve (resulting in intercostal neuralgia)
- damage to the intercostal artery or vein (resulting in haemopneumothorax)
- chest drain kinking, clogging or dislodgement or disconnection from underwater seal
- persistent pneumothorax
- subcutaneous emphysema
- recurrence of pneumothorax upon removal of chest drain.


FRCEM Success

We are an online revision resource for FRCEM Primary and Intermediate exam preparation.

Terms & Conditions
Get in Touch

Resources

- The Royal College of Emergency Medicine
- Irish Association for Emergency Medicine
- Advanced Trauma Life Support
- Resuscitation Council (UK)
- TeachMeAnatomy
- Trauma.org
- Radiopaedia
- Advanced Life Support Group
- Emergency Medicine Journal
- Lifeinthefastlane
- Instant Anatomy
- Patient.co.uk

FRCEMSuccess

©2014 - 2017 FRCEM Success | Website designed & hosted by Cyberfrog Design